

Aus der Radiologischen Universitätsklinik
Abteilung Nuklearmedizin und Klinische Molekulare
Bildgebung Tübingen

**Scintigraphic detection of sentinel nodes in
endometrial cancer**

Inaugural-Dissertation
zur Erlangung des Doktorgrades
der Medizin

der Medizinischen Fakultät
der Eberhard Karls Universität
zu Tübingen

vorgelegt von
Sahbai Samine

2018

Aus der Radiologischen Universitätsklinik
Abteilung Nuklearmedizin und Klinische Molekulare
Bildgebung Tübingen

**Scintigraphic detection of sentinel nodes in
endometrial cancer**

Inaugural-Dissertation
zur Erlangung des Doktorgrades
der Medizin

der Medizinischen Fakultät
der Eberhard Karls Universität
zu Tübingen

vorgelegt von
Sahbai Samine

2018

Dekan: Professor Dr. I. B. Autenrieth

1. Berichterstatter: Professor Dr. C. la Fougère

2. Berichterstatter: Professor Dr. S. Clasen

Tag der Disputation: 18.12.2018

Meiner Mutter

TABLE OF CONTENTS

1. Introduction and scientific issue.....	7
1.1 Epidemiology of endometrial cancer.....	9
1.2 Type of endometrial cancer.....	9
1.3 Risk factors and physiopathology of endometrial cancer.....	10
1.4 Diagnostic of endometrial cancer.....	10
1.5 Histological classification of endometrial cancer.....	10
1.5.1 Adenocarcinoma.....	11
1.5.2 Mucinous carcinoma.....	12
1.5.3 Papillary serous carcinoma.....	12
1.5.4 Clear cell carcinoma.....	13
1.5.5 Squamous carcinoma.....	14
1.5.6 Other histological entities.....	14
1.6 Tumor staging of endometrial cancer.....	14
1.7 Surgical tumor staging.....	15
1.8 Prognostic variables.....	16
1.9 Lymph node metastasis.....	16
1.10 Treatment of endometrial cancer.....	17
1.11 Therapeutic strategies.....	18
1.12 Indication of lymphadenectomy in the pelvic and para-aortic regions.....	19
1.13 Sentinel lymph node in cervical cancer.....	21
1.14 Sentinel lymph node in endometrial cancer.....	22
2. Publications.....	23
2.1 Pericervical injection of Tc99m-Nanocolloid is superior to peritumoral injection for sentinel lymph node detection of endometrial cancer in SPECT/CT.....	23

2.2 Sentinel lymph node mapping using SPECT/CT and gamma probe in endometrial cancer: an analysis of parameters affecting detection rate	30
3. Discussion	40
4. Summary	43
5. Zusammenfassung.....	45
6. References	47
7. Liste der Veröffentlichungen	54

List of abbreviations

BMI	Body Mass Index
CA125	Cancer Antigen 125
CT	Computed Tomography
DNA	Deoxyribonucleid Acid
EC	Endometrial Cancer
ESMO	European Society for Medical Oncology
FIGO	Fédération International de Gynécologie et d'Obstétrique
G	Grade
LN	Lymph Node
MBq	Megabecquerel
MRI	Magnetic Resonance Imaging
MRT	Magnetresonanztomographie
SLN	Sentinel Lymph Node
SPECT	Single Photon Emission Computed Tomography
99m-Tc	Technetium-99m
TNM	Tumor, lymph Node, Metastasis (Tumor classification)

1. Introduction and scientific issue

The sentinel lymph node (SLN) is defined to be the first lymph node which is draining the lymphatic fluid from the malignant tumor and should be the first site of nodal metastasis. Theoretically, absence of metastatic cells in the sentinel lymph node biopsy should reflect the nodal status of the following areas and can avoid further complete lymphadenectomy. This method is preferably performed in patients with apparent early stage cancer and clinically negative lymph node status.

Sentinel lymph nodes are in general detected through injection of ^{99m}-technecium radiolabeled colloids or/and blue dye followed by intraoperative identification of the sentinel lymph nodes utilizing handheld gamma probes or visual identification of blue-stained nodes.

Additional preoperative lymphoscintigraphy in conjunction with SPECT/CT enable a non-invasive SLN-detection by measuring the radioactivity within the SLN and can help to plan complicated surgical procedures especially in the abdomen and pelvis.

Sentinel lymph node detection takes an important place in the therapy management of different tumor entities like melanoma and breast cancer. Actually, this method is under investigation as a diagnostic tool in other human malignancies, including also prostatic and penile cancer as well as carcinoma of the cervix.

SLN mapping was also proposed in endometrial cancer to prevent unnecessary lymphadenectomy and to obtain adequate information regarding the extent of lymph node involvement, thus allowing optimal planning of operative and adjuvant therapy. SLN biopsy could be an alternative technique to prevent long-term side effects from extensive lymphadenectomy, especially in elderly women. The most frequent post-operative adverse events are symptomatic lower-extremity lymphedema and lymphocele¹. Scintigraphic mapping of SLN is increasing in gynecological centers for a better stage-based treatment in endometrial cancer². However, due to the lack of scientific evidence, the routine clinical use of SLN mapping in endometrial cancer is not yet confirmed³.

In addition, different methods of radiotracer injection have been employed for the SLN mapping in endometrial cancer so far: the direct pericervical injection, the hysteroscopic peritumoral injection and the fundal peritumoral injection.

The aim of the presented studies was to determine the best injection technique and therefore to analyze the preoperative scintigraphic SLN detection rate using SPECT/CT between the direct pericervical injection technique and the hysteroscopic-peritumoral injection technique in women diagnosed with endometrial carcinoma (**Publication 1. Sahbai et al. Pericervical injection of Tc99m-Nanocolloid is superior to peritumoral injection for sentinel lymph node detection of endometrial cancer in SPECT/CT. Clin Nucl Med. 2016 Dec;41(12):927-932. Impact Factor 4.563).**

Furthermore, we aimed to determine parameters and factors contributing to scintigraphic SLN detection failure of endometrial cancer in a larger patients' cohort using pericervical injection technique (**Publication 2. Sahbai et al. Sentinel lymph node mapping using SPECT/CT and gamma probe in endometrial cancer: an analysis of parameters affecting detection rate. Eur J Nucl Med Mol Imaging. 2017 Aug;44(9):1511-1519. Impact Factor 7.277).**

1.1 Epidemiology of endometrial cancer

Endometrial cancer is the fourth most frequent women cancer in Europe, the third in USA⁴⁻⁶ and the sixth worldwide. It is the 14th most common cancer overall with around 319000 new cases diagnosed in 2012⁵ and the tenth most common cancer overall with around 99000 new cases diagnosed in 2012⁶.

Germany counted approximately 10930 new cases in 2012 and about 5% of all cancer in women, endometrial cancer represents the most frequent women cancer of genital organ. The proportion of cancer related deaths decreased significantly to 2.5% due to the good prognosis. At diagnosis, the median age is 69 years⁷.

1.2 Type of endometrial cancer

In general there are two different types of endometrial cancer⁸. In about 85% of cases, the type I occurs in younger and peri-menopausal women with a history of endogenous or exogenous estrogen exposure. In these women tumors begin as hyperplastic endometrium and will progress to carcinoma. These estrogen-dependent tumors are tending to be better differentiated and have a more favorable prognosis than tumors that are not associated with hyper-estrogenism. In the other cases, the type II endometrial carcinoma occurs more in women with no estrogen stimulation. These spontaneously occurring cancers are not associated with pathological endometrial hyperplasia, but may arise in a background of atrophic endometrium. They are less differentiated and associated with a poorer prognosis than estrogen-dependent tumors⁹.

1.3 Risk factors and physiopathology of endometrial cancer

Risk factors of endometrial cancer have been identified¹⁰⁻¹⁵. Mostly related to prolonged, estrogen and unopposed stimulation of the endometrium⁹. These risk factors are nulliparity, late menopause, obesity, menopausal estrogen therapy without progesterone¹⁴, antiestrogen tamoxifen therapy of breast cancer^{15,16}, diabetes mellitus⁹ and non-polyposis colorectal cancer syndrome¹⁷. Moreover, other conditions such as hypertension and hypothyroidism have been related with increased risk of endometrial cancer.

1.4 Diagnostic of endometrial cancer

Uterine ultrasound can be used to identify endometrial hypertrophy. Endometrial aspiration biopsy can evaluate abnormal uterine bleeding or suspected endometrial pathology¹⁸. A Papanicolaou test is not reliable when only 30% to 50% of patients with endometrial cancer have pathologic test results¹⁹. The diagnosis will then be proven with the histological pathological examination of biopsy.

1.5 Histological classification of endometrial cancer

In the FIGO grading system, tumors are grouped into three grades²⁰. The grade 1 has a solid growth pattern up to 5% in the tumor. For grade 2, there is 6% to 50% of solid growth pattern in the tumor. In grade 3, at least 50% of the tumor has a solid growth pattern. The histologic classification of endometrial carcinoma is shown in Table 1²¹. The most frequent histological type of endometrial carcinoma is adenocarcinoma which has the best prognosis²². Adenocarcinoma with squamous differentiation is generally graded according to the FIGO grading system which is applicable to all endometrioid carcinomas, including its variants, and to mucinous carcinomas. Serous and clear cell carcinomas should always be considered as high-grade lesions making grading unnecessary²². The FIGO staging system will be later shown in Table 2²³.

Endometrioid adenocarcinoma
Clear cell carcinoma
Squamous carcinoma
Mucinous carcinoma
Papillary serous carcinoma
Other entities (carcinosarcoma)

Table 1. Histologic classification of endometrial carcinomas ²¹

1.5.1 Adenocarcinoma

The endometrioid type of adenocarcinoma (Figure 1) is the most frequent histological type with about 80 to 90% of endometrial carcinomas. It has a good prognostic value with about 90% of 5-year survival²².

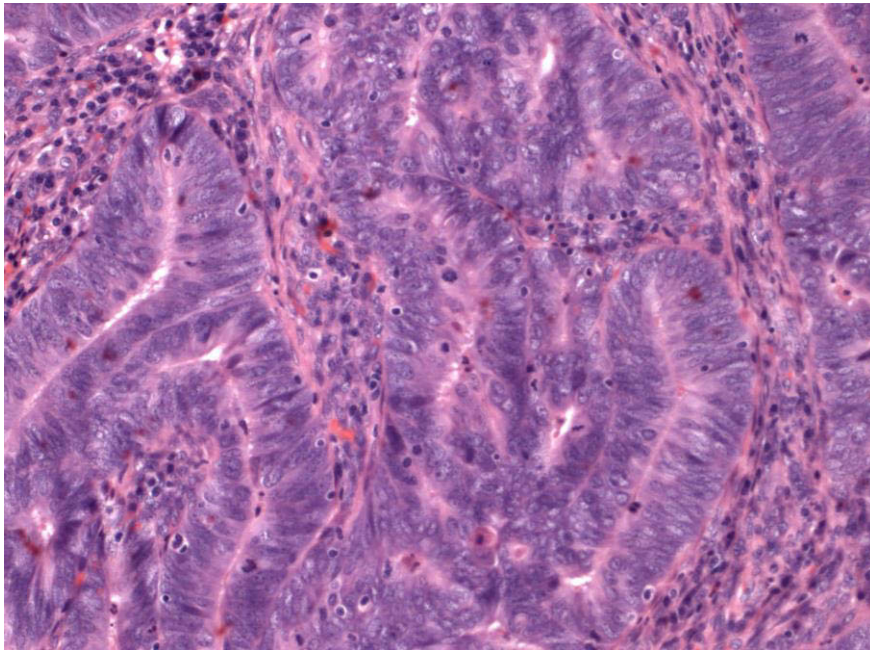


Figure 1. 200x Courtesy of Annette Staebler (Institute of Pathology University Hospital Tuebingen)

1.5.2 Mucinous carcinoma

Predominant mucinous pattern represents 5% of endometrial carcinomas. Cells with intracytoplasmic mucin are present in more than 50% of the tumor (Figure 2)^{24,25}.

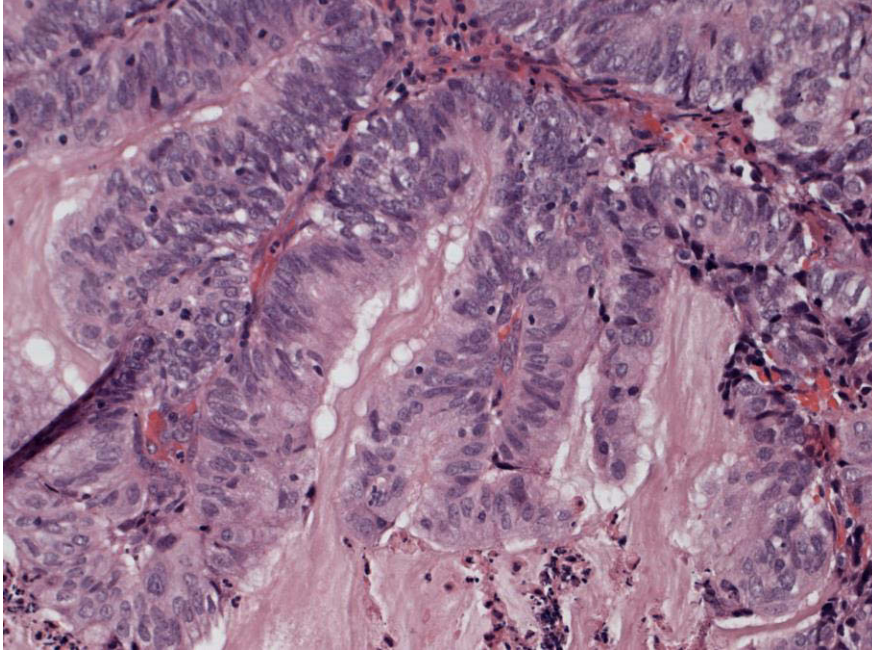


Figure 2. 200x Courtesy of Annette Staebler (Institute of Pathology University Hospital Tuebingen)

1.5.3 Papillary serous carcinoma

4% of endometrial carcinomas present serous cells. These tumors are more aggressive and similar with the ovary and fallopian tube serous carcinomas (Figure 3)²⁶⁻²⁸.

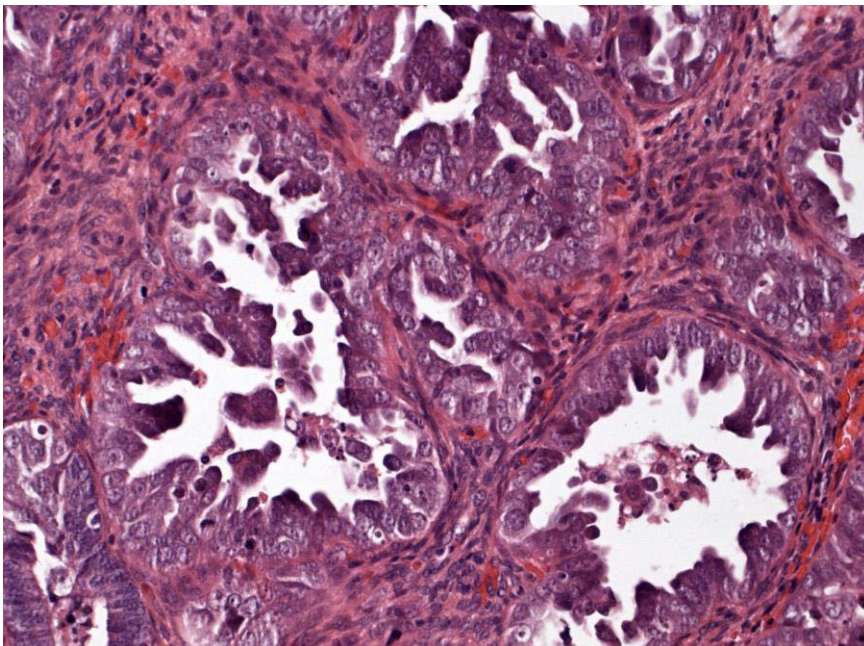


Figure 3. 200x Courtesy of Annette Staebler (Institute of Pathology University Hospital Tuebingen)

1.5.4 Clear cell carcinoma

In 5% of all endometrial carcinomas (Figure 4)²⁹⁻³¹ clear cells tumors appear in women with more advanced age. This aggressive type of endometrial cancer showed overall survival rates from 33% to 64%²⁹. Myometrial invasion and lymphatic vessels invasion are important prognostic indicators.

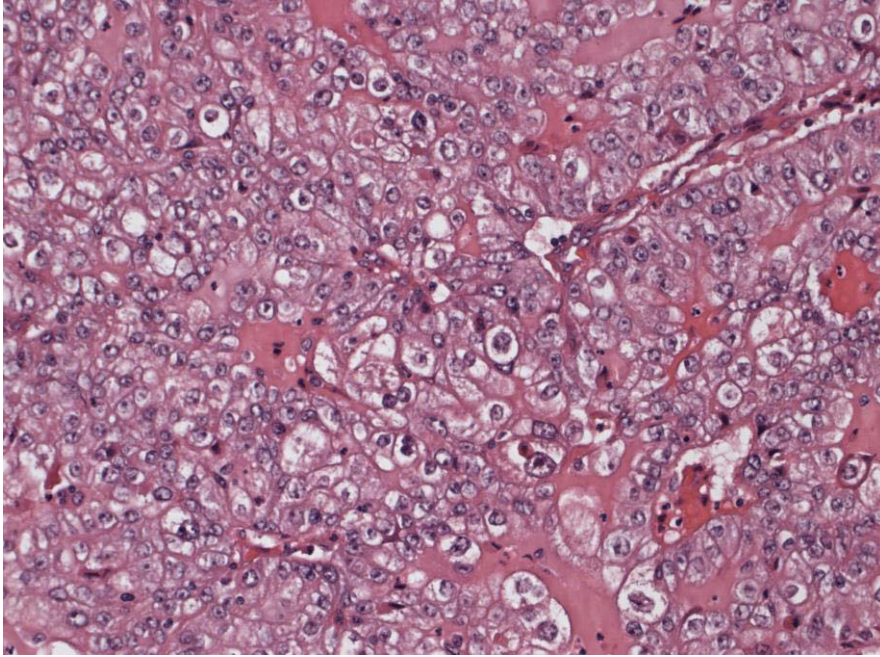


Figure 4. 400x Courtesy of Annette Staebler (Institute of Pathology University Hospital Tuebingen)

1.5.5 Squamous carcinoma

These tumors are rare (Figure 5) and have a poor prognosis of about 36% survival rate³².

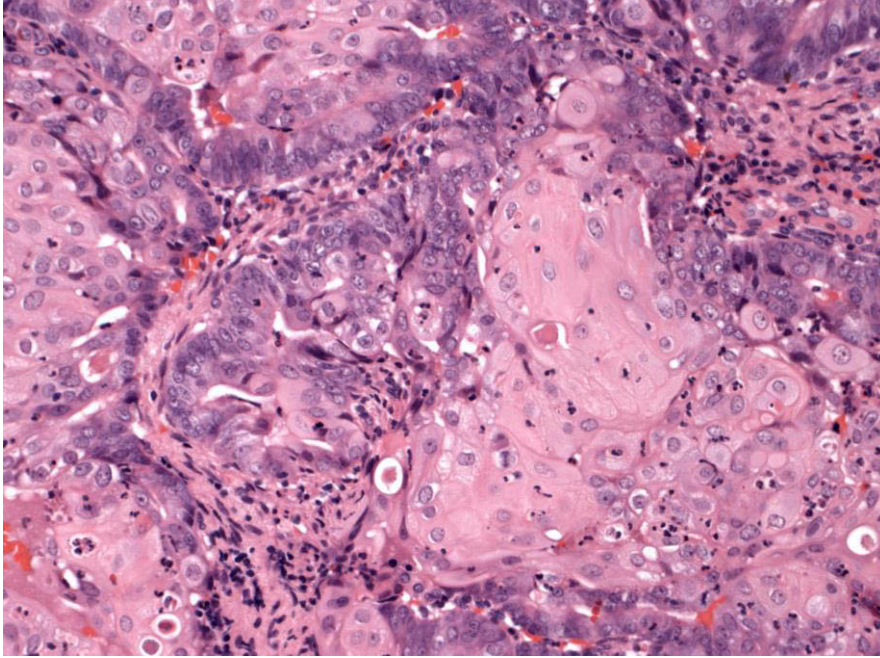


Figure 5. 400x Courtesy of Annette Staebler (Institute of Pathology University Hospital Tuebingen)

1.5.6 Other histological entities

Other histological entities have a poor prognosis. These rare histological types comprise sarcomas and carcinosarcomas²².

1.6 Tumor staging of endometrial cancer

History of patient should specify in particular the antecedents, personal and family medical condition (non-polyposis colorectal cancer syndrome), patient risk factors and comorbidities as well as symptoms suggesting endometrial cancer.

The clinical examination includes an abdominal, pelvic and lymph node examination. Chest radiography might be required in order to determine the cardiorespiratory condition of the patient and to detect pulmonary metastases³³. Ultrasonography and pelvic associated with a MRI exploration of lumbar-aortic lymph node areas is the pre-operative imaging of reference. Other imaging studies may be required by the specialized team³⁴.

There is no specific tumor marker for endometrial cancer.

However, to evaluate the treatment response, the initial dosage of CA125 can be discussed if there is suspected regional extension, ovarian involvement or in case of histological type 2³⁵.

1.7 Surgical tumor staging

Surgical staging is the reference considering the poor correlation between preoperative staging and histological findings. Most of endometrial cancer patients should perform the FIGO system based surgical staging^{23,36,37} (Table 2). Tumor histology and myometrial invasion depth appear to be the two most important factors influencing the risk for lymph node metastasis^{36,37}.

FIGO Stage	
I ^a IA ^a IB ^a	Tumor inside the corpus uteri No myometrial tumor invasion or < 50% Tumor invasion ≥ 50% of the myometrium
II ^a	Tumor extended to the cervical stroma, but not beyond the uterus ^b
III ^a IIIA ^a IIIB ^a IIIC ^a IIIC1 ^a IIIC2 ^a	Local and/or regional tumor spread Tumor invades the serosa of the corpus uteri and/or adnexae ^c Vaginal involvement and/ or parametrial involvement ^c Metastatic lymph nodes in the pelvic and/or para-aortic regions ^c Metastatic pelvic lymph nodes Metastatic para-aortic with or without positive pelvic lymph nodes
IV ^a IVA ^a IVB ^a	Bladder and/or bowel mucosa tumor invasion, and/or distant metastases Tumor invasion of bladder and/or bowel mucosa Distant metastasis, including intra-abdominal metastases and/or inguinal lymph nodes

^a Either G1, G2, or G3

^b Endocervical glandular involvement only should be considered as Stage I

^c Positive cytology has to be reported separately without changing the stage

Table 2. FIGO classification system in the cancer of the corpus uteri

1.8 Prognostic variables

The most significant variable reducing survival is the disease stage. Other independent prognostic factors of disease recurrence or survival are patient age, tumor grade, histological type, myometrial invasion and extra-uterine disease spread detected after surgical histology. Lymphatic invasion seems to be an important prognostic factor in endometrial cancer for disease recurrence and death, particularly in clinical early stage³⁸⁻⁴¹. In patients with clinical stage I endometrial cancer, there will be pelvic lymph node metastases in about 10% of cases and para-aortic lymph node metastases in 6% of cases. The 5-year disease-free survival rate is about 50% compared to 90% for patients without lymph node metastases⁴². The Gynecologic Oncology Group showed that the presence lymph node metastases in the para-aortic region was an important prognostic factor⁴³.

1.9 Lymph node metastasis

Surgical staging can correctly identify extra-uterine disease and can modify significantly treatment decisions. An important retrospective study showed an overall incidence lymph node involvement of about 3% with tumor histological grade I, of 9% with grade II and of 18% with grade III in endometrial cancer in clinical stage I. In case of no myometrial invasion or less than 50%, lymph node involvement was present less than 5% of patients. In contrary, when myometrial invasion was more than 50%, lymph node involvement was found in approximately 20% of patients. For tumor histologic grade I and II, lymph node metastases in the pelvic area were present in less than 5% with myometrial invasion less than 50% and in about 15% with myometrial invasion more than 50%. With cervical tumor invasion, there is an incidence of approximately 15% lymph node involvement in the pelvic and para-aortic area³⁷. Moreover, incidence of lymph node involvement increase significantly with tumor size bigger than 2 cm (about 15%)⁴⁴. Extra-uterine spread of tumor increases the risk of nodal involvement in the pelvic and para-aortic area. Adnexal involvement and positive peritoneal cytology increase also significantly the incidence of pelvic and para-aortic regions³⁷.

1.10 Treatment of endometrial cancer

Surgery is the gold standard therapeutic procedure in endometrial cancer as long as the stage and condition of the patient allow it. It includes usually a total hysterectomy with bilateral salpingo-oophorectomy⁴⁵. Additional gestures depend on clinical stage, histological type and grade: lymphadenectomy and omentectomy⁹. The benefit / risk balance (age, comorbidities, morbid obesity) can limit these additional procedures.

The laparoscopic management should be preferred for early clinical stage I of endometrial cancer^{46,47}.

Laparoscopic hysterectomy and bilateral salpingo-oophorectomy associated with laparoscopic retroperitoneal lymph node sampling is feasible. One randomized study showed less surgical morbidity with the laparoscopic approach than laparotomy in patients with endometrial cancer⁴⁸. In this study, the rates of postoperative complications, the overall survival and the disease-free survival were not significantly different in both groups.

However, laparotomy remains essential in case of suspected large volume tumor or particular anatomical conditions, i.e. massive adhesion or obesity.

Radiation therapy following primary surgery can be achieved by external beam radiotherapy or brachytherapy. Patients with comorbidities unsuitable for surgery may have benefits from primary radiotherapy, which showed to be an effective therapy of endometrial cancer⁴⁹. This was shown in many previous studies⁵⁰⁻⁵².

External radiotherapy is generally targeted and guided by CT-imaging. The volume of irradiation depends on the tumor extension. Radiotherapy should be performed in the pelvis, and possibly in the lumbar-aortic area in case of para-aortic lymph node involvement.

Postoperative vaginal brachytherapy (vaginal cuff irradiation) can also be performed preferentially with high dose rate. This technique avoids long hospitalization and decubitus complications.

If chemotherapy is indicated, it should be given before or after radiotherapy sequentially. When the patient does not seem able to support this sequential treatment,

radiotherapy alone is preferred. Most of the conventional chemotherapy procedures include carboplatin and paclitaxel association or cisplatin combined with doxorubicin.

Adjuvant hormone therapy may be indicated in a metastatic situation when chemotherapy is not applicable or in case of slowly progressive disease or in tumors with hormone positive receptors. The treatment is based mainly on oral daily progesterone medication. In case of contraindication, anti-estrogens should be used.

1.11 Therapeutic strategies

Therapeutic strategies depend on tumor staging and should be defined by surgical prognostic factors determined in histology. There are three classified patient categories based on disease recurrence risk: low, intermediate and high risk. In tumor histological grade I and II with no myometrial invasion (T1a) there is a very good prognosis. These patients should not have additional therapies after surgical treatment⁵³⁻⁵⁵.

The Table 3 represents the therapeutic strategies after to surgical treatment and tumor staging.

FIGO/TNM Staging	Surgery	Postoperative treatment
<i>Low risk</i> Type I histology: IA/T1a, Grade I or II	Yes	No
<i>Intermediate risk</i> Type I histology: IA/T1a, Grade III IB/T1b, Grade I or II	Yes	Brachytherapy
<i>High risk</i> Type I histology: IB/T1b, Grade III	Yes	Radiotherapy <i>Optional brachytherapy</i>

Type II histology: Stage I/T1	Yes	Radiotherapy <i>Optional brachytherapy and chemotherapy</i>
<i>All histologic types</i> Stage II/T2	Yes	Radiotherapy and brachytherapy <i>Optional chemotherapy</i>
<i>All histologic types</i> Stage III/T3 and/or N1	Yes	Radiotherapy and brachytherapy <i>Optional chemotherapy</i>
<i>All histologic types</i> Stage IVA/T4	<i>Optional</i>	Radiotherapy, brachytherapy and chemotherapy
Stage IVB/M1	<i>Optional</i>	Radiotherapy, chemotherapy and hormonal therapy

Table 3. Therapeutic strategies based on histologic and surgical pathological findings

1.12 Indication of lymphadenectomy in the pelvic and para-aortic regions

In general, primary hysterectomy and bilateral salpingo-oophorectomy is the gold standard surgical treatment of patients with endometrial cancer. However, collected data about the impact of pelvic and para-aortic lymphadenectomy on survival remain controversial. Moreover, in early clinical stage of endometrial cancer, there is no consensus for performing systematic lymphadenectomy. Commonly, selective lymph node dissection in the pelvic and para-aortic regions might be effected in more advanced stage of endometrial cancer in case of one or several risk factors presented in the Table 4⁵⁶⁻⁵⁸.

Extra-uterine disease
Myometrial tumor invasion more than 50%
Tumor size more than 2 cm
Cervix extension
High risk tumor histology

Table 4. Risk factors recommending pelvic and para-aortic lymph node dissection

Recently, several factors have been identified in apparent early clinical stage (T1a and T1b) for high risk of recurrence²⁰. These factors can then subdivide all patients with FIGO stage I in low risk; intermediate risk and high risk (see Table 5). Recent published guidelines of the ESMO recommend bilateral lymphadenectomy in the pelvic and para-aortic regions based on risk of recurrence⁵⁹ (Table 6). The role of selective lymphadenectomy in apparent early clinical stage could be an important method for tumor staging during surgery and can make potential therapeutic decision changes. In addition, bilateral lymphadenectomy of pelvic and para-aortic areas is preferred in patients with intermediate and high-risk⁵⁹.

Low risk:	Stage IA, grade I and II of endometrioid type
Intermediate risk:	Stage IA, grade III of endometrioid type Stage IB, grade I and II of endometrioid type
High risk:	Stage IB, grade III of endometrioid type All stages of non-endometrioid type

Table 5. Categories of recurrence risk according to FIGO stage

FIGO	TNM/Grade	Surgical Indication
Stage I	IA, grade I and II	Hysterectomy with bilateral salpingo-oophorectomy
	IA, grade III	Hysterectomy with bilateral salpingo-oophorectomy optional bilateral pelvic-para-aortic lymphadenectomy
	IB, grade I to III	Hysterectomy with bilateral salpingo-oophorectomy optional bilateral pelvic-para-aortic lymphadenectomy
Stage II	II	Radical hysterectomy with bilateral salpingo-oophorectomy and bilateral pelvic to para-aortic lymphadenectomy
Stage III	III	Maximal surgical cytoreduction
Stage IV	IV A	Anterior and posterior pelvic exenteration
	IV B	Palliative surgery and systemic therapy

Table 6. Clinical ESMO guidelines of surgical therapy for early and advanced FIGO stage endometrial cancer

1.13 Sentinel lymph node in cervical cancer

SLN detection techniques in cervical cancer were investigated previously in several published studies. Sentinel lymph nodes can be detected in 80% up to 98% of cervical cancer patients and have been detected by both laparotomy and laparoscopic techniques with equivalent detection rates⁶⁰. Combined blue dye and radiotracer application

techniques appeared to have a better SLN detection rate over either technique used alone⁶¹. Test sensitivity of 88% can be expected with a detection rate of 97% in a recent meta-analysis of 49 studies⁶². In a french prospective multicentric study, the negative predictive value of SLN biopsy in cervical cancer reached 93%⁶³. The number of detected SLN was influenced by patient body mass index, age and time gap between injection and surgery in previous studies^{63,64}. Sentinel node detection in cervical cancer plays an important role and is well established at this time, therefore the technique is recommended since 2014 in the guidelines published by the European Association of Nuclear Medicine and the European Society of Gynaecological Oncology⁶⁵, because sentinel lymph node mapping could provide important prognostic information, detect lymph node micro-metastases and avoid over-treatment with its comorbidities. However, in local tumor advanced cervical cancer stage complete lymphadenectomy should be the standard of care⁶⁶.

1.14 Sentinel lymph node in endometrial cancer

Previous studies have shown the feasibility of SLN technique of endometrial cancer. In general, the detection rate of SLN seems to be inferior (detection rate of 74.6% until 82%)^{67,68} compared to higher previous cited SLN detection rates in cervical cancer. Nevertheless, high diagnostic accuracy and reliability of SLN biopsy in endometrial cancer was shown in previous studies^{69,70}. Two large meta-analyses including several SLN detection techniques and procedures (blue dye and lymphoscintigraphy) showed that the intraoperative detection rate could reach 78%⁷¹ and 81%⁷². One recent study demonstrated the impact of SLN procedure on surgical management as well as on therapeutic indications⁷³. Another previous study showed that the preoperative lymphoscintigraphy with prolonged 2 days protocol was associated with higher number of detected SLN and with higher detection of atypical drainage especially in the para-aortal area⁶⁷.

Added to planar lymphoscintigraphy, SPECT/CT has shown to increase SLN detection rate and provided accurate anatomic information (detection rate from 77% to 93.5%)^{74,75}. Two previous studies have already compared the intraoperative SLN detection

rates between pericervical and hysteroscopic peritumoral injection in favor to pericervical injection. However, in these studies no preoperative imaging was used^{76,77}. Nevertheless, this technique is still under investigation. The best method of injection technique, the use of blue dye labeling and the time after injection (use of a short or a long protocol) in order to have a better detection rate are not yet fully determined.

So far, several methods of radiotracer injection have been employed: the direct pericervical injection, the hysteroscopic peritumoral injection and the fundal peritumoral injection. Recently, alternative methods of injection were described. A study performing myometrial radiotracer injection guided by transvaginal ultrasound showed a scintigraphic detection rate of 70.4%⁷⁸ and another small study with transcervical injection into the isthmocervical region of myometrium showed a detection rate up to 93.5 % with SPECT/CT⁷⁴.

2. Publications

2.1 Pericervical injection of Tc99m-Nanocolloid is superior to peritumoral injection for sentinel lymph node detection of endometrial cancer in SPECT/CT

Pericervical Injection of ^{99m}Tc -Nanocolloid Is Superior to Peritumoral Injection for Sentinel Lymph Node Detection of Endometrial Cancer in SPECT/CT

Samine Sahbai, MD,* Florin-Andrei Taran, MD,† Francesco Fiz, MD,* Annette Staebler, MD,‡ Sven Becker, MD,†§ Erich Solomayer, MD,†|| Diethelm Wallwiener, MD,† Christian la Fougère, MD,* Sara Brucker, MD,† and Helmut Dittmann, MD*

Purpose: Scintigraphic mapping of sentinel lymph node (SLN) is increasingly performed in patients with endometrial carcinoma although its routine clinical use is still under investigation. The purpose of this study was to compare preoperative SLN detection by means of SPECT/CT using pericervical (PC) versus hysteroscopic peritumoral (PT) injection.

Patients and Methods: One hundred forty consecutive patients with endometrial carcinoma who underwent surgery and preoperative SLN SPECT/CT with ^{99m}Tc -nanocolloid were included. Seventy women received hysteroscopic injection at 3 PT sites, and 70 women received PC injection at 3-, 6-, 9-, and 12-o'clock positions. Each patient underwent SPECT/CT followed by modified radical hysterectomy with lymphadenectomy on the day after. Histopathological results were collected for validation.

Results: Three hundred thirty-four SLNs were detected by SPECT/CT in 106 patients (mean, 3.15; range, 1–9). The detection rate after PC nanocolloid injection was 83% versus 69% after PT injection (Pearson χ^2 test, $P = 0.049$). However, PT application resulted in a higher rate of para-aortic SLNs (PC: 60% vs PT: 38% of positive scans, $P = 0.02$). SPECT/CT yielded an overall sensitivity of 70% for the SLN detection in women with lymph node metastases with 3 false-negative cases. Failure to detect SLN was mostly associated with uptake in the reticuloendothelial system (liver, spleen, and bone marrow) or peritoneal diffusion in both cohorts. Negative scans after PT application often showed a minor to even failing injection depot.

Conclusions: Pericervical injection leads to a significantly better detection rate of SLN on SPECT/CT while reducing invasiveness of the injection

procedure. Failure to detect SLN seems to be associated with major venous drainage.

Key Words: endometrial cancer, sentinel lymph node, SPECT/CT, lymphoscintigraphy, injection, nanocolloid, detection rate

(*Clin Nucl Med* 2016;41: 927–932)

Endometrial cancer (EC) is the fourth most common cancer in women in the European Union, and the eighth most common cancer for both sex worldwide.¹ With approximately 99,000 new cases diagnosed in 2012 in the European area, its incidence is continuously increasing.² Endometrial cancer is frequently diagnosed at an early stage, with a reasonably good prognosis and cure rate; for this reason, patient- and stage-tailored protocols are pivotal.^{2,3}

The treatment of choice for EC consists of modified radical abdominal hysterectomy and bilateral salpingo-oophorectomy. However, the role of lymphadenectomy remains controversial.^{4,5} In some countries, guidelines have been modified, and systematic bilateral pelvic and para-aortic lymphadenectomy is no longer recommended for patients with low- and intermediate-risk EC.^{6,7} On the other hand, lymph node (LN) status is one of the most important prognostic factors for overall survival in this entity. Accordingly, the 5-year disease-free survival rate for stage I EC patients drops from 90% to 54% if LN metastases are present at the time of diagnosis.⁸

Sentinel lymph node (SLN) mapping has been proposed as a way to strike a balance between the need for adequate staging and the avoidance of lymphadenectomy-associated morbidity, as well as a way to achieve an improved surgical staging of EC. Previous studies demonstrated the feasibility and high detection rate of SLN procedures in patients with EC using preoperative lymphoscintigraphy and intraoperative detection by γ -probe.^{9,10} Likewise, different prospective studies of SLN biopsy with cervical injection demonstrated high diagnostic accuracy and reliability with a sensitivity of 84% to 89% and a negative predictive value of 97% to 99%.^{11,12} In a meta-analysis of 26 studies with SLN biopsy in EC, including 1101 procedures, the intraoperative detection rate was 78%.¹³ Recently, the impact of SLN biopsy on surgical staging and indications for adjuvant therapies has been reported.¹⁴ However, the role of SLN mapping as well as its procedural method is still under investigation, including the site of injection, the use of blue dye labeling, and the time gap between injection and surgery (1 day vs 2 days protocol). In addition, several approaches of SLN labeling have been described yet, comprising pericervical (PC), hysteroscopic peritumoral (PT), as well as fundal PT injection.¹⁵ Recently, new injection techniques for SLN detection have been described, such as a transvaginal ultrasound-guided myometrial radiotracer injection¹⁶ or transcervical subepithelial injection into the isthmocervical region of the myometrium.¹⁷

Added to planar lymphoscintigraphy, SPECT/CT increased the preoperative SLN detection rate and provided additional valuable anatomic information (eg, detection rate up to 93.5% with SPECT/CT).^{17,18} However, discrepancies between SPECT/CT

Received for publication July 13, 2016; revision accepted August 27, 2016.

From the Departments of *Nuclear Medicine and Clinical Molecular Imaging, †Gynecology and Obstetrics, and ‡Pathology, University Hospital Tübingen; §Department of Gynecology and Obstetrics, University Hospital Frankfurt; and ||Department of Gynecology and Obstetrics, University Hospital Homburg, Germany.

Author contribution: S.S., H.D., F.T., W.D., E.S., S. Brucker, and S. Becker devised the rationale and designed the study protocol; S.S. wrote the original manuscript, collected the data, and performed the statistical analysis; C.L.F., H.D., F.T., and S. Brucker supervised the study; S.S., H.D., and F.T. analyzed and interpreted the data; S.S., E.S., S. Brucker, and S. Becker collected the surgical data; S.S., H.D., F.T., S. Brucker, C.L.F., and F.F. participated in manuscript writing, editing, and revision; S.A. contributed to interpret the histopathological results. All authors have read and approved the final version of the present manuscript. Drs Sara Brucker and Helmut Dittmann contributed equally.

Ethical approval: This article does not contain any studies with animals performed by any of the authors. All procedures performed in studies involving human participants were in accordance with the ethical standards of the institutional and/or national research committee and with the principles of the 1964 Declaration of Helsinki and its later amendments or comparable ethical standards. Informed consent was obtained from all individual participants included in the study. This study was approved by the local ethics committee of the University of Tübingen.

Conflicts of interest and sources of funding: none declared.

Correspondence to: Samine Sahbai, MD, Nuclear Medicine and Clinical Molecular Imaging, University Hospital Tübingen, Otfried-Müller-Straße 14, 72076 Tübingen, Germany. E-mail: sam.sahbai@gmail.com.

Copyright © 2016 Wolters Kluwer Health, Inc. All rights reserved.

ISSN: 0363-9762/16/4112-0927

DOI: 10.1097/RLU.0000000000001414

results and intraoperative detection rate were shown in 1 study.¹⁹ Several factors, such as protracted uptake time and insufficient tracer dose, could explain this phenomenon. Finally, further studies compared the intraoperative detection rate after PC or hysteroscopic PT injection; however, these studies did not include any imaging procedure.^{20,21}

Our study thus aimed to compare effectiveness of SLN detection with SPECT/CT using the 2 major injection techniques: PC injection or hysteroscopic PT injection in a large endometrial carcinoma population.

PATIENTS AND METHODS

In our retrospective study, 147 consecutive adult EC patients who underwent preoperative SLN procedure and surgery at the University Hospital of Tübingen between May 2006 and January 2013 were included. Four patients with histologically proven carcinosarcoma were excluded from the analysis (2 in each group); 1 patient who underwent SPECT without CT and 2 patients who did not obtain an imaging procedure before surgery were also excluded. Of the 140 remaining patients, 70 received hysteroscopic PT injection in 3 sites and 70 underwent 4 PC injections at the 3-, 6-, 9-, and 12-o'clock positions. Each patient was injected with ^{99m}Tc-labeled albumin nanocolloid (GE Healthcare, Braunschweig, Germany) the day before surgery (mean activity, 303 ± 55 MBq) in 0.8 cm³ followed by an injection of 0.5 cm³ saline to drain the remaining

TABLE 1. Histopathological Characteristics of Patients

Injection	PC, n (%)	PT, n (%)	P
Histological type			0.053
Endometrioid	59 (84)	66 (94)	
Clear cell/serous	7 (10)	3 (4)	
Mixed	4 (6)	0 (0)	
Adenosquamous	0 (0)	1 (1)	
Myometrial invasion			0.007
<50%	40 (57)	55 (79)	
>50%	30 (43)	15 (21)	
Grade			0.53
G1	34 (49)	20 (29)	
G2	17 (24)	43 (61)	
G3	19 (27)	7 (10)	
TNM stage			0.02
T1a	39 (56)	52 (74)	
T1b	20 (29)	12 (17)	
T2	6 (9)	2 (3)	
T3a	4 (6)	4 (6)	
T3b	1 (1)	0 (0)	
FIGO			0.014
IA	38 (54)	52 (74)	
IB	18 (26)	10 (14)	
II	3 (4)	2 (3)	
IIIA	2 (3)	4 (6)	
IIIB	1 (1)	0 (0)	
IIIC1	3 (4)	0 (0)	
IIIC2*	5 (7)	2 (3)	
Risk			0.004
Intermediate and high	39 (56)	22 (31)	
Low	31 (44)	48 (69)	

*One patient with isolated para-aortic micrometastasis in each cohort.

TABLE 2. Patient Baseline Characteristics

Injection	PC	PT	P
No. patients	70	70	
Age, median (range), y	65.5 (46–85)	62.0 (33–83)	0.18
Body mass index, median (range)	27.4 (19–46)	26.3 (17–46)	0.25
Mean activity, MBq	280	326	<0.001
Time p.i., median (range), h	5:12 (2:30–18:00)	5:30 (2:00–21:00)	0.73

activity from the needle. Each patient underwent preoperative SPECT/CT image acquisition at earliest 3 h p.i. or the morning thereafter. To maximize the acquisition time while limiting patient discomfort, no planar lymphoscintigraphy or dynamic imaging was performed. Reconstructed MIPs from emission data served the purpose of providing an overall tracer distribution map. SPECT/CTs were conducted with a standard dual detector γ -camera (Millennium VG Hawkeye; GE Healthcare, Chalfont St Giles, United Kingdom). SPECT acquisition parameters were as follows: 128 × 128 matrix, 60 steps, and 15 seconds acquisition time per step. Low-dose CT scan (25 mA, 140 kV, slice thickness 10 mm) was performed for attenuation correction and anatomical mapping. Images were reconstructed with an OSEM iterative reconstruction protocol (2 iterations, 10 subsets), which has shown to afford a good contrast, even in smaller activity sources²²; reconstructed data were then coregistered with CT images on a dedicated workstation (Xeleris 3 software; GE Healthcare).

All patients provided written informed consent. This study was approved by the local ethics committee of the University of Tübingen.

Modified radical hysterectomy and bilateral salpingo-oophorectomy was performed the day after. Each SLN was localized and identified with a handheld γ -probe (Neoprobe, Model 1017 and 1100 Dublin) during surgery and sent to extemporaneous examination. Further LN dissection was based on the initial tumor staging and SLN involvement. Histopathological results of SLNs, non-SLNs, and tumor staging were reviewed and analyzed.

SPECT/CT results were reviewed by 2 nuclear medicine specialists. Any focal activity in the pelvis or abdomen outside the injection area was identified as a potential SLN. Presence of at least 1 SLN was defined as positive scan. Localization, number, and side of hot spots were described. The anatomical regions were allocated

TABLE 3. Results of SPECT/CT Imaging in Dependence of Injection Technique

Injection	PC	PT	P
Patients, n	70	70	
Scan with detected SLN, n	58	48	
Detection rate, %	83	69	0.049
SLNs detected, n	184	150	
Mean SLN per patient	3.17	3.13	
Intraoperative detection rate, %*	74	52	0.01
Scans with para-aortic SLN, n (%)	22 (31)	29 (41)	0.24
% of positive scans†	38	60	0.02
Scans with bilateral SLN, n (%)	27 (39)	18 (26)	0.09
% of positive scans†	47	38	0.35

*Percentage of total patients with available report of intraoperative detection.

†% of SLN detection in a localization of total patients with positive scan.

TABLE 4. No. SLN Localized by Injections Group

Injection	PC	PT
SLNs, n	184	150
Parametrium, n (%)	5 (3)	3 (2)
Iliac, n (%)	115 (63)	74 (49)
Iliac common, n (%)	36 (20)	20 (13)
Para-aortic, n (%)	26 (14)	53 (35)
Inguinal, n (%)	2 (1)	0 (0)

to the parametric, iliac, iliac common, and para-aortic regions. To simplify the analysis, the iliac site includes both iliac external and internal sites. Bilateral scans were defined as positive scans, with at least a visible SLN on each side of the anatomical midline. The detection rate was defined as the number of patient with at least 1 SLN at the SPECT/CT images of total patients. Detection rates were compared using the Pearson χ^2 test with $P < 0.05$ considered as statistically significant. Mann-Whitney U test or Student t test for unpaired data (as appropriate) were used to compare patient baseline characteristics. SPSS Statistics 21 (IBM Inc, Armonk, NY) was used for statistical analysis.

RESULTS

Patient Characteristics

Patients were stratified according to histological findings (Table 1, tumor grade, TNM, International Federation of Gynecology and Obstetrics [FIGO], and histological subtype).²³ General characteristics in both cohorts were comparable, except for injected activity, which was significantly higher in the PT group (326 ± 49 vs 280 ± 51 ; $P < 0.001$; Table 2). A significant difference between the 2 cohorts was found for baseline myometrial depth invasion, TNM, and FIGO classification according to final histology results; no difference was found for histology type and tumor grade (Table 1).

In general, advanced stage was more frequent in the PC group ($P < 0.01$). In particular, a myometrial tumor invasion greater than 50% was observed in 30 (43%) of 70 patients in the PC group but only in 15 (21%) of 70 patients and in the PT group. Moreover, LN metastases were more frequent in the PC group (PC: 11% vs PT: 3%; $P < 0.05$).

Furthermore, the postoperative recurrence risk was classified into low-, intermediate-, and high-risk groups²⁴ (Table 1). Accordingly, low-risk patients were more prevalent in the PT group (PT: 69% vs PC: 44%; $P < 0.01$).

Regarding surgery procedures, 8 of 70 patients underwent a laparotomy in the PC cohort versus only 1 of 70 in the PT cohort

($P < 0.05$). Blue dye labeling was used in 7 of 70 patients in the PC group and only in 1 of 70 patient in the PT cohort.

Imaging Findings

In 106 of 140 patients, at least 1 SLN was identified by means of SPECT/CT imaging, resulting in an overall detection rate of 76%. A total of 334 SLNs was detected (on average, 3 per patient; range, 1–9). The overall detection rate was significantly higher with PC tracer injection (83%) as compared with hysteroscopic PT application (69%; $P < 0.05$). On the other hand, after PT injection, para-aortic SLNs were detected more frequently (PT: 60% vs PC: 38%, $P = 0.02$), which however generally exhibited a lower tracer uptake when compared with pelvic SLNs. Bilateral pelvic SLNs detection was significantly higher in the PC group (27/70) than in the PT group (18/70; $P < 0.05$). Results are summarized in Table 3.

In the PC cohort, most patients showed SLNs at the iliac/common iliac sites (Table 4); however, some women presented para-aortic SLNs and only in rare cases parametrial SLNs. Aberrant drainage was revealed by the detection of inguinal SLNs in 1 case.

In the PT cohort, most SLNs were located in the iliac and para-aortic sites (Table 4). In some cases, SLNs were found in the iliac common site and more rarely in the parametrium site. A typical example of SLN detection is shown in Figure 1. Isolated para-aortic SLNs were found in 8 cases (see Fig. 2), only one of which belonged to the PC injection group. However, this patient presented diffuse radioactivity in the abdomen, which might have obscured proximal SLNs in this particular case.

Correlation With Surgical and Pathological Findings

Complete surgical reports on the intraoperative SLN detection were available in 54 patients for PT and in 65 patients for PC injection. The calculated intraoperative detection rate was significantly higher in favor of PC injection (PC: 74% vs PT: 52%; $P = 0.01$). Histology revealed at least 1 LN metastasis in 10 (7%) of 140 patients, 8 of which belonged to the PC cohort (Table 5). Seven of 10 women with LN involvement were detected by means of SLN visualization with SPECT/CT. Two of three false-negative patients belonged to the PT cohort and one to the PC cohort. These 2 individuals had pT1b tumor stage and presented isolated para-aortic metastasis. The patient with PC injection had pT2 status at histology and presented 1 iliac as well as 1 para-aortic nodal metastasis.

As depicted in Table 5, 2 patients had SLN detection in the SPECT/CT examination on the side contralateral to the metastatic LN. One patient had bilateral LN metastases but evidence of SLN on 1 side only according to the SPECT/CT. In a case with extensive iliac and para-aortic LNs metastases, SPECT/CT imaging showed SLNs only in the iliac region. The latter case was not considered as a proper false-negative result, because SPECT/CT imaging managed to detect an involved SLN along at least one of the lymph progression pathways (Table 5).

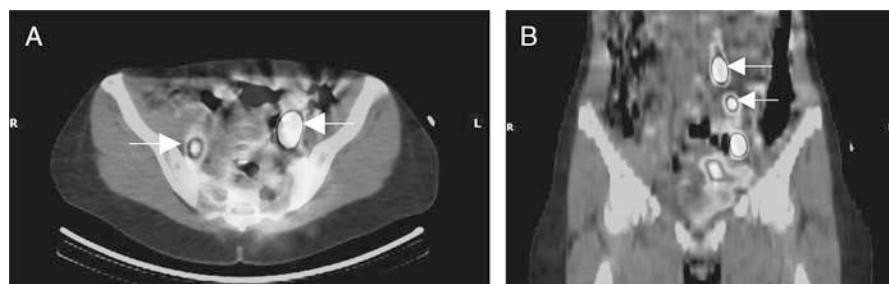


FIGURE 1. SPECT/CT scan with hot spots bilateral iliac (A), left para-aortic and left common iliac identified as SLNs (B).

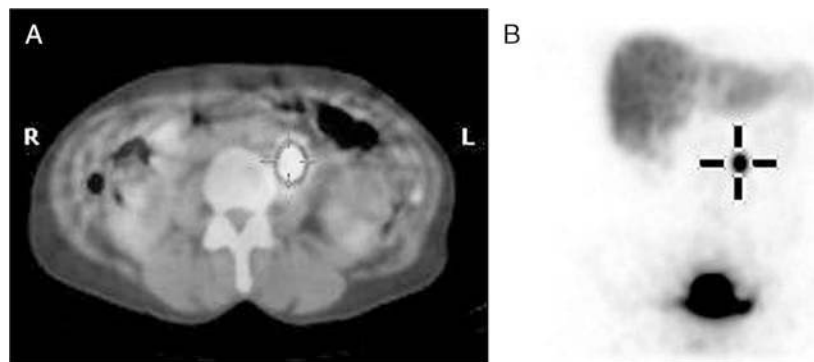


FIGURE 2. SPECT/CT (A) and MIP image (B) showing 1 hot spot identified as an isolated para-aortic SLN after PT injection.

Nanocolloid Tissue Distribution in False-Negative Cases

The 34 negative SPECT/CT scans were reviewed for specific findings (Table 6). A minor to failing injection depot was observed in one third of patients after hysteroscopic PT application but only in 1 case with PC injection. There was a strong uptake in the reticulo-endothelial system of liver and spleen in 53% of patients irrespective of injection protocol. Moreover, high bone marrow uptake was observed in negative scans in nearly one third of PT versus one quarter of PC applications. There were 8 patients with peritoneal/abdominal activity, more frequently in the PC group. Representative examples of detection failure are shown in Figure 3.

DISCUSSION

This retrospective study demonstrated a significantly better SLN detection rate by means of SPECT/CT after PC as compared with hysteroscopic-PT radiotracer application. In particular, PC injection was superior for the visualization of pelvic SLNs (external/internal and common iliac sites). To our knowledge, this is the first

study comparing SPECT/CT findings resulting from these 2 injection techniques.

Our results are in line with various studies analyzing intraoperative SLN detection both after ^{99m}Tc -nanocolloids and/or patent blue dye injection, favoring the use of PC application, as it yields a better detection rate as compared with PT injection.^{10,13,20,21,25}

Moreover, our current preoperative detection rate with SPECT/CT using PC injection is in accordance with previous studies reporting imaging-based rates ranging from 77% to 91%.^{18,19,26,27} Particularly, a detection rate of 38% for para-aortic SLNs as well as of 47% for bilateral pelvic SLNs was found in patients with positive SPECT/CT, which is compliant with published studies (25% to 44% and 35% to 57%, respectively).^{17,18}

As uterine body is a midline structure with a bilateral lymphatic drainage, it can be argued that to improve SLN biopsy as a primary staging method, bilateral LN detection on SPECT/CT images could be an essential requisite. Accordingly, in a prospective multicenter study of early cervical cancer, SLN biopsy was fully reliable only when SLNs were detected bilaterally.²⁸ On the other hand, in case of absence of demonstrable SLN uptake, a systematic lymphadenectomy could be in order, so as to decrease the false-negative rate and increase the detection of micrometastases; this concept is already being carried out for SLN procedures in cervix cancer.^{29,30}

Numerous pathological studies have demonstrated that the uterine fundus could drain via the gonadic vessels^{31,32} whereas the cervix has different primary drainage ways.³³ It has thus been confirmed that EC could spread along 2 main lymphatic connections, depending on its location: one extending to the external iliac area and the other ranging to the para-aortic area.³³ Therefore, hysteroscopic-PT injection should better mimic this pathophysiological aspect of tumor spread. In previous studies comparing both

TABLE 5. Patients With LN Metastases on Histology and SLN Detection by SPECT/CT

Injection	LN Metastases Localization	n	SPECT/CT and SLN Localization	
PT				
Patient 1	Para-aortic*	1	-	
Patient 2	Para-aortic	1	-	
PC				
Patient 1	Para-aortic	1	+	Para-aortic
Patient 2	Left iliac	1	-	
	Para-aortic*	1	-	
Patient 3	Para-aortic	1	+	Para-aortic
Patient 4	Left iliac	1	+/-	Left iliac
	Right iliac	3	+/-	
Patient 5	Right iliac	2	+/-	Left iliac
Patient 6	Right iliac	1	+	Right iliac
Patient 7	Right iliac	1	+/-	Left iliac
Patient 8	Left iliac	1	+	Left iliac
	Para-aortic	4	-	

+ indicates SLN detection in SPECT/CT; -, no SLN detection in SPECT/CT; +/-, SLN detection in SPECT/CT only in the pelvic area contralateral to the LN metastasis.

*Isolated para-aortic micrometastasis.

TABLE 6. SPECT/CT Findings in Patients With SLN Detection Failure (n = 34)

Injection	PC	PT
Patients with negative scans, n	12	22
Minor to failing injection depot, n (%)*	1 (8)	7 (32)
Liver and spleen high uptake, n (%)*	6 (50)	12 (55)
Bone marrow high uptake, n (%)*	3 (25)	8 (36)
Peritoneal/abdominal radioactivity, n (%)*	4 (33)	4 (18)
Patients in high-risk group, n (%)*	2 (17)	5 (23)
Patients with LN involvement, n (%)*	1 (8)	2 (9)

*Percentage of the 34 patients with detection failure.

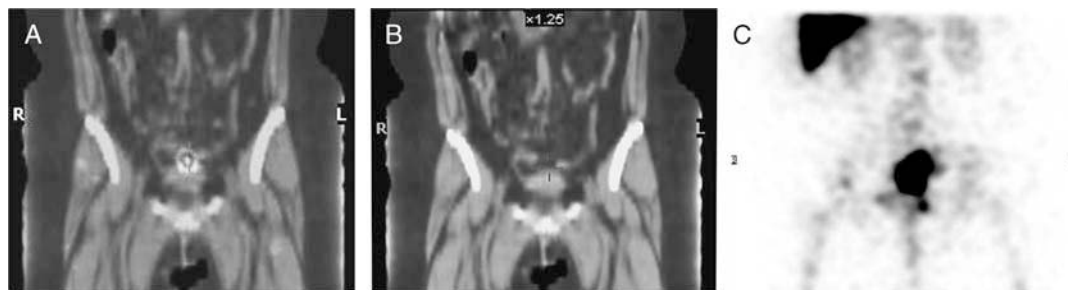

FIGURE 3. A, Case of SLN detection failure with low activity in SPECT/CT at the injection area after PT injection. B, The same case with CT alone. C, SPECT showing high activity in the liver and bone marrow. No SLN was detected.

injection methods, para-aortic SLNs were detected in lymphoscintigraphy with PT injection only (up to 56% of patients).^{21,25} However, the use of SPECT/CT imaging was shown to be capable to detect para-aortic SLNs after PC injection.^{18,19} In our study, para-aortic SLNs were detected with PC injection technique, whereas PT injection visualized para-aortic SLNs more frequently. Because para-aortic SLNs usually presented rather low nanocolloid uptake, one might speculate that the detection should be eased with attenuation corrected tomographic images as opposed to planar scintigraphy.²⁷

According to our results, failure to detect SLNs was frequently associated with high uptake in the liver, spleen, and bone marrow regardless of application mode. Because of the well-known accumulation of nanocolloids in these organs after intravenous injection, this finding is to be interpreted as a major venous drainage.^{34,35} Another factor influencing SLN detectability could be insufficient tracer deposition at the injection site or tracer extravasation, marked by peritoneal radioactivity. In fact, minor to even failing tracer depot was often demonstrated in case of missed detection. This result could be explained by a mechanical loss of radiotracer, most probably occurring during or early after injection. Of note, this finding was often seen in PT injection, whereas it was uncommon with PC application.

It has been previously been reported that metastatic involvement might affect scintigraphic SLN detection due to lymphatic drainage obstruction by neoplastic cells in breast cancer.^{36,37} In a study of EC using the patent blue dye method only, LN involvement was present in more than 50% of patients with detection failure.³⁸ Conversely, in our study, only 3 of 34 patients (8%) with negative SPECT/CT scan presented LN metastases, whereas most metastatic cases showed SLNs on SPECT/CT. Another SPECT/CT study with transcervical myometrial injection of the radiotracer revealed LN involvement in 30% (3/9) of negative scans. Of note, the overall prevalence of lymphatic metastasis was somewhat higher in that study (20%).¹⁸ In a retrospective multicenter study of early stage patients, only 1 of 20 detection failures occurred in a case with LN metastasis.³⁹

There are many parameters and factors that might influence SLN detection such as the time interval between injection and imaging, tumor biology, and patient characteristics. However, there is only limited knowledge of their contribution to SLN detection in EC. Frati et al⁹ compared a 1-day and 2-day protocol before surgery and showed a higher detection of aberrant drainage especially in the para-aortic area with the 2-day protocol. In our study, time after injection did not seem to influence SLN detection rate. Finally, mastering of the application technique is associated with a learning curve; hence, detection rates of SLNs may be linked to the surgeons' experience. Khoury-Collado et al⁴⁰ showed that an SLN detection rate of more than 90% with a false-negative rate of 0% could be attained in EC after 30 procedures. Moreover, a further evaluation indicated that even the experience of the injecting physician might

contribute to detection sensitivity.⁴¹ However, the groups of patients included in our study were subjected to the same level of practical experience with both techniques; each technique was performed by a specific and separate surgical team utilizing the SLN procedure at a comparable experience level.

In comparison to EC, there is far more scientific knowledge gained with SLN detection in breast cancer. A recent study including 1050 women confirmed that SLN identification failure was influenced by biological tumor factors,⁴² whereas another study with 164 breast cancer patients showed that patient age and nodal status significantly affected SLN localization.⁴³ However, study of tumor characteristics exceeded the scopes of the current study.

There are several limitations in our study. The analysis was based on SPECT/CT imaging results only. Intraoperative SLN detection reports were available in a fewer number of patients in each group. However, in accordance to our imaging results, an increased detection of SLN was found after PC injection. Because of the low number of SLN detection failures and of the 2 groups' comparison, factors contributing to detection failure could not be affirmatively explored. In particular, the low incidence of LN metastases in the PT cohort limits the comparison of accuracy. On the other hand, PT uterine injection is more difficult and invasive than direct cervical injection, as it requires hysteroscopic access and anesthesia.

Studies with higher numbers of patients are needed to determine the predictive parameters for detection failure to optimize protocols for SLN scintigraphy in EC.

CONCLUSIONS

Preoperative SLN detection by means of SPECT/CT imaging after PC injection of nanocolloids leads to a higher detection rate than hysteroscopic PT tracer injection. Our data support the use of the most simplified and the less invasive injection procedure that was shown to improve the accuracy of SLN mapping in patients with EC.

REFERENCES

1. Ferlay J, Soerjomataram I, Dikshit R, et al. Cancer incidence and mortality worldwide: sources, methods and major patterns in GLOBOCAN 2012. *Int J Cancer*. 2015;136:E359–E386.
2. Ferlay J, Steliarova-Foucher E, Lortet-Tieulent J, et al. Cancer incidence and mortality patterns in Europe: estimates for 40 countries in 2012. *Eur J Cancer*. 2013;49:1374–1403.
3. Bender HG. Risk-adapted therapy for cancer of the endometrium. *Eur J Obstet Gynecol Reprod Biol*. 1993;49:50.
4. Kitchener H, Swart AM, Qian Q, et al. Efficacy of systematic pelvic lymphadenectomy in endometrial cancer (MRC ASTEC trial): a randomised study. *Lancet*. 2009;373:125–136.
5. Todo Y, Kato H, Kaneuchi M, et al. Survival effect of para-aortic lymphadenectomy in endometrial cancer (SEPAL study): a retrospective cohort analysis. *Lancet*. 2010;375:1165–1172.

6. Querleu D, Planchamp F, Narducci F, et al. Clinical practice guidelines for the management of patients with endometrial cancer in France: recommendations of the Institut National du Cancer and the Société Française d'Oncologie Gynécologique. *Int J Gynecol Cancer*. 2011;21:945–950.
7. Hofmann HM, Ebner F, Haas J, et al. Magnetic resonance imaging in clinical cervical cancer: pretherapeutic tumour volumetry. *Baillieres Clin Obstet Gynaecol*. 1988;2:789–802.
8. Lurain JR, Rice BL, Rademaker AW, et al. Prognostic factors associated with recurrence in clinical stage I adenocarcinoma of the endometrium. *Obstet Gynecol*. 1991;78:63–69.
9. Frati A, Ballester M, Dubernard G, et al. Contribution of lymphoscintigraphy for sentinel lymph node biopsy in women with early stage endometrial cancer: results of the SENTI-ENDO Study. *Ann Surg Oncol*. 2015;22:1980–1986.
10. Niikura H, Okamura C, Utsunomiya H, et al. Sentinel lymph node detection in patients with endometrial cancer. *Gynecol Oncol*. 2004;92:669–674.
11. Ballester M, Dubernard G, Lécure F, et al. Detection rate and diagnostic accuracy of sentinel-node biopsy in early stage endometrial cancer: a prospective multicentre study (SENTI-ENDO). *Lancet Oncol*. 2011;12:469–476.
12. How J, Lau S, Press J, et al. Accuracy of sentinel lymph node detection following intra-operative cervical injection for endometrial cancer: a prospective study. *Gynecol Oncol*. 2012;127:332–337.
13. Kang S, Yoo HJ, Hwang JH, et al. Sentinel lymph node biopsy in endometrial cancer: meta-analysis of 26 studies. *Gynecol Oncol*. 2011;123:522–527.
14. Darai E, Dubernard G, Bats AS, et al. Sentinel node biopsy for the management of early stage endometrial cancer: long-term results of the SENTI-ENDO study. *Gynecol Oncol*. 2015;136:54–59.
15. Brucker SY, Taran FA, Wallwiener D. Sentinel lymph node mapping in endometrial cancer: a concept ready for clinical routine? *Arch Gynecol Obstet*. 2014;290:9–11.
16. Tomé A, Pahisa J, Vidal-Sicart S, et al. Transvaginal ultrasound-guided myometrial injection of radiotracer (TUMIR): a new method for sentinel lymph node detection in endometrial cancer. *Gynecol Oncol*. 2013;128:88–94.
17. Mücke J, Klapdor R, Schneider M, et al. Isthmocervical labelling and SPECT/CT for optimized sentinel detection in endometrial cancer: technique, experience and results. *Gynecol Oncol*. 2014;134:287–292.
18. Perissinotti A, Paredes P, Vidal-Sicart S, et al. Use of SPECT/CT for improved sentinel lymph node localization in endometrial cancer. *Gynecol Oncol*. 2013;129:42–48.
19. Sawicki S, Kobierski J, Łapińska-Szumczyk S, et al. Comparison of SPECT-CT results and intraoperative detection of sentinel lymph nodes in endometrial cancer. *Nucl Med Commun*. 2013;34:590–596.
20. Robova H, Charvat M, Strnad P, et al. Lymphatic mapping in endometrial cancer: comparison of hysteroscopic and subserosal injection and the distribution of sentinel lymph nodes. *Int J Gynecol Cancer*. 2009;19:391–394.
21. Niikura H, Kaiho-Sakuma M, Tokunaga H, et al. Tracer injection sites and combinations for sentinel lymph node detection in patients with endometrial cancer. *Gynecol Oncol*. 2013;131:299–303.
22. Shcherbinin S, Celler A, Belhocine T, et al. Accuracy of quantitative reconstructions in SPECT/CT imaging. *Phys Med Biol*. 2008;53:4595–4604.
23. FIGO Committee on Gynecologic Oncology. FIGO staging for carcinoma of the vulva, cervix, and corpus uteri. *Int J Gynaecol Obstet* 2014;125:97–98.
24. Lurain JR. Uterine Cancer. *Berek & Novak's Gynecology, 14th Edition*. Lippincott Williams & Wilkins; 2007;33:1343–1402.
25. Perrone AM, Casadio P, Formelli G, et al. Cervical and hysteroscopic injection for identification of sentinel lymph node in endometrial cancer. *Gynecol Oncol*. 2008;111:62–67.
26. Ballester M, Rouzier R, Coutant C, et al. Limits of lymphoscintigraphy for sentinel node biopsy in women with endometrial cancer. *Gynecol Oncol*. 2009;112:348–352.
27. Buda A, Elisei F, Arosio M, et al. Integration of hybrid single-photon emission computed tomography/computed tomography in the preoperative assessment of sentinel node in patients with cervical and endometrial cancer: our experience and literature review. *Int J Gynecol Cancer*. 2012;22:830–835.
28. Lécure F, Mathevet P, Querleu D, et al. Bilateral negative sentinel nodes accurately predict absence of lymph node metastasis in early cervical cancer: results of the SENTICOL study. *J Clin Oncol*. 2011;29:1686–1691.
29. Martínez A, Zerdoud S, Mery E, et al. Hybrid imaging by SPECT/CT for sentinel lymph node detection in patients with cancer of the uterine cervix. *Gynecol Oncol*. 2010;119:431–435.
30. Cibula D, Abu-Rustum NR, Dusek L, et al. Bilateral ultrastaging of sentinel lymph node in cervical cancer: lowering the false-negative rate and improving the detection of micrometastasis. *Gynecol Oncol*. 2012;127:462–466.
31. Henriksen E. The lymphatic dissemination in endometrial carcinoma. A study of 188 necropsies. *Am J Obstet Gynecol*. 1975;123:570–576.
32. Yokoyama Y, Maruyama H, Sato S, et al. Indispensability of pelvic and paraaortic lymphadenectomy in endometrial cancers. *Gynecol Oncol*. 1997;64:411–417.
33. Lécure F, Neji K, Robin F, et al. Lymphatic drainage of the uterus. Preliminary results of an experimental study [in French]. *J Gynecol Obstet Biol Reprod (Paris)*. 1997;26:418–423.
34. Saba TM. Physiology and physiopathology of the reticuloendothelial system. *Arch Intern Med*. 1970;126:1031–1052.
35. Klingensmith WC 3rd, Spitzer VM, Fritzbeg AR, et al. Normal appearance and reproducibility of liver-spleen studies with Tc-99m sulfur colloid and Tc-99m microalbumin colloid. *J Nucl Med*. 1983;24:8–13.
36. Eldweny H, Alkhalidy K, Alsaleh N, et al. Predictors of non-sentinel lymph node metastasis in breast cancer patients with positive sentinel lymph node (Pilot study). *J Egypt Natl Canc Inst*. 2012;24:23–30.
37. Coufal O, Zapletal O, Vrtělová P, et al. Failed preoperative lymphoscintigraphy for sentinel lymph node biopsy in breast cancer, possible causes and implications for the surgery—the analysis of 3014 procedures [in French]. *Rozhl Chir*. 2015;94:126–130.
38. Lopes LA, Nicolau SM, Baracat FF, et al. Sentinel lymph node in endometrial cancer. *Int J Gynecol Cancer*. 2007;17:1113–1117.
39. Raimond E, Ballester M, Hudry D, et al. Impact of sentinel lymph node biopsy on the therapeutic management of early-stage endometrial cancer: results of a retrospective multicenter study. *Gynecol Oncol*. 2014;133:506–511.
40. Khoury-Collado F, Glaser GE, Zivanovic O, et al. Improving sentinel lymph node detection rates in endometrial cancer: how many cases are needed? *Gynecol Oncol*. 2009;115:453–455.
41. Dittmann H, Becker S, Bares R. Detection of sentinel lymph nodes after hysteroscopic peritumoral injection of Tc-99m-Nanocolloid in grade 1 endometrial carcinoma. *J Nucl Med Meeting Abstracts*. 2010;51:18.
42. Bernardi S, Bertozzi S, Londero AP, et al. Prevalence and risk factors of intraoperative identification failure of sentinel lymph nodes in patients affected by breast cancer. *Nucl Med Commun*. 2013;34:664–673.
43. Dordea M, Colvin H, Cox P, et al. Clinical and histopathological factors affecting failed sentinel node localization in axillary staging for breast cancer. *Surgeon*. 2013;11:63–66.

2.2 Sentinel lymph node mapping using SPECT/CT and gamma probe in endometrial cancer: an analysis of parameters affecting detection rate

Sentinel lymph node mapping using SPECT/CT and gamma probe in endometrial cancer: an analysis of parameters affecting detection rate

Samaneh Sahbai¹ · Florin-Andrei Taran² · Annette Staebler³ · Diethelm Wallwiener² · Christian la Fougère¹ · Sara Brucker² · Helmut Dittmann¹

Received: 31 December 2016 / Accepted: 23 March 2017
© Springer-Verlag Berlin Heidelberg 2017

Abstract

Purpose SPECT/CT after pericervical injection of technetium-99 m-nanocolloid was shown to be suitable for sentinel lymph node (SLN) mapping in endometrial cancer (EC). The aim of this study was to analyze factors affecting successful SLN detection by means of SPECT/CT such as imaging findings, patient characteristics and tumor biology in a large cohort of patients.

Methods One hundred and forty-five consecutive patients suffering from EC who received pre-surgical SLN mapping at our institution between 2011 and 2016 were included in this analysis. SPECT/CT data of abdomen and pelvis (mean 4:20 ± 1:20 h p.i.) were acquired after pericervical injection of technetium-99 m-nanocolloid (mean 230 ± 45 MBq) in all patients. Surgical staging was performed on the day after. Acquisition parameters, patient characteristics, SPECT/CT findings as well as histopathological results were collected.

Results A total of 282 SLNs were identified by means of SPECT/CT. Overall, preoperative and intraoperative SLN detection rates were 86%, 76% and 74% respectively. The most important factor associated with failure to detect SLNs was the presence of high bone marrow on SPECT/CT ($p = 0.005$). Peritoneal/abdominal radioactivity was also associated with

missed SLN detection in SPECT/CT ($p = 0.02$). However, the presence of liver/spleen uptake on its own was not predictive for detection failure. Low numbers of detected SLNs in SPECT/CT were slightly related with older age and lower injected activity. No significant influence was found for the parameters of tumor histology and stage, lymph node involvement and the time gap between injection and imaging.

Conclusions Venous drainage as indicated by bone marrow uptake is the most important factor associated with scintigraphic SLN detection failure. Moreover, high peritoneal and abdominal activity was also associated with detection failure. Thus, meticulous application of the radiotracer is crucial in EC.

Keywords Endometrial cancer · Sentinel lymph node · Detection failure · SPECT/CT · Lymphoscintigraphy · Nanocolloid

Introduction

Endometrial cancer (EC) is the fourth most common cancer in women in European countries and the third most common in the USA [1, 2]. The role of lymph node dissection in EC is still under discussion and controversial. Several studies showed no benefit for overall and recurrence-free survival in early stage EC, but an increased risk of surgical morbidity and adverse events after lymphadenectomy [3, 4]. On the other hand, two different studies revealed a significant longer overall survival after lymphadenectomy in case of intermediate or high risk of recurrence [5]. However, the debate regarding the design of the studies is ongoing. Nevertheless, sentinel lymph node (SLN) mapping in patients with apparent early-stage EC was shown to improve detection of metastases, which in turn was associated with increased use of adjuvant therapy [6]. The use

S. Sahbai, F.A. Taran, H. Dittmann and S. Brucker contributed equally.

✉ Samaneh Sahbai
sam.sahbai@gmail.com

¹ Nuclear Medicine and Clinical Molecular Imaging, University Hospital Tuebingen, Otfried-Müller-Straße 14, 72076 Tübingen, Germany

² Gynecology and Obstetrics, University Hospital Tuebingen, Tuebingen, Germany

³ Pathology, University Hospital Tuebingen, Tuebingen, Germany

of SLN biopsy in patients with EC might, thus, have the potential to decrease intraoperative and postoperative morbidity associated with systematic lymphadenectomy and, nevertheless, allow adequate surgical staging [7].

Scintigraphic mapping and biopsy of SLNs is increasingly performed in many gynecological centers aiming at an improved surgical staging in patients with EC [8]. It has been shown that use of the SLN approach is as effective as the classical systematic lymphadenectomy for lymph node (LN) metastases detection in early stage EC patients while no difference for disease free survival was seen [9]. In other tumor entities like early stage breast cancer (T1 - T2) and malignant melanoma the use of SLN techniques is well established in clinical routine [10, 11]. Yet, in EC the SLN procedure is not used in clinical routine, and the detection rate is somewhat lower when compared to breast cancer or cervical cancer.

A meta-analysis of 26 studies on SLN biopsy in EC including a total of 1101 procedures with radioisotope and/or blue dye method showed an intraoperative detection rate of 78% [12]. In contrast, two recent meta-analyses showed higher scintigraphic SLN detection rates up to 98.6% and 100% in cervical cancer and breast cancer, respectively [13, 14].

In EC patients, imaging-based preoperative detection rates with SPECT/CT were reported from 77% up to 91% using pericervical radiotracer injection [15–17] and thus to be higher compared to planar scintigraphy (68%) [18]. However, previous studies also revealed that SLN detection rates in EC were influenced by the radiotracer application method employed. Higher detection rates were found after pericervical injection as compared to peritumoral application in both pre-surgical imaging with planar scintigraphy [19] and SPECT/CT [20] as well as for intra-surgical SLN detection by means of gamma hand probe [12]. Besides the injection technique, other parameters are supposed to influence the SLN detection rate such as the time gap between injection and imaging, tumor biology and patient characteristics as well as the experience of the injecting physician [21–25]. Therefore, we aimed to analyze factors which could influence successful SLN detection after pericervical injection such as imaging findings in SPECT/CT, technical and clinical variables as well as tumor characteristics in a large cohort of patients suffering from EC.

Materials and methods

In our prospective study, 145 consecutive patients with histologically proven EC underwent preoperative SLN procedure and surgical staging at the University Hospital of Tuebingen between 2011 and 2016. All patients underwent a pericervical injection at 3, 6, 9 and 12 o'clock positions. Each patient was injected with technetium-99 m-nanocolloid (Nanocoll®, GE Healthcare, Braunschweig, Germany) 1 day before surgery (mean 230 ± 45 MBq) in 0.8 cm^3 added by an injection of

0.5 cm^3 saline to drain the remaining radioactivity from the needle. The injecting physician verified that the needle tip did avoid blood vessels by aspirating just before injection.

SPECT/CT protocol

Preoperative imaging with SPECT/CT was performed at 3–5 h p.i. (mean $4:20 \pm 1:20$). Patients were scanned from pelvis to caudal liver on a hybrid SPECT/CT device (Millennium VG Hawkeye®; GE Healthcare, Chalfont St Giles, UK and since October 2014 on a Discovery 670 Pro®, GE Healthcare, Chicago, USA). SPECT acquisition parameters were for both devices as follows: 128×128 matrix, 15 s acquisition time per step and 30 steps for Discovery 670 Pro®, but 60 steps for Millennium VG Hawkeye®. Low dose CT scan was performed for attenuation correction and anatomical mapping (2.5 mA, 140 kV, slice thickness 10 mm, 40 slices interpolated to 90 slices for Millennium VG Hawkeye® and smart dose 10–80 mA, 120 kV, slice thickness 2.5 mm and 161 slices for Discovery 670 Pro®). Image reconstruction and fusion were performed using a Xeleris® 3 software package (GE Healthcare, Chicago, USA). SPECT image reconstruction was similar for both devices using an ordered subset expectation maximization (OSEM) protocol with two iterations and ten subsets. The voxel size was 4.42 mm^3 .

SLN biopsy

Surgical staging was performed by laparoscopy the day after. Blue dye was intracervically injected at 3 and 9 o'clock positions (0.2 cm^3 per injection) in all patients, right before surgery. Each SLN was localized and identified using a handheld gamma probe (Neoprobe®, Models 1017 and 1100, Dublin, USA) during surgery and afterwards sent to instantaneous sectioning. The indication for systematic lymphadenectomy was based on tumor staging by instantaneous section of the uterus and SLN involvement. Histopathological results of SLNs, non SLNs and staging of tumors were collected and analyzed.

SLN detection

Imaging results (SPECT/CT) were analyzed by two experienced nuclear medicine specialists and reported in consensus. Any focal activity in an adequate anatomical lymphatic region with or without delineated lymph node in the CT images was identified as SLN. Presence of at least one SLN was defined as successful SLN detection in SPECT/CT. Further imaging findings, such as presence of radiotracer uptake in the liver/spleen, in bone marrow and in the peritoneal/abdominal area were visually analyzed for each patient. Patients' characteristics (age and BMI) and the time gap between injection and imaging were collected. In addition, tumor type, TNM stage

and grading as well as LN involvement, histological type and tumor grade after surgery were included in the analysis. Surgical reports and intraoperative detection of SLN were reviewed.

Preoperative or intraoperative SLN detection was defined as the number of patients with at least one detected SLN.

Statistical analysis

A Mann-Whitney U test was performed as adequate for qualitative variables and ANOVA linear regression was used for the univariate analysis of quantitative parameters as adequate. In addition, the Pearson correlation coefficient was employed to compare preoperative and intraoperative SLN detection methods. SPSS Statistics 21 software (IBM Inc., Armonk, NY, USA) was used for statistical analysis; $p < 0.05$ was considered as statistically significant.

The study was approved by the local ethics committee. All patients provided written informed consent.

Results

Patient characteristics and imaging results

The mean age of the patients was 63 ± 11 years and the mean BMI was 30 ± 6 ; detailed patients characteristic are shown in Table 1. A total of 282 SLNs were identified by means of SPECT/CT, and the overall scintigraphic SLN detection rate was 76% with 110 of 145 patients showing at least one SLN on the SPECT/CT scan. Detected SLNs were most frequently located in the internal or external iliac region near to the uterus (57%), sometimes in the iliac common (26%), less frequently in the para-aortic region (13%) and only rarely seen at parametrial, obturatoric and presacral sites (from 0.7% to 2.8%). The detailed distribution of detected SLNs in the main anatomical regions is depicted in Table 2. Distant drainage was seen in 28% and 52% of patients with SLN detection in the para-aortic and common iliac region, respectively. Exclusive atypical SLN distribution was seen in only three cases: one patient showed SLNs solely in the common iliac region, one presented inguinal SLNs and a third patient showed para-aortic SLN exclusively. Remarkably, no significant difference was found between the two used SPECT/CT devices for SLN detection rate (79% vs. 72%; $p = 0.4$) as well as for the obtained imaging results (see Table 3).

Failure to detect SLN was associated with the presence of substantial bone marrow uptake on SPECT/CTs (43% vs. 19%; $p = 0.005$). Likewise, the presence of high peritoneal/abdominal radioactivity was also associated with detection failure (20% vs. 7%; $p = 0.02$). Liver and spleen uptake was seen on the majority of SPECT/CT scans. On its own, this imaging feature was not predictive of detection failure, but

Table 1 Patient baseline characteristics

Number of patients	145
Mean age in years (range)	63.0 (32–88)
Mean BMI (range)	29.7 (17–52)
Mean activity in MBq (range)	230 (149–346)
Mean time p.i. (hours, SD)	4:20 (\pm 1:20)
	Number of patients
Histological Type	
Endometrioid	140
Serous	4
Adenosquamous	1
Myometrial invasion	
< 50%	101
> 50%	44
Grade	
G1	82
G2	34
G3	29
TNM Stage	
T1a	103
T1b	28
T2	6
T3a	5
T3b	3
FIGO	
IA	101
IB	27
II	3
IIIA	3
IIIB	2
IIIC1	2
IIIC2*	6
IV	1

*one patient with isolated para-aortic micrometastasis

almost equally present in case of successful detection (79% vs. 83%). For detailed results refer to Table 4. Of note, all patients with bone marrow uptake also had intensive liver and spleen uptake. Age, BMI and both injected activity as well as the time interval between injection and imaging were not significantly different for SLN detection versus no detection respectively (63 vs. 63 ; $p = 0.5$; 30 vs. 29 ; $p = 0.3$; 230 vs. 228 MBq; $p = 0.7$ and $4:23$ vs. $4:13$; $p = 0.9$; see Table 5). Para-aortic SLN detection was associated with a somewhat higher injected activity (mean 250 vs. 224 MBq; $p = 0.003$). No significant parameters influencing the detection of bilateral SLN were found. Fig. 1 demonstrates typical examples of imaging results in a patient with successful SLN mapping and Fig. 2 represents another patient where SPECT/CT failed to detect any SLN.

Table 2 SLNs distribution in SPECT/CT

	Right Hemipelvis (<i>n</i> = 159) SLN (<i>n</i>)	Left Hemipelvis (<i>n</i> = 123) SLN (<i>n</i>)	Total (<i>n</i> = 282) <i>n</i> (%) [*]
Para-aortic	11	25	36 (13)
Common iliac	50	23	73 (26)
Iliac	95	66	161 (57)
Obturator/Parametrium	2	6	8 (2.8)
Presacral	1	1	2 (0.7)
Inguinal	0	2	2 (0.7)

*percentage of total detected SLNs in SPECT/CT

Number of SLNs detected in SPECT/CT

The number of total detected SLNs for each patient in SPECT/CT was also collected. Univariate analysis using ANOVA linear regression showed only a poor correlation for older age and for lower injected activity with the decrease of total detected SLNs ($p = 0.04$ for both; $r^2 = 0.03$; see Fig. 3).

Intraoperative SLN detection

Using a gamma hand probe during surgery, at least one SLN was detected in 107 of 145 patients. Thus, the calculated intraoperative detection rate was 74%. Similar to preoperative results, intraoperative detection failure was significantly associated with the presence of bone marrow uptake on SPECT/CT imaging (40% vs. 20%; $p = 0.015$; see Table 4).

SLN detection and tumor stage

According to our analysis, both SPECT/CT and intraoperative SLN detection rate was not influenced by tumor grade, histology or stage. Importantly, LN involvement did not seem to affect detection since SLNs were detected on SPECT/CT in 7/9 cases with histologically verified LN metastasis. Moreover, no correlation was found between tumor stage and the presence of bone marrow uptake.

Table 3 Comparison of imaging results between both used SPECT/CT devices

SPECT/CT	Millennium VG Hawkeye®	Discovery 670 Pro®	<i>p</i> value
Patients (<i>n</i>)	73	72	
SLN detection rate (%)	79%	72%	0.4
Bone marrow uptake (%) [*]	19%	28%	0.2
Peritoneal/abdominal activity (%) [*]	13%	6%	0.2
Liver/spleen uptake (%) [*]	81%	81%	n.s.

*percentage of total scanned patients in each group

Comparison of preoperative and intraoperative SLN detection

Comparing the preoperative and intraoperative scintigraphic detection for each patient, there was a discrepancy in a total of 35 patients. Remarkably, 16 patients with detection failure on SPECT/CT had recognizable SLNs at surgery. Predominantly, SLNs were identified by a gamma hand probe, but 3/16 patients showed SLNs only by blue dye staining. In contrast, intraoperative examination failed to identify SLNs in 19 patients who had previously shown SLNs at SPECT/CT. The Pearson correlation between intraoperative and preoperative scintigraphic overall detection of SLN was poor but significant ($r = 0.39$; $p = 0.01$). The calculated rate of discrepancy was 24% (35/145). However, by combining the preoperative and intraoperative SLN detection method, the overall SLN detection rate attained 86%.

Discussion

The rationale for using SLN detection and biopsy in patients with EC results from the known high morbidity after standard lymphadenectomy but only low prevalence of lymph node metastases. Yet, lymphatic drainage from the uterus is ramified and complex, so that an accurate pre-surgical detection of the SLN is highly desirable. The use of technetium-99 m labeled colloids for SLN mapping enables a pre-surgical and intra-surgical detection of SLN, but can also be associated with detection failure, thus necessitating the additional use of blue dye or a complete lymphadenectomy. Due to the lack of large studies in EC patients, only limited knowledge about factors affecting the SLN detection rate is available. As we have previously shown, SLN detection failure in EC was seen more frequently with the presence of high uptake in liver, spleen and bone marrow irrespective of the application mode used [20]. This finding indicated a significant amount of radioactivity being drained via blood vessels rather than via lymphatic flow [26]. In addition, in patients suffering from breast cancer other factors affecting the scintigraphic SLN detection were suggested such as metastatic involvement of

Table 4 Comparison of imaging results in SPECT/CT and during surgery with a gamma hand probe between SLN detection and no detection

SPECT/CT	No SLN	SLN	<i>p</i> value
Patients (n)	35	110	
Bone marrow uptake (%)*	43%	19%	0.005
Peritoneal/abdominal activity (%)*	20%	7%	0.02
Liver/spleen uptake (%)*	79%	83%	0.6
Detection rate (%)*	76%		
Gamma hand probe			
Patients (n)	38	107	
Bone marrow uptake (%)*	40%	20%	0.015
Peritoneal/abdominal activity (%)*	16%	8%	0.1
Liver/spleen uptake (%)*	87%	78%	0.3
Detection rate (%)*	74%		

*percentage of total scanned patients in each group

LN's due to lymphatic drainage obstruction by neoplastic cells or the age of the patients [27, 28].

Our analysis of SLN detection in patients with EC showed that bone marrow uptake was associated with a significantly lower detection rate and, consequently, was the most important factor associated with SLN detection failure by both preoperative SPECT/CT imaging as well as by intraoperative gamma probe measurement. In addition, our findings also showed that the presence of abdominal/peritoneal uptake was associated with SLN detection failure in SPECT/CT. To our knowledge, this is the first systematical report on factors potentially influencing the SLN detection rate in EC. A recent study in cervical cancer demonstrated that older age was associated with unilateral detection and that both older age and BMI were associated with a reduced number of detected SLNs [29]. In view of these results, it might be expected that detection failure could be correlated with BMI in EC patients as well; however we did not ascertain a significant association in our study. Moreover, our analysis did not reveal any factors related to unilateral SLN detection. A previous study showed a better preoperative detection rate and a higher number of intraoperative detected SLNs when the injection of radiotracer was performed the day before surgery in favor of a long protocol in comparison to a 1-day protocol (preoperative

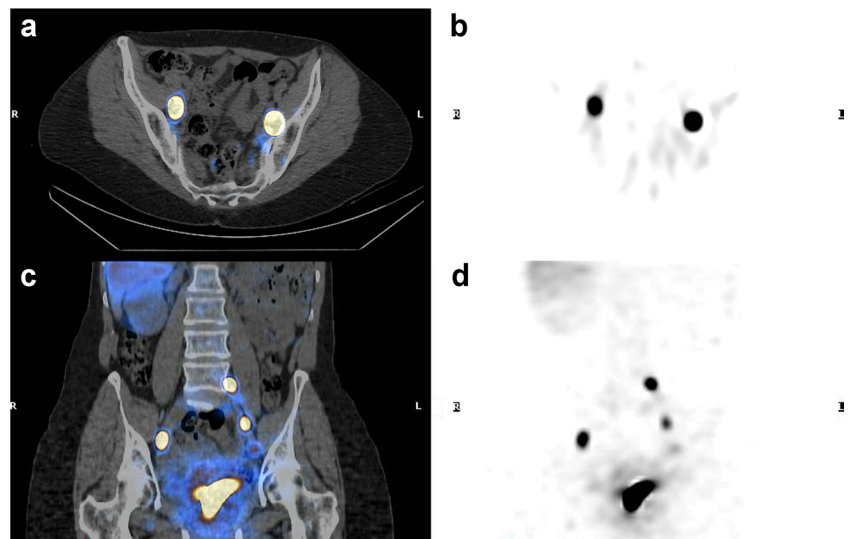
Table 5 Analyzed patients characteristics and SLN detection in SPECT/CT

SPECT/CT	No SLN	SLN	<i>p</i> value
Patients (n)	35	110	
Mean age (years)	63	63	0.5
Mean BMI	29	30	0.3
Mean activity (MBq)	228	230	0.7
Mean time p.i. (hours)	4:13	4:23	0.9

detection rate of 80% vs. 62%, respectively) [21]. However, in our study all patients underwent injection exclusively 1 day before surgery (long protocol) and no significant correlation with time gap between injection and imaging for both SLN detection rate and number of detected SLNs was found. Nevertheless, there was only a loose correlation between number of detected SLNs in SPECT/CT and injected activity as well as lower patient age. A previous study on prostate cancer suggested an injection of 200 MBq technetium-99 m-nanocolloid instead of 60 MBq in order to avoid detection failure on SLN procedure in planar lymphoscintigraphy [30]. In contrast, our study comprised only a higher range of injected activities and lymphoscintigraphy with SPECT/CT. Within the dose range used, our analysis did not show any significant influence of injected activity on detection rate on a per-patient basis. Based on the earlier work, it could be hypothesized that higher injected activity is required for deep pelvic SLN detection in contrast to the more superficial SLNs as, e.g., in breast cancer. However, our study is not designed to define the minimum activity level needed for successful SLN detection. Surprisingly, liver and spleen uptake was seen in about 80% of our patients, but this pattern was not significantly associated with SLN detection failure. In our work, the same nanocolloid particles were used throughout and standardized injection procedures were performed by the same well-trained medical team in all patients. In particular, before each injection the needle position was controlled by aspiration to avoid intravenous application, thus current findings should not have been biased by such technical factors.

Remarkably, the presence of bone marrow uptake was systematically associated with the presence of liver/spleen uptake. Previously, it has been shown that technetium-99 m-nanocolloid could be transported via direct blood drainage in patients receiving injections into the prostate gland [31]. In case of lymphedema or lymphatic dysfunction, several studies demonstrated that direct lymphovenous communication might exist [32, 33]. A quantitative SPECT study after i.v. injection of different technetium-99 m labeled nanocolloids, which are also suitable for bone marrow scintigraphy, has shown much higher liver and spleen uptake compared to bone marrow uptake [34]. Therefore, we conclude that the presence of bone marrow uptake indicates particularly high venous drainage of the radiotracer provoked by serious tissue injuries at the injection points. It could be hypothesized that some venous drainage is present in the majority of patients as indicated by liver/spleen uptake, while bone marrow uptake is seen only in patients with particularly a large amount of venous activity, which in turn might lead to insufficient tracer deposition at injection sites. Remarkably, the presence of high peritoneal and abdominal activity was seen in 20% of cases without SLN detection in SPECT/CT. This finding could be interpreted as missed injection leading to high background activity which may mask potential lymph node uptake.

Fig. 1 Transverse fused SPECT/CT (a) with corresponding SPECT (b) showing bilateral iliac SLNs detection. Coronal fused SPECT/CT (c) with corresponding SPECT (d) showing the injection site, bilateral iliac SLNs and one left iliac common SLN. Note low liver uptake and no significant bone marrow uptake



However, some patients failed SLN detection without signs of major venous drainage or potentially disturbing activity. In these patients, no other variables were found to be associated with detection failure taking into consideration that the imaging results were evaluated only visually. It might, therefore, be concluded that insufficient lymphatic drainage is the cause of detection failure in a subgroup of patients with EC.

In addition to the issues discussed above, other patient-related factors like BMI or age [35] as well as the presence of metastatic involvement of LNs causing lymphatic drainage obstruction have been proposed to influence SLN detection in breast cancer [27, 28]. Moreover, a survey confirmed that a high number of LN metastases was correlated with detection failure in breast cancer [36]. In contrast, SLN detection rate was not influenced by any clinical or technical variables [37], SLN involvement or LN metastases in other studies of breast

cancer patients [35, 37]. In our study of EC patients, similar to the latter studies, scintigraphic SLN detection rate was not associated with tumor type, grade or LN involvement. Currently, the overall SLN detection rate might have been influenced by the low number of patients with advanced LN metastases. Obviously, an extended metastatic LN involvement will be expected to affect SLN detection rate also in EC. Regarding local tumor staging, it could be assumed that an extension to the cervix will increase the number of blood vessels which might in turn favor venous drainage from the injection points. However, we did not find a correlation between the presence of bone marrow uptake and locally advanced tumor stage in our cohort.

Similar to previous studies, there was a poor correlation between preoperative and intraoperative detection of SLNs [16, 38]. This could be due to the long time gap between

Fig. 2 Transverse fused SPECT/CT (a) with corresponding SPECT (b) and coronal fused SPECT/CT (c) with corresponding SPECT (d) showing the injection site, high liver/spleen uptake, bone marrow uptake and no SLN detection

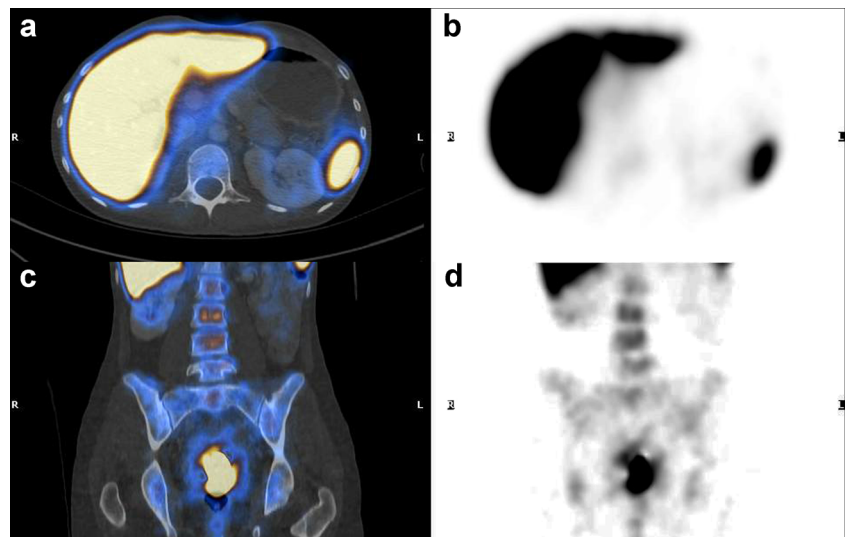
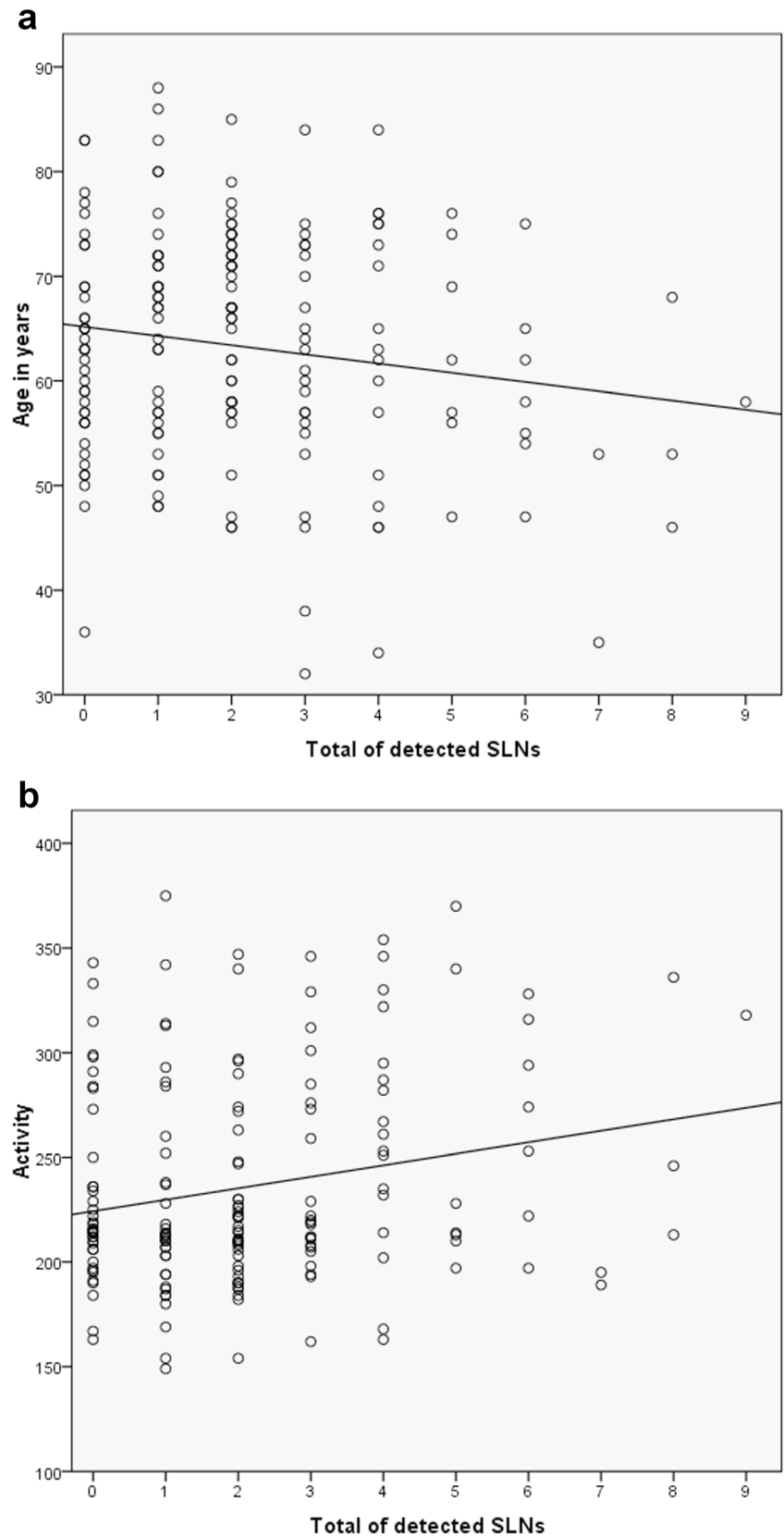


Fig. 3 Correlation of patient age (a) and injected activity (b) with number of total detected SLNs in SPECT/CT ($r^2 = 0.03$; $p = 0.04$)



imaging and surgery; in particular, detected SLNs in SPECT/CT could have possibly lost activity at time of surgery since

the radiotracer could have been washed out through lymphatic flow. Another factor could be a high background activity in

the liver/spleen and in the injection area, which might disturb the detection of SLNs in specific anatomical regions with the gamma probe.

Considering common iliac and paraaortic areas as uncommon SLN drainage pathways, our study showed a slightly higher detection rate in these areas in comparison to a previously published study (26% vs. 24% and 13% vs. 6% for common iliac and paraaortic, respectively) [21]. Remarkably, exclusive atypical SLN location was rarely seen in our cohort.

There are a few limitations in our study. The analysis was focused on visual preoperative imaging results. Thus, an individual lesion by lesion comparison of imaging and intraoperative SLN findings was not feasible. As a consequence, imaging and surgical detection could only be compared on a per patient basis. In view of the discrepancies seen between intraoperative and preoperative SLN detection it would be desirable to analyze regional detectability, e.g., near to the liver (high background for the gamma probe) or near to the injection area. Otherwise, the overall low frequency of LN involvement and of locally advanced tumors in our cohort could limit the statistical significance regarding its influence on the SLN detection rate. A potential limitation of this study is the use of two SPECT/CT devices with different CT slice thickness. However, we observed no significant difference of SLN detection rate as well as for analyzed imaging variables between both SPECT/CT systems. Since the evaluation of SLN detection was based primarily on SPECT images and regarding the typically high ratio of lesion to background, a critical methodic bias is not to be expected from the use of two different devices.

Conclusions

Some venous drainage of technetium-99 m-nanocolloid is present in the majority of EC patients investigated by SPECT/CT for SLN mapping. Bone marrow uptake indicates particularly high blood drainage, which is significantly associated with failure to detect SLN both pre-operatively in lymphoscintigraphy and during surgery with a gamma probe. Additionally, the presence of high abdominal and peritoneal activity was also associated with SLN detection failure. Therefore, meticulous application of the radiotracer is crucial in EC. The presence of LN metastases as well as tumor grade and stage did not affect preoperative SLN detection rate in our cohort of predominantly low to intermediate stages of EC.

Compliance with ethical standards

Conflict of interest The authors declare that they have no conflict of interest.

Ethical approval All procedures performed in studies involving human participants were in accordance with the ethical standards of the institutional and/or national research committee and with the 1964 Helsinki Declaration and its later amendments or comparable ethical standards.

Informed consent Informed consent was obtained from all individual participants included in the study.

References

1. Ferlay J, Steliarova-Foucher E, Lortet-Tieulent J, Rosso S, Coebergh JW, Comber H, et al. Cancer incidence and mortality patterns in Europe: estimates for 40 countries in 2012. *Eur J Cancer (Oxf, Engl: 1990)*. 2013;49:1374–403. doi:10.1016/j.ejca.2012.12.027.
2. Siegel RL, Miller KD, Jemal A. Cancer statistics, 2015. *CA Cancer J Clin*. 2015;65:5–29. doi:10.3322/caac.21254.
3. Frost JA, Webster KE, Bryant A, Morrison J. Lymphadenectomy for the management of endometrial cancer. The Cochrane database of systematic reviews. 2015:CD007585. doi:10.1002/14651858.CD007585.pub3.
4. Bogani G, Dowdy SC, Cliby WA, Ghezzi F, Rossetti D, Frigerio L, et al. Management of endometrial cancer: issues and controversies. *Eur J Gynaecol Oncol*. 2016;37:6–12.
5. Todo Y, Kato H, Kaneuchi M, Watari H, Takeda M, Sakuragi N. Survival effect of para-aortic lymphadenectomy in endometrial cancer (SEPAL study): a retrospective cohort analysis. *Lancet (Lond, Engl)*. 2010;375:1165–72. doi:10.1016/s0140-6736(09)62002-x.
6. Holloway RW, Gupta S, Stavitzki NM, Zhu X, Takimoto EL, Gubbi A, et al. Sentinel lymph node mapping with staging lymphadenectomy for patients with endometrial cancer increases the detection of metastasis. *Gynecol Oncol*. 2016;141:206–10. doi:10.1016/j.ygyno.2016.02.018.
7. Leitao Jr MM, Khoury-Collado F, Gardner G, Sonoda Y, Brown CL, Alektiar KM, et al. Impact of incorporating an algorithm that utilizes sentinel lymph node mapping during minimally invasive procedures on the detection of stage IIIC endometrial cancer. *Gynecol Oncol*. 2013;129:38–41. doi:10.1016/j.ygyno.2013.01.002.
8. Khoury-Collado F, St Clair C, Abu-Rustum NR. Sentinel lymph node mapping in endometrial cancer: an update. *Oncologist*. 2016;21:461–6. doi:10.1634/theoncologist.2015-0473.
9. Zahl Eriksson AG, Ducie J, Ali N, McGree ME, Weaver AL, Bogani G, et al. Comparison of a sentinel lymph node and a selective lymphadenectomy algorithm in patients with endometrioid endometrial carcinoma and limited myometrial invasion. *Gynecol Oncol*. 2016;140:394–9. doi:10.1016/j.ygyno.2015.12.028.
10. Gherghe M, Bordea C, Blidaru A. Sentinel lymph node biopsy (SLNB) vs. axillary lymph node dissection (ALND) in the current surgical treatment of early stage breast cancer. *J Med life*. 2015;8:176–80.
11. New ASCO, SSO guidelines for sentinel lymph node biopsy in melanoma. *Oncology (Williston Park, NY)*. 2012;26:841–2.
12. Kang S, Yoo HJ, Hwang JH, Lim MC, Seo SS, Park SY. Sentinel lymph node biopsy in endometrial cancer: meta-analysis of 26 studies. *Gynecol Oncol*. 2011;123:522–7. doi:10.1016/j.ygyno.2011.08.034.
13. Ahmed M, Purushotham AD, Horgan K, Klaase JM, Douek M. Meta-analysis of superficial versus deep injection of radioactive tracer and blue dye for lymphatic mapping and detection of sentinel lymph nodes in breast cancer. *Br J Surg*. 2015;102:169–81. doi:10.1002/bjs.9673.

14. Hoogendam JP, Veldhuis WB, Hobbelen MG, Verheijen RH, van den Bosch MA, Zweemer RP. 99mTc SPECT/CT versus planar lymphoscintigraphy for preoperative sentinel lymph node detection in cervical cancer: a systematic review and Metaanalysis. *J Nucl Med*. 2015;56:675–80. doi:10.2967/jnumed.114.152439.
15. Buda A, Elisei F, Arosio M, Dolci C, Signorelli M, Perego P, et al. Integration of hybrid single-photon emission computed tomography/computed tomography in the preoperative assessment of sentinel node in patients with cervical and endometrial cancer: our experience and literature review. *Int J Gynecol Cancer*. 2012;22:830–5. doi:10.1097/IGC.0b013e318253496f.
16. Sawicki S, Kobierski J, Lapinska-Szumczyk S, Lass P, Cytawa W, Bianek-Bodzak A, et al. Comparison of SPECT-CT results and intraoperative detection of sentinel lymph nodes in endometrial cancer. *Nucl Med Commun*. 2013;34:590–6. doi:10.1097/MNM.0b013e328360d8cc.
17. Perissinotti A, Paredes P, Vidal-Sicart S, Torne A, Albela S, Navales I, et al. Use of SPECT/CT for improved sentinel lymph node localization in endometrial cancer. *Gynecol Oncol*. 2013;129:42–8. doi:10.1016/j.ygyno.2013.01.022.
18. Mucke J, Klapdor R, Schneider M, Langer F, Gratz KF, Hillemanns P, et al. Isthmocervical labelling and SPECT/CT for optimized sentinel detection in endometrial cancer: technique, experience and results. *Gynecol Oncol*. 2014;134:287–92. doi:10.1016/j.ygyno.2014.05.001.
19. Niikura H, Kaiho-Sakuma M, Tokunaga H, Toyoshima M, Utsunomiya H, Nagase S, et al. Tracer injection sites and combinations for sentinel lymph node detection in patients with endometrial cancer. *Gynecol Oncol*. 2013;131:299–303. doi:10.1016/j.ygyno.2013.08.018.
20. Sahbai S, Taran FA, Fiz F, Staebler A, Becker S, Solomayer E, et al. Pericervical injection of 99mTc-Nanocolloid is superior to Peritumoral injection for sentinel lymph node detection of endometrial cancer in SPECT/CT. *Clin Nucl Med*. 2016;41:927–32. doi:10.1097/rlu.0000000000001414.
21. Frati A, Ballester M, Dubernard G, Bats AS, Heitz D, Mathevet P, et al. Contribution of lymphoscintigraphy for sentinel lymph node biopsy in women with early stage endometrial cancer: results of the SENTI-ENDO study. *Ann Surg Oncol*. 2015;22:1980–6. doi:10.1245/s10434-014-4203-7.
22. Dittmann H, Becker S, Bares R. Detection of sentinel lymph nodes after hysteroscopic peritumoral injection of Tc-99m-Nanocolloid in grade 1 endometrial carcinoma. *J Nucl Med*. 2010;51:18.
23. Eldweny H, Alkhalid K, Alsaleh N, Abdulsamad M, Abbas A, Hamad A, et al. Predictors of non-sentinel lymph node metastasis in breast cancer patients with positive sentinel lymph node (pilot study). *J Egypt Natl Cancer Inst*. 2012;24:23–30. doi:10.1016/j.jnci.2011.12.004.
24. Coufal O, Zapletal O, Vrtelova P, Vasina J, Rehak Z. Failed preoperative lymphoscintigraphy for sentinel lymph node biopsy in breast cancer, possible causes and implications for the surgery - the analysis of 3014 procedures. *Rozhl Chir*. 2015;94:126–30.
25. Bernardi S, Bertozzi S, Londero AP, Angione V, Petri R, Giacomuzzi F. Prevalence and risk factors of intraoperative identification failure of sentinel lymph nodes in patients affected by breast cancer. *Nucl Med Commun*. 2013;34:664–73. doi:10.1097/MNM.0b013e328361cd84.
26. Klingensmith 3rd WC, Spitzer VM, Fritzberg AR, Kuni CC. Normal appearance and reproducibility of liver-spleen studies with Tc-99m sulfur colloid and Tc-99m microalbumin colloid. *J Nucl Med*. 1983;24:8–13.
27. Dordea M, Colvin H, Cox P, Pujol Nicolas A, Kanakala V, Iwuchukwu O. Clinical and histopathological factors affecting failed sentinel node localization in axillary staging for breast cancer. *Surgeon*. 2013;11:63–6. doi:10.1016/j.surge.2011.10.006.
28. Birdwell RL, Smith KL, Betts BJ, Ikeda DM, Strauss HW, Jeffrey SS. Breast cancer: variables affecting sentinel lymph node visualization at preoperative lymphoscintigraphy. *Radiology*. 2001;220:47–53. doi:10.1148/radiology.220.1.r01jn2347.
29. Wuntakal R, Papadopoulos AJ, Montalto SA, Perovic M, Coutts M, Devaja O. Location of sentinel lymph node in cervical carcinoma and factors associated with unilateral detection. *Int J Gynecol Cancer*. 2015;25:1663–8. doi:10.1097/igc.0000000000000539.
30. Brenot-Rossi I, Rossi D, Estemi B, Brunelle S, Chuto G, Bastide C. Radioguided sentinel lymph node dissection in patients with localised prostate carcinoma: influence of the dose of radiolabelled colloid to avoid failure of the procedure. *Eur J Nucl Med Mol Imaging*. 2008;35:32–8. doi:10.1007/s00259-007-0516-0.
31. Wengenmair H, Kopp J, Vogt H, Wawroschek F, Grober S, Dom R, et al. Sentinel lymph node diagnosis in prostatic carcinoma: II. Biokinetics and dosimetry of 99mTc-Nanocolloid after intraprostatic injection. *Nuklearmedizin*. 2002;41:102–7.
32. Soares MM, Keramida G, Glass DM, Mortimer PS, Peters AM. Lymph proteins may access peripheral blood without entering thoracic duct in patients with lymphatic dysfunction. *J Vasc Surg Venous Lymphat Disord*. 2016;4:215–20. doi:10.1016/j.jvsv.2015.10.010.
33. Stamp GF, Peters AM. Peripheral lymphovenous communication in lymphoedema. *Nucl Med Commun*. 2012;33:701–7. doi:10.1097/MNM.0b013e32835313d4.
34. Kalin B, Axelsson B, Jacobsson H. Quantitative evaluation of four 99mTc colloids for bone marrow scintigraphy using single photon emission computed tomography. *Nucl Med Commun*. 1991;12:135–45.
35. Soran A, Falk J, Bonaventura M, Keenan D, Ahrendt G, Johnson R. Does failure to visualize a sentinel node on preoperative lymphoscintigraphy predict a greater likelihood of axillary lymph node positivity? *J Am Coll Surg*. 2005;66–71. doi:10.1016/j.jamcollsurg.2007.01.064.
36. Sener SF, Winchester DJ, Brinkmann E, Winchesteer DP, Alwawi E, Nickolov A, et al. Failure of sentinel lymph node mapping in patients with breast cancer. *J Am Coll Surg*. 2004;198:732–6. doi:10.1016/j.jamcollsurg.2004.01.006.
37. Rubello D, Zavagno G, Bozza F, Lise M, De Salvo GL, Saladini G, et al. Analysis of technical and clinical variables affecting sentinel node localization in patients with breast cancer after a single intradermal injection of 99mTc nanocolloidal albumin. *Nucl Med Commun*. 2004;25:1119–24.
38. Bats AS, Frati A, Mathevet P, Orliaguet I, Querleu D, Zerdoud S, et al. Contribution of lymphoscintigraphy to intraoperative sentinel lymph node detection in early cervical cancer: analysis of the prospective multicenter SENTICOL cohort. *Gynecol Oncol*. 2015;137:264–9. doi:10.1016/j.ygyno.2015.02.018.

3. Discussion

In our first study, we observed a significantly better SLN detection rate after a pericervical injection versus hysteroscopic-peritumoral injection in patients with endometrial carcinoma who underwent SPECT/CT⁷⁹. This finding is in line with previous studies which found a better detection rate in favor to pericervical injection compared to peritumoral injection^{76,77,80}. However, these studies used only the intra-operative or the planar lymphoscintigraphy. In our study, the pericervical injection method detected SLNs in the iliac and common iliac anatomical areas more frequently than the peritumoral injection method. Additionally, pericervical injection seemed to be superior in our data for the detection of bilateral pelvic SLNs. Finally, we could affirm that the sole potential benefit of the peritumoral injection method was the better detection rate of SLNs in the para-aortic area. This could be explained by a direct physiologic lymphatic drainage of the radiotracer from the uterus body to the para-aortic nodal areas. This concept was previously shown in published studies^{77,80,81}.

Failing tracer depot has been frequently seen in case of detection failure using hysteroscopic peritumoral injection while it remained very uncommon with pericervical injection. This imaging feature seemed to be correlated with the waste of activity outside of the patient by the use of hysteroscopic technique. Generally, detection failure of SLNs seemed to be related to venous drainage represented by visually higher uptake in the spleen, liver and bone marrow in both injection methods. However, our first study was not designed to determine significant factors affecting successful SLN detection.

Actually, missed SLN detection in EC could limit the acceptance of this procedure in the daily clinical routine. Further improvements were thus necessary to identify and possibly eliminate sources of error so to make this technique as reliable and reproducible as possible.

That is why we performed a prospective study in our institution which was designed to compare technical, clinical and tumor factors between detection and no detection of SLNs intra-operatively as well as in SPECT/CT in a larger cohort of patient. This study was focused on the pericervical injection only which was shown to have a better detection rate.

The results of our second study showed that the most important significant factor affecting SLN detection rate was the presence of augmented radiotracer venous drainage shown by visual high bone marrow uptake in the SPECT/CT images⁸². Moreover, missed SLN detection in SPECT/CT was also associated with the presence of high abdominal and peritoneal activity, but this was not significantly associated with intra-operative SLN detection failure⁸². It could be supposed that the presence of masking abdominal activity hid potential hot-spots in the SPECT/CT images while it did not affect the SLN detection by the use of gamma hand probe during surgery. Amazingly, SLN detection failure was seen in some patients without high venous drainage or high peritoneal activity. Thus, insufficient lymphatic drainage should be considered as another possible cause of detection failure. However, this second study evaluated the results only with visual analysis on SPECT/CT images, so that no significant difference for liver/spleen uptake between the two groups was reached. It might be considered that detection failure could be also associated with higher uptake into the liver and the spleen.

In both studies, SLN detection rate - on a patient-base - was not correlated with parameters, such as tumor stage, lymph node involvement, histology type, uptake time and injected radiotracer activity. It should be considered that in general our patient cohort had a low rate of advanced tumor stage and LN metastases. However, some trends were found for the detected SLNs number of each patient in the scintigraphic images. In fact, lower patient age and higher injected activity seemed to be related with superior detected SLNs numbers in SPECT/CT. Moreover, detection rate of additional para-aortic SLNs seemed to be better when higher activity or peritumoral injection of radiotracer was performed.

In conclusion, the long experience of SLN technique acquired in our institution allowed us to answer to clinical relevant issues of SLN biopsy procedure in endometrial cancer. In fact, we were able to confirm that the best injection method to detect SLNs in SPECT/CT imaging is the direct pericervical injection which is at the same time the less invasive and technically the more reproducible. Moreover, we were the first working group who analyzed technical and clinical parameters affecting potentially pre-operative and intra-operative SLN detection of endometrial cancer.

Further longitudinal studies should be performed in order to confirm the clinical benefits of SLN biopsy and to improve the pre-operative staging in endometrial cancer. It is not yet clear whether groups of patients with selective SLN biopsy or complete lymphadenectomy will have a better overall survival or progression free disease. In addition, the accuracy of SLN biopsy to prevent metastatic disease in endometrial cancer has not yet been determined.

4. Summary

Endometrial cancer is the fourth most common cancer in women of Europe and the third in USA. Worldwide its incidence is steadily increasing. Surgery is the reference treatment, usually with a total hysterectomy and bilateral salpingo-oophorectomy. Additional surgical treatments (lymphadenectomy, omentectomy) depend on the clinical stage, histological type and grade. Lymph node status is described as one of the most important prognostic factors affecting overall survival in EC. The clinical benefits of systematic lymphadenectomy in the pelvic and para-aortic regions for overall survival are still controversial. Sentinel lymph node mapping could potentially improve surgical staging while reducing surgical comorbidities of complete lymphadenectomy. The benefits of the routine clinical use of SLN mapping are not yet confirmed in EC. Moreover, the more efficient protocol and SLN mapping procedure in endometrial cancer were not completely determined. Our aim in the first study was to compare the preoperative scintigraphic SLN detection rate using SPECT/CT between two injection techniques of ^{99m}Tc-nanocolloid (direct pericervical injection versus hysteroscopic-peritumoral injection). Our second study was designed to determine significant parameters affecting scintigraphic SLN detection rate with pericervical injection technique in a large cohort of patients. Our results showed that the detection rate after pericervical injection was significantly better than the hysteroscopic-peritumoral injection (83% versus 69%; $p = 0.049$). However, additional para-aortic SLNs were detected more frequently with peritumoral application. Injection area with poor or missing activity on SPECT/CT seemed to be an important factor of detection failure by using hysteroscopic-peritumoral application. In our second study, the determining factors of SLN detection failure were the presence of high bone marrow ($p=0.005$) and peritoneal/abdominal radioactivity ($p=0.02$) on SPECT/CT. Patient age and injected radioactivity seemed to be potential influencing factors for the number of total detected SLNs. Para-aortic SLN detection rate was slightly better when higher activity injection of radiotracer was used. However, no correlation was significantly found for tumor stage and histology type, lymph node metastases and the time of imaging after radiotracer application. Beside the question of the best SLN detection method and the best pre-operative imaging for tumor staging, more studies are needed to evaluate the

benefits of selective SLN biopsy compared to systematic lymphadenectomy in women with endometrial cancer.

5. Zusammenfassung

Das Endometriumkarzinom ist der vierthäufigste Tumorerkrankung bei Frauen in Europa und der dritte in den USA. Weltweit steigt die Inzidenz stetig an. Die wichtigsten Risikofaktoren für die Entwicklung eines Endometriumkarzinoms sind Adipositas, Diabetes und eine stattgehabte Tamoxifen-Therapie wie auch eine längere Östrogen-Stimulation des Uterus. Die Chirurgie ist die Therapie der ersten Wahl, meist mit einer totalen Hysterektomie und bilateraler Salpingo-Ovariektomie. Zusätzliche chirurgische Prozeduren (Lymphadenektomie, Omentektomie) hängen vom Tumorstadium, dem histologischen Typ und der Tumorgradierung ab. Der Lymphknotenstatus wird als einer der entscheidendsten prognostischen Faktoren beschrieben, die das Gesamtüberleben beeinflussen kann. Die klinischen Vorteile einer systematischen pelvinen- und para-aortalen Lymphadenektomie im Hinblick auf das Gesamtüberleben sind jedoch noch umstritten. Sentinel-Lymphknoten-Lokalisierung könnte die chirurgische Tumoreinstufung verbessern und gleichzeitig die operativen Komorbiditäten einer totalen Lymphadenektomie reduzieren. Der Nutzen einer routinemäßigen klinischen Verwendung der SLN-Untersuchung beim Endometriumkarzinom ist bis jetzt jedoch noch nicht bestätigt. Darüber hinaus ist die beste Vorgehensweise für die SLN-Untersuchung beim Endometriumkarzinom noch nicht endgültig bestimmt. Das Ziel unserer ersten Studie war es, die präoperative szintigraphische SLN-Detektionsrate mit SPECT/CT in Abhängigkeit von den verwendeten Injektionstechniken von ^{99m}Tc -Nanocolloid (direkte perizervikale Injektion versus hysteroskopisch peritumorale Injektion) zu vergleichen. Unsere zweite Studie wurde durchgeführt, um signifikante Parameter zu bestimmen, die die szintigraphische SLN-Detektionsrate bei perizervikaler Injektionstechnik in einer größeren Gruppe von Patienten beeinflussen konnten. Unsere Ergebnisse zeigten, dass die Detektionsrate nach perizervikaler Injektion signifikant besser als die hysteroskopisch peritumorale Injektion war (83% gegenüber 69%; $p = 0,049$). Allerdings wurden zusätzliche para-aortale SLNs häufiger mit peritumorale Applikation nachgewiesen. Ein Injektionsareal mit geringer oder fehlender Radioaktivität in SPECT/CT schien bei der hysteroskopisch peritumoralen Applikation ein wichtiger Faktor für ein Detektionsversagens zu sein. In unserer zweiten Studie,

waren hohe Knochenmarkspeicherung ($p = 0,005$) und peritoneale / abdominale Radioaktivität ($p = 0,02$) in SPECT/CT die wichtigsten Faktoren, die mit dem SLN-Detektionsversagen verbunden waren. Das Patientenalter und die injizierte Radioaktivität schienen potenzielle Einflussfaktoren für die Anzahl der insgesamt detektierten SLNs zu sein. Die para-aortale SLN-Detektionsrate war etwas besser, wenn eine höhere Aktivitätsmenge des Radiotracers verwendet wurde. Es wurde keine signifikante Korrelation für Tumorhistologie, Tumorstadium und Lymphknotenmetastasierung sowie der Zeitspanne zwischen Injektion und Bildgebung gefunden. Weitere Studien sind jedoch noch erforderlich, um die klinischen Vorteile der selektiven SLN-Biopsie im Vergleich zur systematischen Lymphadenektomie bei Frauen mit Endometriumkarzinom zu bestimmen.

6. References

1. Achouri A, Huchon C, Bats AS, Bensaid C, Nos C, Lecuru F. Complications of lymphadenectomy for gynecologic cancer. *European journal of surgical oncology : the journal of the European Society of Surgical Oncology and the British Association of Surgical Oncology*. Jan 2013;39(1):81-86.
2. Khoury-Collado F, St Clair C, Abu-Rustum NR. Sentinel Lymph Node Mapping in Endometrial Cancer: An Update. *The oncologist*. Apr 2016;21(4):461-466.
3. Collarino A, Vidal-Sicart S, Perotti G, Valdes Olmos RA. The sentinel node approach in gynaecological malignancies. *Clinical and translational imaging*. 2016;4(5):411-420.
4. Siegel RL, Miller KD, Jemal A. Cancer statistics, 2015. *CA: a cancer journal for clinicians*. Jan-Feb 2015;65(1):5-29.
5. Ferlay J, Steliarova-Foucher E, Lortet-Tieulent J, et al. Cancer incidence and mortality patterns in Europe: estimates for 40 countries in 2012. *European journal of cancer (Oxford, England : 1990)*. Apr 2013;49(6):1374-1403.
6. Ferlay J, Soerjomataram I, Dikshit R, et al. Cancer incidence and mortality worldwide: sources, methods and major patterns in GLOBOCAN 2012. *International journal of cancer. Journal international du cancer*. Mar 1 2015;136(5):E359-386.
7. Wolf U, Barnes B, Bertz J, et al. The (German) Center for Cancer Registry Data (ZfKD) at the Robert Koch Institute (RKI) in Berlin. *Bundesgesundheitsblatt - Gesundheitsforschung - Gesundheitsschutz*. 2011;54(11):1229.
8. Bokhman JV. Two pathogenetic types of endometrial carcinoma. *Gynecologic oncology*. Feb 1983;15(1):10-17.
9. JR L. *Berek & Novak's gynecology, 14th Edition*. Lippincott Williams & Wilkins; 2007.
10. MacMahon B. Risk factors for endometrial cancer. *Gynecologic oncology*. Aug 1974;2(2-3):122-129.
11. Parazzini F, La Vecchia C, Bocciolone L, Franceschi S. The epidemiology of endometrial cancer. *Gynecologic oncology*. Apr 1991;41(1):1-16.
12. Parazzini F, La Vecchia C, Negri E, Fedele L, Balotta F. Reproductive factors and risk of endometrial cancer. *American journal of obstetrics and gynecology*. Feb 1991;164(2):522-527.
13. Brinton LA, Berman ML, Mortel R, et al. Reproductive, menstrual, and medical risk factors for endometrial cancer: results from a case-control study. *American journal of obstetrics and gynecology*. Nov 1992;167(5):1317-1325.
14. Grady D, Gebretsadik T, Kerlikowske K, Ernster V, Petitti D. Hormone replacement therapy and endometrial cancer risk: a meta-analysis. *Obstetrics and gynecology*. Feb 1995;85(2):304-313.
15. Fisher B, Costantino JP, Redmond CK, Fisher ER, Wickerham DL, Cronin WM. Endometrial cancer in tamoxifen-treated breast cancer patients: findings from the National Surgical Adjuvant Breast and Bowel Project (NSABP) B-14. *Journal of the National Cancer Institute*. Apr 6 1994;86(7):527-537.
16. Assikis VJ, Jordan VC. Gynecologic effects of tamoxifen and the association with endometrial carcinoma. *International journal of gynaecology and*

- obstetrics: the official organ of the International Federation of Gynaecology and Obstetrics*. Jun 1995;49(3):241-257.
17. Aarnio M, Sankila R, Pukkala E, et al. Cancer risk in mutation carriers of DNA-mismatch-repair genes. *International journal of cancer. Journal international du cancer*. Apr 12 1999;81(2):214-218.
 18. Chambers JT, Chambers SK. Endometrial sampling: When? Where? Why? With what? *Clinical obstetrics and gynecology*. Mar 1992;35(1):28-39.
 19. Zucker PK, Kasdon EJ, Feldstein ML. The validity of Pap smear parameters as predictors of endometrial pathology in menopausal women. *Cancer*. Nov 1 1985;56(9):2256-2263.
 20. Pecorelli S. Revised FIGO staging for carcinoma of the vulva, cervix, and endometrium. *International journal of gynaecology and obstetrics: the official organ of the International Federation of Gynaecology and Obstetrics*. May 2009;105(2):103-104.
 21. Gordon MD, Ireland K. Pathology of hyperplasia and carcinoma of the endometrium. *Seminars in oncology*. Feb 1994;21(1):64-70.
 22. Carol L. Kosary RL, Young JL, Keel GE, Eisner MP, Lin YD, Horner M-J. SEER Survival Monograph: Cancer Survival Among Adults: U.S. SEER Program, 1988-2001, Patient and Tumor Characteristics. *Cancer of the Corpus Uteri*. National Cancer Institute, SEER Program, NIH Pub. No. 07-6215, Bethesda, MD, 2007.2007.
 23. Oncology FCoG. FIGO staging for carcinoma of the vulva, cervix, and corpus uteri. *International journal of gynaecology and obstetrics: the official organ of the International Federation of Gynaecology and Obstetrics*. May 2014;125(2):97-98.
 24. Ross JC, Eifel PJ, Cox RS, Kempson RL, Hendrickson MR. Primary mucinous adenocarcinoma of the endometrium. A clinicopathologic and histochemical study. *The American journal of surgical pathology*. Dec 1983;7(8):715-729.
 25. Melhem MF, Tobon H. Mucinous adenocarcinoma of the endometrium: a clinico-pathological review of 18 cases. *International journal of gynecological pathology : official journal of the International Society of Gynecological Pathologists*. 1987;6(4):347-355.
 26. Hendrickson M, Ross J, Eifel P, Martinez A, Kempson R. Uterine papillary serous carcinoma: a highly malignant form of endometrial adenocarcinoma. *The American journal of surgical pathology*. Mar 1982;6(2):93-108.
 27. Silva EG, Jenkins R. Serous carcinoma in endometrial polyps. *Modern pathology : an official journal of the United States and Canadian Academy of Pathology, Inc*. Mar 1990;3(2):120-128.
 28. Goff BA, Kato D, Schmidt RA, et al. Uterine papillary serous carcinoma: patterns of metastatic spread. *Gynecologic oncology*. Sep 1994;54(3):264-268.
 29. Abeler VM, Vergote IB, Kjorstad KE, Trope CG. Clear cell carcinoma of the endometrium. Prognosis and metastatic pattern. *Cancer*. Oct 15 1996;78(8):1740-1747.
 30. Abeler VM, Kjorstad KE. Clear cell carcinoma of the endometrium: a histopathological and clinical study of 97 cases. *Gynecologic oncology*. Mar 1991;40(3):207-217.

31. Christopherson WM, Alberhasky RC, Connelly PJ. Carcinoma of the endometrium: I. A clinicopathologic study of clear-cell carcinoma and secretory carcinoma. *Cancer*. Apr 15 1982;49(8):1511-1523.
32. Abeler V, Kjorstad KE. Endometrial squamous cell carcinoma: report of three cases and review of the literature. *Gynecologic oncology*. Mar 1990;36(3):321-326.
33. ACOG practice bulletin, clinical management guidelines for obstetrician-gynecologists, number 65, August 2005: management of endometrial cancer. *Obstetrics and gynecology*. Aug 2005;106(2):413-425.
34. Gordon AN, Fleischer AC, Dudley BS, et al. Preoperative assessment of myometrial invasion of endometrial adenocarcinoma by sonography (US) and magnetic resonance imaging (MRI). *Gynecologic oncology*. Aug 1989;34(2):175-179.
35. Niloff JM, Klug TL, Schaetzl E, Zurawski VR, Jr., Knapp RC, Bast RC, Jr. Elevation of serum CA125 in carcinomas of the fallopian tube, endometrium, and endocervix. *American journal of obstetrics and gynecology*. Apr 15 1984;148(8):1057-1058.
36. Boronow RC, Morrow CP, Creasman WT, et al. Surgical staging in endometrial cancer: clinical-pathologic findings of a prospective study. *Obstetrics and gynecology*. Jun 1984;63(6):825-832.
37. Creasman WT, Morrow CP, Bundy BN, Homesley HD, Graham JE, Heller PB. Surgical pathologic spread patterns of endometrial cancer. A Gynecologic Oncology Group Study. *Cancer*. Oct 15 1987;60(8 Suppl):2035-2041.
38. Cowles TA, Magrina JF, Masterson BJ, Capen CV. Comparison of clinical and surgical-staging in patients with endometrial carcinoma. *Obstetrics and gynecology*. Sep 1985;66(3):413-416.
39. Kaku T, Tsuruchi N, Tsukamoto N, Hirakawa T, Kamura T, Nakano H. Reassessment of myometrial invasion in endometrial carcinoma. *Obstetrics and gynecology*. Dec 1994;84(6):979-982.
40. Hanson MB, van Nagell JR, Jr., Powell DE, et al. The prognostic significance of lymph-vascular space invasion in stage I endometrial cancer. *Cancer*. Apr 15 1985;55(8):1753-1757.
41. Abeler VM, Kjorstad KE, Berle E. Carcinoma of the endometrium in Norway: a histopathological and prognostic survey of a total population. *International journal of gynecological cancer : official journal of the International Gynecological Cancer Society*. Jan 1992;2(1):9-22.
42. Lurain JR, Rice BL, Rademaker AW, Poggensee LE, Schink JC, Miller DS. Prognostic factors associated with recurrence in clinical stage I adenocarcinoma of the endometrium. *Obstetrics and gynecology*. Jul 1991;78(1):63-69.
43. Moore DH, Fowler WC, Jr., Walton LA, Droegemueller W. Morbidity of lymph node sampling in cancers of the uterine corpus and cervix. *Obstetrics and gynecology*. Aug 1989;74(2):180-184.
44. Schink JC, Lurain JR, Wallemark CB, Chmiel JS. Tumor size in endometrial cancer: a prognostic factor for lymph node metastasis. *Obstetrics and gynecology*. Aug 1987;70(2):216-219.
45. Colombo N, Creutzberg C, Amant F, et al. ESMO-ESGO-ESTRO Consensus Conference on Endometrial Cancer: Diagnosis, Treatment and Follow-up.

- International journal of gynecological cancer : official journal of the International Gynecological Cancer Society.* Jan 2016;26(1):2-30.
46. Childers JM, Brzechffa PR, Hatch KD, Surwit EA. Laparoscopically assisted surgical staging (LASS) of endometrial cancer. *Gynecologic oncology.* Oct 1993;51(1):33-38.
 47. Gemignani ML, Curtin JP, Zelmanovich J, Patel DA, Venkatraman E, Barakat RR. Laparoscopic-assisted vaginal hysterectomy for endometrial cancer: clinical outcomes and hospital charges. *Gynecologic oncology.* Apr 1999;73(1):5-11.
 48. Malur S, Possover M, Michels W, Schneider A. Laparoscopic-assisted vaginal versus abdominal surgery in patients with endometrial cancer--a prospective randomized trial. *Gynecologic oncology.* Feb 2001;80(2):239-244.
 49. Marziale P, Atlante G, Pozzi M, Diotallevi F, Iacovelli A. 426 cases of stage I endometrial carcinoma: a clinicopathological analysis. *Gynecologic oncology.* Mar 1989;32(3):278-281.
 50. Taghian A, Pernot M, Hoffstetter S, Luporsi E, Bey P. Radiation therapy alone for medically inoperable patients with adenocarcinoma of the endometrium. *International journal of radiation oncology, biology, physics.* Nov 1988;15(5):1135-1140.
 51. Lehoczky O, Bosze P, Ungar L, Tottossy B. Stage I endometrial carcinoma: treatment of nonoperable patients with intracavitary radiation therapy alone. *Gynecologic oncology.* Dec 1991;43(3):211-216.
 52. Kupelian PA, Eifel PJ, Tornos C, Burke TW, Delclos L, Oswald MJ. Treatment of endometrial carcinoma with radiation therapy alone. *International journal of radiation oncology, biology, physics.* Nov 15 1993;27(4):817-824.
 53. Morrow CP, Bundy BN, Kurman RJ, et al. Relationship between surgical-pathological risk factors and outcome in clinical stage I and II carcinoma of the endometrium: a Gynecologic Oncology Group study. *Gynecologic oncology.* Jan 1991;40(1):55-65.
 54. Orr JW, Jr., Holimon JL, Orr PF. Stage I corpus cancer: is teletherapy necessary? *American journal of obstetrics and gynecology.* Apr 1997;176(4):777-788; discussion 788-779.
 55. Straughn JM, Jr., Huh WK, Kelly FJ, et al. Conservative management of stage I endometrial carcinoma after surgical staging. *Gynecologic oncology.* Feb 2002;84(2):194-200.
 56. Neubauer NL, Lurain JR. The role of lymphadenectomy in surgical staging of endometrial cancer. *International journal of surgical oncology.* 2011;2011:814649.
 57. Milam MR, Java J, Walker JL, et al. Nodal metastasis risk in endometrioid endometrial cancer. *Obstetrics and gynecology.* Feb 2012;119(2 Pt 1):286-292.
 58. Koh WJ, Greer BE, Abu-Rustum NR, et al. Uterine neoplasms, version 1.2014. *Journal of the National Comprehensive Cancer Network : JNCCN.* Feb 2014;12(2):248-280.
 59. Colombo N, Preti E, Landoni F, et al. Endometrial cancer: ESMO Clinical Practice Guidelines for diagnosis, treatment and follow-up. *Annals of oncology : official journal of the European Society for Medical Oncology.* Oct 2013;24 Suppl 6:vi33-38.
 60. Bats AS, Frati A, Mathevet P, et al. Contribution of lymphoscintigraphy to intraoperative sentinel lymph node detection in early cervical cancer: Analysis

- of the prospective multicenter SENTICOL cohort. *Gynecologic oncology*. May 2015;137(2):264-269.
61. Niikura H, Okamura C, Akahira J, et al. Sentinel lymph node detection in early cervical cancer with combination 99mTc phytate and patent blue. *Gynecologic oncology*. Aug 2004;94(2):528-532.
 62. Wang XJ, Fang F, Li YF. Sentinel-lymph-node procedures in early stage cervical cancer: a systematic review and meta-analysis. *Medical oncology (Northwood, London, England)*. Jan 2015;32(1):385.
 63. Bats AS, Buenerd A, Querleu D, et al. Diagnostic value of intraoperative examination of sentinel lymph node in early cervical cancer: a prospective, multicenter study. *Gynecologic oncology*. Nov 2011;123(2):230-235.
 64. Wuntakal R, Papadopoulos AJ, Montalto SA, Perovic M, Coutts M, Devaja O. Location of Sentinel Lymph Node in Cervical Carcinoma and Factors Associated With Unilateral Detection. *International journal of gynecological cancer : official journal of the International Gynecological Cancer Society*. Nov 2015;25(9):1663-1668.
 65. Giammarile F, Bozkurt MF, Cibula D, et al. The EANM clinical and technical guidelines for lymphoscintigraphy and sentinel node localization in gynaecological cancers. *European journal of nuclear medicine and molecular imaging*. Jul 2014;41(7):1463-1477.
 66. Bidus MA, O'Boyle JD, Elkas JC. Sentinel Lymph Node Detection in Gynecologic Malignancies. *Postgraduate Obstetrics & Gynecology*. 2004;24(26):1-5.
 67. Frati A, Ballester M, Dubernard G, et al. Contribution of Lymphoscintigraphy for Sentinel Lymph Node Biopsy in Women with Early Stage Endometrial Cancer: Results of the SENTI-ENDO Study. *Annals of surgical oncology*. Jun 2015;22(6):1980-1986.
 68. Niikura H, Okamura C, Utsunomiya H, et al. Sentinel lymph node detection in patients with endometrial cancer. *Gynecologic oncology*. Feb 2004;92(2):669-674.
 69. Ballester M, Dubernard G, Lecuru F, et al. Detection rate and diagnostic accuracy of sentinel-node biopsy in early stage endometrial cancer: a prospective multicentre study (SENTI-ENDO). *The Lancet. Oncology*. May 2011;12(5):469-476.
 70. How J, Lau S, Press J, et al. Accuracy of sentinel lymph node detection following intra-operative cervical injection for endometrial cancer: a prospective study. *Gynecologic oncology*. Nov 2012;127(2):332-337.
 71. Kang S, Yoo HJ, Hwang JH, Lim MC, Seo SS, Park SY. Sentinel lymph node biopsy in endometrial cancer: meta-analysis of 26 studies. *Gynecologic oncology*. Dec 2011;123(3):522-527.
 72. Smith AJ, Fader AN, Tanner EJ. Sentinel Lymph Node Assessment in Endometrial Cancer: A Systematic Review and Meta-analysis. *American journal of obstetrics and gynecology*. Nov 18 2016.
 73. Darai E, Dubernard G, Bats AS, et al. Sentinel node biopsy for the management of early stage endometrial cancer: long-term results of the SENTI-ENDO study. *Gynecologic oncology*. Jan 2015;136(1):54-59.

74. Mucke J, Klapdor R, Schneider M, et al. Isthmocervical labelling and SPECT/CT for optimized sentinel detection in endometrial cancer: technique, experience and results. *Gynecologic oncology*. Aug 2014;134(2):287-292.
75. Perissinotti A, Paredes P, Vidal-Sicart S, et al. Use of SPECT/CT for improved sentinel lymph node localization in endometrial cancer. *Gynecologic oncology*. Apr 2013;129(1):42-48.
76. Robova H, Charvat M, Strnad P, et al. Lymphatic mapping in endometrial cancer: comparison of hysteroscopic and subserosal injection and the distribution of sentinel lymph nodes. *International journal of gynecological cancer : official journal of the International Gynecological Cancer Society*. Apr 2009;19(3):391-394.
77. Niikura H, Kaiho-Sakuma M, Tokunaga H, et al. Tracer injection sites and combinations for sentinel lymph node detection in patients with endometrial cancer. *Gynecologic oncology*. Nov 2013;131(2):299-303.
78. Torne A, Pahisa J, Vidal-Sicart S, et al. Transvaginal ultrasound-guided myometrial injection of radiotracer (TUMIR): a new method for sentinel lymph node detection in endometrial cancer. *Gynecologic oncology*. Jan 2013;128(1):88-94.
79. Sahbai S, Taran FA, Fiz F, et al. Pericervical Injection of ^{99m}Tc-Nanocolloid Is Superior to Peritumoral Injection for Sentinel Lymph Node Detection of Endometrial Cancer in SPECT/CT. *Clinical nuclear medicine*. Dec 2016;41(12):927-932.
80. Perrone AM, Casadio P, Formelli G, et al. Cervical and hysteroscopic injection for identification of sentinel lymph node in endometrial cancer. *Gynecologic oncology*. Oct 2008;111(1):62-67.
81. Lecuru F, Neji K, Robin F, Darles C, de Bievre P, Taurelle R. [Lymphatic drainage of the uterus. Preliminary results of an experimental study]. *Journal de gynecologie, obstetrique et biologie de la reproduction*. 1997;26(4):418-423.
82. Sahbai S, Taran FA, Staebler A, et al. Sentinel lymph node mapping using SPECT/CT and gamma probe in endometrial cancer: an analysis of parameters affecting detection rate. *European journal of nuclear medicine and molecular imaging*. Apr 03 2017.

Die Arbeit wurde in der Klinik für Nuklearmedizin Universitätsklinikum Tübingen unter Betreuung von Prof. Dr. Christian la Fougère durchgeführt.

Die Konzeption der Studie erfolgte in Zusammenarbeit mit Dr. Helmut Dittmann, Oberarzt in der Klinik für Nuklearmedizin Universitätsklinikum Tübingen.

Die statistische Auswertung erfolgte eigenständig und nach Beratung durch das Institut für Biometrie in der Universitätsklinikum Tübingen (Prof. Peter Martus) durch mich.

Die Bilder der Histologie wurden mit freundlicher Genehmigung von Dr. Annette Staebler (Klinik für Pathologie Universitätsklinikum Tübingen) eingereicht.

Ich versichere, das Manuskript selbständig nach Anleitung durch Dr. Helmut Dittmann und Prof. Christian la Fougère verfasst zu haben und keine weiteren als die von mir angegebenen Quellen verwendet zu haben.

Tübingen, den 19.10.2017

Doktorand Samine Sahbai

7. Liste der Veröffentlichungen

Sahbai S, Taran FA, Fiz F, Staebler A, Becker S, Solomayer E, Wallwiener D, la Fougère C, Brucker S, Dittmann H.

Pericervical injection of Tc99m-Nanocolloid is superior to peritumoral injection for sentinel lymph node detection of endometrial cancer in SPECT/CT

Clinical Nuclear Medicine - 2016- 41(12):927-932

Sahbai S, Taran FA, Staebler A, Wallwiener D, la Fougère C, Brucker S, Dittmann H.

Sentinel lymph node mapping using SPECT/CT and gamma probe in endometrial cancer: an analysis of parameters affecting detection rate

European Journal of Nuclear Medicine and Molecular Imaging - 2017 - 44(9):1511-1519