Diagnostic and prognostic implications of myocardial Gremlin-1 expression in patients with structural myocardial disease

Inaugural-Dissertation
zur Erlangung des Doktorgrades der Medizin

der Medizinischen Fakultät
der Eberhard Karls Universität
zu Tübingen

vorgelegt von

Tavlaki, Elli

2016

Dekan:	**Professor Dr. I. Autenrieth**
1. Berichterstatter:	**Professor Dr. T. Geisler**
2. Berichterstatter:	**Professor Dr. A. Nieß**

Table of Contents

Page

1. Introduction 6

1.1 Structural myocardial diseases – a challenge in classification, diagnosis and therapy 6

1.1.1 Definition of cardiomyopathies according to ESC classification 7

1.1.1.1 Dilated cardiomyopathy (DCM) 8

1.1.1.2 Hypertrophic cardiomyopathy (HCM) 9

1.1.1.3 Arrhythmogenic right ventricular cardiomyopathy (ARVC) 10

1.1.1.4 Restrictive cardiomyopathy (RCM) 11

1.1.1.5 Unclassified cardiomyopathies 11

1.2 Prognostic impact of myocardial inflammation and fibrosis in structural myocardial disease 12

1.2.1 Proinflammatory cytokines 12

1.2.2 Matrix metalloproteinases (MMPs) 13

1.2.3 Oxidative stress 13

1.3 Impact of molecular and immunohistochemical biomarkers in structural myocardial diseases for risk stratification 14

1.3.1 Impact of Cyclophilin A and Extracellular Matrix Metalloproteinase Inducer (EMMPRIN) as risk markers in structural myocardial diseases 14

1.3.2 Inflammatory markers in standard histopathology and immunohistochemistry: Major Histocompatibility Complex Class II , CD 3 and CD 68 15

1.4 Impact of Gremlin-1 in the adult organism and in fibrosis 16

1.4.1 Interaction of Gremlin-1, bone morphogenetic proteins and transforming growth factor beta: Characterization of the signaling pathways 17
1.4.2 Gremlin-1 and fibrosis 19
1.4.2.1 Gremlin-1 and kidney fibrosis 19
1.4.2.2 Gremlin-1 and idiopathic pulmonary fibrosis 20
1.4.2.3 Gremlin-1 and liver fibrosis 21
1.5 Hypothesis 22
2. Materials and methods 23
2.1 Materials 23
2.1.1 Antibodies 23
2.1.2 Kits 23
2.1.3 Software 24
2.1.4 Chemicals and reagents 24
2.1.5 Clinical and lab equipment 27
2.2 Study design and assessment of risk factors 27
2.3 Study endpoints and follow up 28
2.4 Endomyocardial biopsy 29
2.5 Histology and immunohistochemistry 29
2.5.1 Histology 29
2.5.2 Immunohistochemistry 31
2.6 Histopathological analysis 32
2.7 Molecular detection of viral genomes by nested PCR 33
2.7.1 RNA preparation and Real-Time-quantitative PCR (qRT-PCR) analysis 34
2.8 Sodiumdodecylsulfate polyacrylamide gel electro-phoresis (SDS-PAGE) and Western Blotting 35
2.8.1 SDS-PAGE 35
2.8.1.1 SDS-PAGE protocol 36
2.8.2 Western Blot (WB) 36
2.8.2.1 Western Blot protocol 37
2.9 Statistical analysis 37

3. Results 39
3.1 Patient population and risk factors 39
3.2 Myocardial expression of Gremlin-1 and correlation between Gremlin-1 expression and the degree of myocardial fibrosis 44
3.3 Association of endomyocardial expression of Gremlin-1 with left ventricular dysfunction 47
3.4 Association of Gremlin-1 expression with poor clinical outcome/ Gremlin-1 as independent predictor of adverse cardiac events 48
4. Discussion 51
5. Summary 56
6. Zusammenfassung 57
7. Contributions 59
8. Index of abbreviations 61
9. Index of tables 63
10. Index of figures 63
11. Index of references 64
12. Acknowledgement 70

1. Introduction

1.1 Structural myocardial diseases – a challenge in classification, diagnosis and therapy

Structural myocardial diseases represent a large and heterogenous group of cardiac diseases with various clinical phenotypes including arrhythmic events, heart failure and even sudden cardiac death.

The underlying cardiomyopathies (CM) are a complex group of heart muscle diseases with multiple etiologies making the classification of CM especially difficult.

According to the classification by the American Heart Association (AHA 2006) CM are divided in two main categories: primary and secondary CM. Primary CM can be genetic, mixed or acquired, whereas secondary CM constitute to be a part of a systemic disorder [1]. In primary CM the heart is the predominantly involved organ whereas in secondary CM the myocardial dysfunction is caused by the underlying disease.

There is a different classification suggested by the European Society of Cardiology (ESC 2008) according to which CM "are grouped into specific morphological and functional phenotypes; each phenotype is then sub-classified into familial and non-familial forms". Exact definitions of CM are given below.

Progression of cardiomyopathies can be irreversible leading to congestive heart failure. The affection of the myocardium, especially the degree of cardiac inflammation, fibrosis and subsequent dysfunction of the myocardium and impairment of the left ventricular function is a limiting factor of the patients' prognosis in primary and secondary CM.

Since heart failure is the third most common cause of death in Germany after chronic ischemic heart disease and acute myocardial infarction (Statistisches Bundesamt 2010), it is of great importance to diagnose and treat CM at an early stage of the disease. In the United States it is estimated that 5-10% of patients with congestive heart failure are diagnosed with some type of CM [2].

The diagnosis of CM involves established examination methods like echocardiography, cardiac magnetic resonance imaging, heart catheterization, endomyocardial biopsy, and electrophysiological risk stratification. The etiology remains unknown in 50% of patients [3].

Patients with CM need either a long term pharmacological treatment or implantable device therapy (cardiac resynchronization therapy (CRT), cardioverter-defibrillators (ICDs) and/or ventricular assist device), and in cases of end stage disease heart transplantation. Despite these therapeutic options the prognosis remains poor so far [3, 4].

The individual risk assessment is crucial for the clinical decision process. There are clinical factors associated with an adverse clinical outcome like New York Heart Association (NYHA) class ≥ III [5-8], low ventricular ejection fraction (LVEF) [9-12] or elevated B-type natriuretic peptide (BNP) [13].

However, there are no established histological criteria or markers to classify the severity of CM or to assess the short-term and long-term prognosis. Such markers would give us the opportunity to predict the outcome of the disease and thus providing individual and causal treatment approaches at an early stage of the disease.

1.1.1 Definition of cardiomyopathies according to ESC classification

According to ESC classification CM is a myocardial disorder in which the heart muscle is structurally and functionally abnormal, in the absence of coronary artery disease, hypertension, valvular disease and congenital heart disease [14]. They are classified according to functional and morphological criteria as dilated, hypertrophic, arrhythmogenic right ventricular, restrictive and unclassified CM. According to etiology CM can be genetic or nongenetic, with nongenetic being divided into acquired or idiopathic.

1.1.1.1 Dilated cardiomyopathy (DCM)

DCM is the most common CM worldwide defined by the presence of left ventricular dilation and left ventricular systolic dysfunction [15]. The right ventricle can be dilated and the right ventricular function is often impaired. DCM can be genetic, idiopathic or acquired. The prevalence of idiopathic DCM is estimated as 1:2500 and is a CM of unknown cause. It appears in men twice as often in comparison to women and most often in middle age. The acquired DCM can be caused by myocarditis and toxical factors (toxins, alcohol, drug abuse and anthracycline). Systemic infections (viral, bacterial, fungal, parasitic) and especially viral infections (B19 parvovirus, adenovirus, coxsackievirus B) can lead to myocardial infection after an interval of some days. This leads to a myocardial inflammation and myocardial dysfunction. Acquired DCM is also caused by systemic underlying diseases. Patients with autoimmune systemic (lupus erythematosus, polymyositis, sklerodermie, rheumatoid arthritis, Churg Strauss syndrome, sarkoidosis, amyloidosis), neuromuscular (myotonic dystrophy, Morbus Friedrich), metabolic (Morbus Gaucher, haemochromatosis) or endocrine disorders (hyper/hypo-thyreosis, diabetes mellitus) are often diagnosed with DCM. Genetic DCM is found in 35% of patients. The disease is predominantly inherited in an autosomal dominant pattern**.** Sarcomeric protein, Z-band, cytoskeletal genes and nuclear membrane mutations are reported in the disease [1]. In the myocardium of patients with DCM the structure of fibers becomes anomalous and areas with interstitial and perivascular fibrosis are detected. Parts of the myocardium can be necrotic, showing cellular infiltration [15]. This process leads to cardiac remodeling of one or both ventricles. Patients with DCM gradually develop heart failure, ventricular and supraventricular arrhythmias and depending on the risk for sudden cardiac death (SCD) they often need an ICD implantation [1].

1.1.1.2 Hypertrophic cardiomyopathy (HCM)

HCM is a genetic CM based on sarcomere disorder. It is characterized by a hypertrophied but in the start non-dilated left ventricle (LV). The LV wall thickness is increased (>13mm). That makes the LV stiff and leads to diastolic filling disorder and elevated end-diastolic pressure. Gradually, the LV dilates and patients develop systolic dysfunction. The majority of the patients have an asymmetrical pattern of hypertrophy, which is mainly detected in the anterior septum [16]. HCM is classified in hypertrophic obstructive CM (HOCM) and hypertrophic non-obstructive CM (HNCM) depending on the presence of LV outflow tract obstruction. Late gadolinium enhancement (LGE) detected by cardiac magnetic resonance (CMR) is present in 60% of patients with HCM and LV hypertrophy which is why CMR is used for risk stratification in HCM [17]. The disease is caused by a gene mutation of sarcomeric proteins which is inherited in an autosomal dominant pattern. The prevalence in the general population is about 1:500. Histological analysis reveals hypertrophied cardiomyocytes which are distributed in the LV in a disorganized way and alter the normal LV architecture. The increased formation of intimal and medial collagen in the wall of coronary vessels leads to a small vessel disease and myocardial ischemia. The abnormal structure of the myocardium tissue after the cardiomyocyte death and the formation of myocardial scarring finally contributes to life-threatening arrhythmias like ventricular tachycardia (VT), ventricular fibrillation (VF) and consequently to SCD [1]. The annual incidence of SCD is approximately 1%. Prior cardiac arrest (due to VF, VT), spontaneous sustained VT and syncope of undetermined origin with clinically relevant, haemodynamically significant sustained VT or VF induced at electrophysiological study are major risk factors for SCD and according to American College of Cardiology (ACC) / AHA guidelines they are a *class I indication* for ICD implantation [18]. Moreover, other risk factors like family history of SCD, unexplained syncope, non-sustained VT (nsVT), abnormal blood pressure during exercise and extreme left ventricular hypertrophy (maximum dimension ≥ 3cm) highly increase the risk for

SCD, which is why patients with one or more of these factors have a *class IIa indication* for ICD implantation [19].

1.1.1.3 Arrhythmogenic right ventricular cardiomyopathy (ARVC)

ARVC is an uncommon CM characterized by the presence of right ventricular systolic/diastolic dysfunction and global or regional abnormal structure of the right ventricle (RV) (RV dilatation and RV aneurysms). In patients with ARVC the cardiomyocytes are progressively replaced by fatty and fibrous tissue. In two thirds of the patients there is also a fibrous replacement of the myocardium of the LV and LV enlargement. Other important morphological patterns of ARVC are focal thinning of ventricular free wall, wall hypertrophy, focal bulging of the RV wall in diastole and right ventricular outflow tract (RVOT) enlargement. CMR is a valuable tool for evaluation of cardiac structure and function in ARVC [20]. A definitive diagnosis however is based on histological demonstration of transmural fibrous and/or fibrofatty replacement of RV myocardium at biopsy. The prevalence is estimated between 1:2000 and 1:5000 and it is more commonly seen in males. It is associated with SCD in young people and athletes [21]. ARVC is predominantly autosomal dominant inherited. Mutations in genes encoding for desmoplakin, plakophilin-2, plakoglobin, desmoglein-2, ryanodine receptor RyR2 and transforming growth factor beta (TGF-ß) are recognized in the disease. The abnormal structure of the RV can lead to fatal VTs. The induction of fast unstable VT/VF at electrophysiological study has been shown as independent predictor of life-threatening events [22]. These data may be valuable for identifying individuals at risk in an early stage. Anti-arrhythmic drug-therapy, catheter ablation and ICD implantation are therapeutic options.

1.1.1.4 Restrictive cardiomyopathy (RCM)

RCM is a rare CM characterized by diastolic dysfunction due to increased stiffness of the left ventricular wall. End diastolic pressure is increased in both ventricles with only a small elevation of the volume. The LV wall thickness and the atrioventricular valves remain normal whereas the atria are significantly dilated. The ventricular filling is defective but the systolic function is preserved. A wide spectrum of systematic disease like amyloidosis, sarcoidosis, haemochromatosis, carcinoid heart disease, scleroderma and anthracycline toxicity can lead to acquired RCM**.** Loeffler endocarditis is a specific form of restrictive CM and usually a late manifestation of hypereosinophilic syndrome. Patients with end-stage HCM, DCM and endocardial fibrosis and fibroelastosis are also very often diagnosed with RCM. The familial type of the disease is autosomal dominant inherited with gene mutation of troponin I and desmin. RCM is believed to have the lowest prevalence in the population of all types of CM [14].

1.1.1.5 Unclassified cardiomyopathies

This category encompasses CMs which do not have the typical characteristics of one of the other 4 groups**.** Left ventricular non compaction CM (NCCM) is a rare congenital CM (1:2000 echocardiographic studies) which is believed to be caused by arrest of normal embryogenesis of the endocardium and myocardium. LV appears to be spongy and “non-compacted” and consists of a meshwork of numerous muscle bands called trabeculations with deep intertrabecular recesses. NCCM can be familial (40%) and may occur sporadically. Clinical manifestations vary from no symptoms to congestive heart failure, arrhythmias, and embolic events [23]. Takotsubo CM is a non-ischaemic CM which is triggered by endogenous or iatrogenic catecholamine excess . It is also called stress-induced CM or transient apical ballooning syndrome. It is characterized by transient and severe left ventricular apical ballooning and basal hyperkinesia. Clinical manifestation is the sudden onset of congestive

heart failure. In the acute phase of this CM the patients have symptoms similar to an acute coronary syndrome (dyspnea, chest pain) and the ECG changes are suggestive of an anterior wall myocardial infarction. About 70 - 80% of the cases occur in post-menopausal women. LV function usually recovers within 2 months [24].

1.2 Prognostic impact of myocardial inflammation and fibrosis in structural myocardial diseases

The prognosis of structural myocardial disease has been linked to the degree of inflammation and the amount of fibrosis within the myocardium. Inflammatory mechanisms in structural myocardial diseases comprise the recruitment of inflammatory cells to myocardial sites of injury and dysfunction. Specific humoral and cellular factors like proinflammatory cytokines, matrix metallo-proteinases (MMPs) and reactive oxygen species play a distinct role in the process of cardiac remodeling and lead to myocardial fibrosis [25].

1.2.1 Proinflammatory cytokines

Interleukin 1 (IL)-1β, interleukin 6 (IL)-6 and tumor necrosis factor (TNF)-α are cytokines that play an important role in the inflammatory processes that are involved in cardiac remodeling due to an underlying structural myocardial disease. In congestive heart failure cytokines are produced from the myocardium because of haemodynamic overload. It is also believed that there is an extramyocardial peripheral production due to hypoxia and tissue hypoperfusion [25]. The increased expression of cytokines leads to monocyte phenotype transition and necrosis of cardiomyocytes. They further activate MMPs, a proteolytic enzyme family which degrades the cardiac extracellular matrix (ECM) and leads to the modification of the interstitial matrix. Consequently proinflammatory cytokines lead to adverse LV remodeling and fibrosis process [26].

1.2.2 Matrix metalloproteinases (MMPs)

MMPs are zinc-dependent proteases which belong to the metzincin superfamily. They degrade ECM and play an important role in normal tissue remodeling. At the same time uncontrolled increase in MMP activity leads to excessive ECM degradation and pathological tissue remodeling. By the digestion of ECM matrikines are released [27]. They are peptides that contribute to chemotaxis in many cell types and induce the production of cytokines and growth factors. Consequently they play a role in new connective tissue formation. Furthermore, MMPs release platelet derived growth factor (PDGF), active transforming growth factor beta1 (TGFß1) and insulin-like growth factor (IGF) through the digestion of the ECM. They are active factors associated with ECM that control the cell activity (proliferation, differentiation) and play a role in formation and remodeling of ECM [28]. With this mechanism MMPs lead to the progression of fibrotic processes of the myocardium.

1.2.3 Oxidative stress

Chronically elevated oxidative stress in myocardium also plays a role in the mechanism of cardiac remodeling. Reactive Oxygen Species (ROS) are highly reactive molecules, produced by the normal metabolism of oxygen. ROS production is a normal component of oxidative phosphorylation; however, disregulation of ROS generation can play a role in cell dysfunction. Higher but not cytotoxic levels of ROS and signaling through β_1-andrenergic-receptor or angiotensin-receptors apparently induce mitochondria dependent apoptosis in myocytes. High mechanical strain causing strong ROS-production and β_1-andrenergic-receptor induce apoptosis, probably through ROS dependent activation of c-Jun N-terminal kinases. Under low mechanical strain lower levels of ROS are produced. Together with stimulation through angiotensin-, TNF-a, endothelin or a_1-andrenergic receptors kinase cascades are activated culminating in an activation of gene expression for cell growth leading to

myocyte hypertrophy. Moreover, oxidative stress stimulates cardiac fibroblast proliferation and activates MMPs and leads to cardiac tissue remodeling [29].

1.3 Impact of molecular and immunohistochemical biomarkers in structural myocardial diseases for risk stratification

1.3.1 Impact of Cyclophilin A and Extracellular Matrix Metalloproteinase Inducer (EMMPRIN) as risk markers in structural myocardial diseases

Cyclophilin A (CypA) is a cyclosporine binding-protein. CypA expression in patients with coxsackievirus B3-induced myocarditis is found to promote the recruitment of macrophages and T-cells and so it is believed to play a significant role in the pathogenesis of inflammatory CM [30]. Recently it was shown that CypA is an independent predictor of clinical outcome in patients with congestive heart failure [31].

EMMPRIN is a transmembrane glycoprotein which is expressed by leukocytes, epithelial and endothelial cells. It is a type I integral membrane receptor binding with many ligands such as CypA and Cyclophilin B (CypB) amongst others. EMMPRIN is significantly highly expressed in patients with inflammatory CM and can serve as a marker of myocardial remodeling. However, in non-inflammatory CM it is only slightly upregulated [32].

1.3.2 Inflammatory markers in standard histopathology and immunohistochemistry: Major Histo-compatibility Complex Class II, CD 3 and CD 68

Major Histocompatibility Complex (MHC) Class II molecules are extracellular proteins which are found on antigen-presenting cells and lymphocytes. In $CD4^+$ T-cells recognition of antigens presented on MHC-II activate T-cells which can regulate the immune response and inflammation. By this mechanism MHCII expression is believed to play a role in inflammatory heart disease [33]. MHCII expression is found to be strongly connected with the expression of other myocardial inflammation markers like CypA, CD68, CD3 in myocytes of patients with CVB3-induced myocarditis [30].

CD3 is a transmembrane receptor on the surface of T-cells. In immunohistochemistry it is used as marker of T-cells in tissue specimens. CD3 expression was shown to have a strong correlation with the expression of CypA and EMMPRIN in myocardial tissue sections of patients with inflammatory CM and is regarded as marker of myocardial inflammation [30].

CD68 is an intracellular glycoprotein that is also expressed on the surface of monocytes and macrophages. It is used as marker for macrophages in immunohistochemical stainings. Macrophage infiltration, detected by CD68 staining, plays an important role in inflammatory processes of myocardium. Its expression in tissue sections of endomyocardial biopsies of patients with CVB3-induced myocarditis is significantly correlated with the expression of CypA, EMMPRIN, CD3 and MHCII [30].

1.4 Impact of Gremlin-1 in the adult organism and in fibrosis

Gremlin-1 (Grem1) is a member of the DAN and cerberus protein family, a subgroup of the cysteine knot superfamily which are antagonists of bone morphogenetic proteins (BMPs). Grem1 is a 184 amino-acid protein with a size of 20.7 kDa. It exists in two isoforms, a secreted and a cell-associated one [34].

At first Grem1 was identified as a novel gene named *drm* that was transcriptionally down-regulated in v-mos-transformed fibroblasts of rat embryos [35]. In 1998 at the Department of Molecular and Cell Biology in the University of California, Berkeley, this gene was renamed Gremlin and was shown to be expressed in the neural crest of Xenopus embryos and plays a role in embryonic development [36]. Nowadays, the role of Grem1 in embryogenesis is well described. Grem1 expression contributes to lung, kidney and limbs development [37]. Its expression is also crucial for cardiogenesis, angiogenesis, setup of the anterior-posterior body axis and left-right symmetry [38, 39] Grem1 inhibits monocyte chemotaxis by interacting with Slit1 and Slit2 proteins [40] . Furthermore, it interacts directly with endothelial cells and plays a significant role as proangiogenic factor in angiogenesis, suggesting Grem1 as a possible target in cancer treatment [41] .

Interestingly, in adults Grem1 expression is also shown to be involved in chronic inflammatory diseases leading to fibrotic remodeling of organs, like lungs, kidney and liver [37, 42-44].

1.4.1 Interaction of Gremlin-1, bone morphogenetic proteins and transforming growth factor beta: Characterization of the signaling pathways

Transforming growth factor beta (TGF-ß) is a cytokine that plays an important role in regulating many cell functions like cell proliferation and differentiation. It is a secreted protein, found in 3 isoforms TGF-ß1, TGF-ß2 and TGF-ß3. TGF-ß acts on epithelial cells and is a protein secreted by many cell types. Through TGF-ß/Smad (Small tail and mothers against decapentaplegic)-signaling pathway TGF-ß leads to epithelial to mesenchymal transition (EMT), a process which is shown to contribute to fibrinogenesis [42]. Smads are intracellular proteins that transfer the signals from TGF-ß ligands binding on cell surface to the nucleus. Binding of the receptor with the TGF-ß ligand leads to the activation of Smad3, which is a receptor-associated Smad (R-Smad). The phosphorylated R-Smad binds to a Smad4, which is a common Smad (coSmad). This complex is then transferred into the nucleus and leads to the transcription of various genes. In epithelial cells of patients with kidney fibrosis the TGF-ß/Smad signaling pathway is found to promote EMT [43].

BMPs are a family of 20 cytokines, members of the TGF-ß superfamily. They have a morphogenetic role in embryonic development and the normal formation of many tissues. BMPs promote osteoblast differentiation and induce bone formation. They also induce kidney and heart development and regulate hepatic glucose homoeostasis and fertility [45]. BMPs induce cell regeneration and mediate apoptosis of myofibroblasts. BMP-7 is shown to play a role in reducing the release of proinflammatory cytokines at epithelial cells of kidney tissue and it counteracts the TGF-ß/Smad signaling in those cells [42].

Grem1 inhibits BMP-2,-4 and -7. The mechanisms of inhibition can be either extra- or intra-cellular. Through extracellular binding with secreted BMPs, Grem1 prevents the BMP ligand to bind with its receptor on cell surface. Through intracellular antagonism, Grem1 binds the BMP precursor protein and prevents the secretion of the mature protein. Moreover, Grem1 has the ability to

bind directly with surface proteins (like Slit proteins) in vascular cells [37], *Figure 1.*

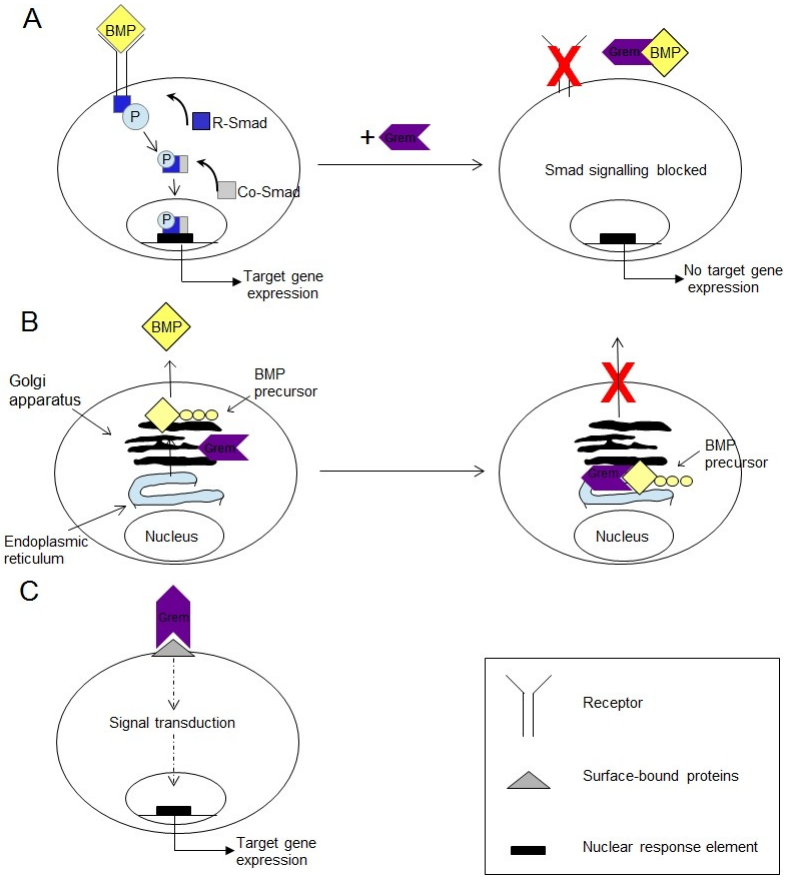

Figure 1. Grem1 antagonism in vascular cells: (A) extracellular BMP inhibition through binding of secreted BMP by Grem1 (B) intracellular BMP inhibition through Grem1 binding with BMP precursor protein (C) direct binding of Grem1 with surface of vascular cells through Grem1 binding to slit proteins. *According to Costello et al. [37]*

The overexpression of Grem1 leads to reduction of BMP signaling and to up-regulation of the profibrotic TGF-ß signaling. TGF-ß itself induces the Grem1 production (positive feedback). Promoting the TGF-ß-induced EMT Grem1 induces the ECM accumulation and contributes to fibrinogenesis [37].

1.4.2 Gremlin-1 and fibrosis

1.4.2.1 Gremlin-1 and kidney fibrosis

Grem1 expression plays a significant role in renal embryogenesis but its expression is supposed to be silent in the normal adult kidney. In patients with chronic kidney disease (CKD) it is shown that Grem1 is reactivated and induces the EMT. EMT is a mechanism by which the adult kidney epithelium responds to injury. During this process, the cells of the injured epithelium, which are characterized by phenotypic plasticity, lose the epithelial characteristics and convert to mesenchymal cells losing polarity, cell-cell adhesion and gaining motility, *Figure 2.*

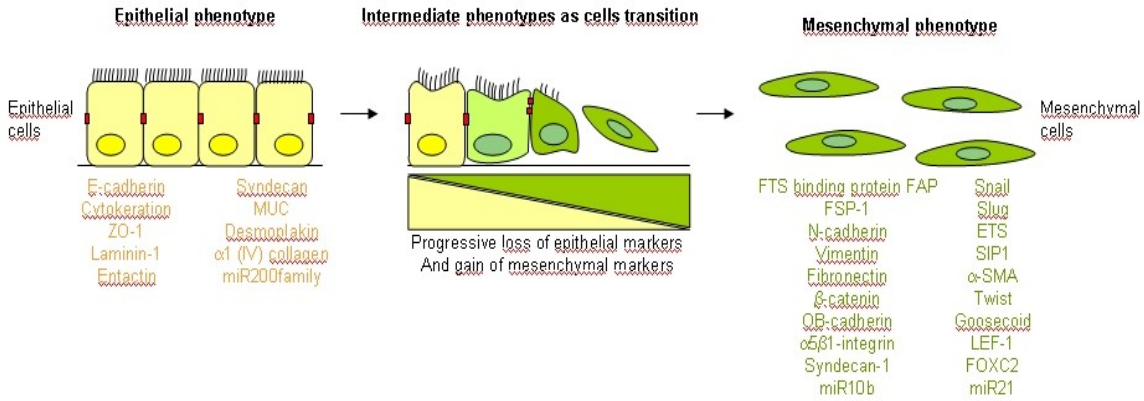

Figure 2. The process of EMT. The epithelial cells lose their polarity, their epithelial markers (listed on left side), gain mesenchymal markers (listed on right side) and mobility, and finally turn into mesenchymal cells. According to Kalluri et al. [46]

The epithelial cells avoid apoptosis and migrate into tubulointerstitium because of their fibroblasts phenotype. Through this mechanism fibrogenesis in tubulointerstitium is promoted. This is how Grem1 expression is believed to lead to ECM accumulation in interstitial place and atrophied tubular structure, contributing eventually to renal fibrosis [42]. With the same mechanism Grem1 expression in parietal epithelial glomerular cells of patients with pauci-immune crescentic glomerulonephritis is believed to play a role in the pathogenetic profile of the disease. TGF-ß induces the Grem1 expression. The parietal

epithelial cells undergo EMT and convert to fibroblasts which contribute to the scar formation of crescentic glomerulonephritis [43].

1.4.2.2 Gremlin-1 and idiopathic pulmonary fibrosis

By inhibiting BMP-4-mediated signals, Grem1 is believed to play a significant role in lung development. Both, loss and overexpression of the gene leads to abnormal lung formation. Increased expression of Grem1 is detected in the lung interstitium of patients with idiopathic pulmonary fibrosis (IPF). IPF is a disease characterized by fibroproliferation, tissue destruction and excessive accumulation of ECM. The cells of injured lung epithelium undergo EMT as response to TGF-ß signaling [47]. BMPs normally induce regeneration of the epithelium and myofibroblasts apoptosis. Grem1 as BMP inhibitor inhibits this process and leads to ECM accumulation. With this mechanism Grem1 is shown to play a significant role in IPF. Furthermore, Grem1 overexpression in pulmonary microvascular endothelial cells and smooth muscle cells induces the apoptosis of the endothelium and the uncontrolled proliferation of the smooth muscle cells. This promotes the vessel inflammation and is believed to contribute to pulmonary hypertension [37], *Figure 3.*

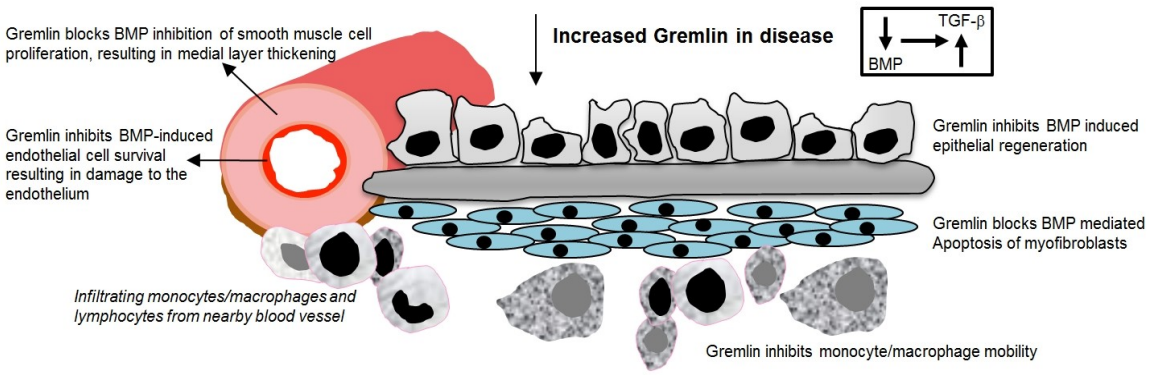

Figure 3. Contribution of excessive Grem1 expression to cellular changes in the lung. Grem1 inhibits BMP induced epithelial regeneration and BMP mediated apoptosis of myofibroblasts and leads to ECM accumulation. High levels of Grem1 lead to uncontrolled proliferation of smooth muscle cells and promote damage to the endothelium, causing inflammation. *According to Costello et al [37].*

1.4.2.3 Gremlin-1 and liver fibrosis

Liver fibrosis is a progressive disease which is caused by various reasons like viral hepatitis, parasitic infection, metabolic and autoimmune disorders, congenital abnormalities and drugs and alcohol abuse. All these disorders lead to chronic liver injury and contribute to hepatic impairment, fibrosis and finally cirrhosis. In the activated hepatic stellate cells (HSC) of fibrotic livers of mice increased expression of Grem1 is reported. Cytokines, TGF-ß and oxidative stress induce the quiescent hepatic stellate cells activation. Through activation the cells lose a part of their retinoid storage capacity and they transform into myofibroblasts. The cell proliferation becomes excessive and ECM is increasingly produced. At the same time, during the HSC transdifferentiation the expression of MMP-inhibitors like tissue inhibitor of metalloproteinases (TIMP) TIMP-1 and -2 and the plasminogen activator inhibitor type 1 are induced. Consequently, the degradation of ECM is reduced. The combination of increased ECM production and decreased degradation due to Grem1 expression on hepatic cells is believed to lead to ECM accumulation and fibrosis. Finally, Grem1 could be used as specific marker of hepatic fibrogenesis and inhibition of its expression could be beneficial for patients suffering from the disease [44].

1.5 Hypothesis

The lack of established histological criteria or markers to classify the severity of the structural myocardial diseases leads to the urgent need to find new biomarkers which could assess the short-term and long-term prognosis. A biomarker with high prognostic impact could be used in routine histological staining and contribute to the identification of patients with CM who have a high risk for sudden cardiac death and heart failure at early stages of the disease. Grem1 is a biomarker whose expression correlates with the formation of fibrotic tissue in kidney, lung and liver. Until now not much is known about its role in the process of fibrosis in human myocardium.

Since Grem1 is a BMP antagonist that plays a role in chronic fibrotic diseases of other organs and since myocardial fibrosis is a key step in the pathophysiology of myocardial remodeling, we hypothesized that the expression of Grem1 may play a role in structural myocardial disease and might have a predictive value in the diagnostic workup of patients with structural myocardial disease.

2. Materials and methods

2.1 Materials

2.1.1 Antibodies

Primary Antibodies

Antigen	Host Species	Reactivity	Manufacturer
CD3	Mouse, monoclonal	human	Novocastra Laboratories, Newcastle on Tyne, UK
CD68	Mouse, monoclonal	human	Dako, Hamburg, Germany
HLA-DR-α	Mouse, monoclonal	human	Dako, Hamburg, Germany
Gremlin 1	Rabbit, polyclonal	human	Biozol/Abnova, Eching, Germany
Gremlin 1	Rabbit, polyclonal	mouse	Abcam, Cambridge, UK
Actin	Rabbit, polyclonal	mouse	Abcam, Cambridge, UK

Secondary antibodies

Anti-mouse	Rabbit, polyclonal	mouse	Dako, Hamburg, Germany
Anti-rabbit	Goat, polyclonal	rabbit	Dako, Hamburg, Germany
Anti-rabbit	Donkey	rabbit	LI-COR Biosciences, Bad Homburg, Germany

Isotype controls

Isotype	Species	Manufacturer
IgG1	Mouse	Dako, Hamburg, Germany
IgG, polyconal	Rabbit	Dako, Hamburg, Germany

2.1.2 Kits

iQ SYBR Green Supermix — Bio-Rad, Munich, Germany

Biorad Protein Assay — Bio-Rad, Munich, Germany

RNEasy Mini kit for RNA Isolation — Qiagen, Hilden, Germany

Vectastain Elite ABC Kit	Vector, Burlingame, USA

2.1.3 Software

ImageJ Software	National Institutes of Health, USA
SPSS Software version 19.0	IBM, USA

2.1.4 Chemicals and reagents

Acid fuchsin	Sigma, St. Louis, USA
Citric acid	Sigma, St. Louis, USA
Eosin powder	Roth, Karlsruhe, Germany
Giemsa-solution	Sigma, St. Louis, USA
Glacial acetic acid	Merck, Darmstadt, Germany
Hemalum stock solution	Merck, Darmstadt, Germany
Hydrogen peroxide	Merck, Darmstadt, Germany
Immobilon-FL PVDF Membrane	Merck Millipore, Schwalbach, Germany
Light Green SF Yellowish	Sigma, St. Louis, USA
Orange G	Sigma, St. Louis, USA
Ponceau S	Roth, Karlsruhe, Germany
Protein block serum free	Dako, Hamburg, Germany
RNAlater	Life Technologies GmbH, Darmstadt Germany
Roti Histol	Roth, Karlsruhe, Germany

Roti Histokitt	Roth, Karlsruhe, Germany
Sodium phosphotungstate hydrate	Sigma, St. Louis, USA
Trisodium citrate dihydrate	Merck, Darmstadt Germany
Weigert's iron hematoxylin Solution A	Roth, Karlsruhe, Germany
Weigert's iron hematoxylin Solution B	Roth, Karlsruhe, Germany

Aqueous acetic acid:

200ml distilled water

15 drops of glacial acetic acid

Citrate buffer, pH6:

41ml 0.1M Trisodium citrate dehydrate (2.94g dissolved in 100ml aq. dest)

9ml 0.1M Citric acid (1.92g dissolved in 100ml aq. dest)

450ml Aqua dest.

pH adjusted to 6.0 before use

1% Eosin staining solution:

200ml distilled water

2g Eosin powder

1 drop glacial acetic acid

Giemsa staining solution:

80ml distilled water

20ml Giemsa-solution (Sigma)

3-5 drops of glacial acetic acid

Hemalum staining solution:

160ml distilled water

40ml Hemalum stock solution

Filtrated through folded filter paper

Light Green SF Yellowish stain solution:

0.6g Light Green SF Yellowish

0.6ml glacial acetic acid

300ml distilled water

Phosphotungstic acid – Orange G stain solution:

12g Sodium phosphotungstate hydrate

6g Orange G

300ml distilled water

Ponceau-acid fuchsin stain solution:

0.2 g Ponceau S

0.1g Acid fuchsin

0.6ml glacial acetic acid

300ml distilled water

Weigert's iron hematoxylin stain solution:

100ml of Weigert's iron hematoxylin Solution A

100ml of Weigert's iron hematoxylin Solution B

2.1.5 Clinical and lab equipment

Biopsy forceps	Cordis Corporation, Waterloo, Belgium
iE33 Transthoracic echocardiography	Philips Medical Systems, Hamburg, Germany
Odyssey infrared imaging system	LI-COR Biosciences, Bad Homburg, Germany
PerfectBlue Semi-dry Electro Blotter	Peqlab Biotechnologie GmbH, Erlangen, Germany
XCell Sure Lock Mini-Cell	Life Technologies GmbH, Darmstadt, Germany

2.2 Study design and assessment of risk factors

The study enrolled 214 consecutive patients who underwent endomyocardial biopsy as part of the routine clinical evaluation for suspected structural myocardial disease at our university hospital from August 2007 until November 2010 .

Patients were included if they showed either impaired global or regional left ventricular function, enlargement of the LV, myocardial hypertrophy, or abnormal myocardial texture in echocardiography suggesting a structural myocardial disease. Significant coronary artery disease (> 50% diameter luminal stenosis of two or more epicardial vessels or left main or proximal left

anterior descending coronary artery stenosis > 50%) was ruled out by coronary angiography in all patients [48].

A careful history and physical examination as well as laboratory testings were collected of all patients at enrollment. Risk factors included LVEF, left ventricular enddiastolic diameter (LVEED), NYHA functional class, troponin I (TnI) and BNP.

LVEF was measured by contrast ventriculography in the 30° right anterior oblique and in the 60° left anterior oblique views in all patients undergoing cardiac catheterization. LVEDD was analyzed by 2-dimensionally guided M-mode echocardiography in all patients [48].

All patients received medication according to current ESC and ACC/AHA guidelines depending on their left ventricular function and heart failure symptoms [49] .

The study conformed to the principles outlined in the Declaration of Helsinki, and informed consent was obtained from all patients. The study was approved by the local ethics committee (Project-No. 253/2009BO2).

2.3 Study end points and follow-up

Patients were scheduled in our outpatient clinic for clinical follow-up every 6 months. Patients who missed their follow-up visit were contacted by telephone for an interview. None of the patients was lost during follow-up .

Study endpoint was a combination of all-cause of death or re-hospitalization due to heart failure within a follow-up period of 3 years. The occurence of an end point and all clinical events were reviewed by an independent end point committee [48].

2.4 Endomyocardial biopsy

Biopsy sample site was the right or left ventricle (84.1% right ventricular septum) and at least six specimens with a diameter of 1 to 3 mm were harvested. Biopsy samples were taken with a dedicated bioptome advanced through various 7F coronary guiding catheters. Samples were immediately fixed under sterile conditions in 4% buffered formaldehyde for haematoxylin and eosin (HE), Masson's trichrome, and Giemsa staining or further immunohistochemistry. 4µm thick paraffin-embedded tissue sections were stained and examined by light microscopy. Other samples were quick-frozen or fixed in RNA-later for PCR detection of viral genomes [50-54] [48].

2.5. Histology and immunohistochemistry

2.5.1 Histology

For histological analysis fixed biopsy samples were deparaffinized and afterwards stained according to protocols for hematoxylin and eosin (HE), Masson's trichrome or Giemsa staining.

Hematoxylin-Eosin staining is used as a diagnostic tool in medical practice to differentially stain tissue. Nuclei are colored blue by haematoxylin while eosinophilic structures such as cytoplasm, Lewy bodies, Mallory bodies, red blood cells and collagen are colored pink to red by eosin.

Masson's trichrome is a routine three color stain used in histopathology to detect collagen fibers in different tissues. Nuclei are stained black, collagen fibers blue, the background red so the cells can be distinguished from the connective tissue.

Giemsa staining is widely used in cytogenetics as it stains chromosomes by interacting with DNA and as differential stain for the histopathological diagnosis of several parasitic infections. It is also a classic stain for peripheral blood smears. Erythrocytes, lymphocyte cytoplasm, platelets, monocytes and

leukocytes are stained differently so that they can be distinguished during microscopy. Giemsa staining colors nuclei dark blue, the cytoplasm light blue and the collagen pale pink.

Deparaffinization and rehydration was achieved by incubation in Roti-Histol twice for 10 minutes each and ethanol in descending concentrations, 100% ethanol twice for 5 minutes, 96% and 70% ethanol for 5 minutes each.

For hematoxylin and eosin staining slides were washed after deparaffinization for 5 minutes in distilled water and incubated in Mayer's hemalum for 5 minutes. Slides were washed in distilled water and incubated in warm running tap water for 15 minutes. After staining for 3 minutes in 1% Eosin, slides were washed in distilled water and dehydrated in an ascending alcohol dilution series 70% - 80% - 96% ethanol (10 seconds each), 100% ethanol (twice 5 minutes each) and Roti Histol (5min) and mounted with a Roti-Histokitt.

For Masson's trichrome staining slides were incubated for 5 minutes in distilled water after deparaffinization and then incubated for 2 minutes in Weigert's iron hematoxylin. The slides were then washed in tap water and incubated in warm running tap water for 15 minutes. Following an incubation in ponceau-acid fuchsin for 5 minutes, slides were washed in distilled water and incubated in phosphotungstic acid – Orange G for 10 minutes. Slides were washed again in distilled water and incubated in light green SF yellowish for 5 minutes. After a final washing step sections were dehydrated in an ascending alcohol dilution series 70% - 80% - 96% ethanol (10 seconds each), 100% ethanol (twice 5 minutes each) and Roti Histol for 5 minutes and mounted with Roti-Histokitt.

For Giemsa staining slides were washed in distilled water following deparaffinization and incubated in Giemsa staining solution for 30 minutes, again washed in distilled water and incubated twice in aqueous acetic acid for 3 seconds each. Sections were dehydrated in an ascending alcohol dilution series (96% ethanol twice for 3 seconds, 100% ethanol twice for 5 seconds and Roti Histol 5min) and mounted with a Roti-Histokitt.

2.5.2 Immunohistochemistry

Biopsy-sections were also analyzed by immunhistochemistry. Immunhisto-chemistry is a method used to detect antigens of interest in tissue samples. After binding of a primary antibody specific for the antigen a subsequent incubation with a biotinylated secondary antibody directed against the species of the primary antibody and adding avidin-peroxidase complexes leads to the accumulation of peroxidase at the antigen. Visualization of the antigen is achieved through a final incubation step with a peroxidase-sensitive color precursor compound. Oxidation of the compound causes precipitation of color where the antigen is present in the sample.

An avidin-biotin-immunoperoxidase method was used for immunohistochemistry according to the manufacturer's protocol. Monoclonal antibodies against the following antigens were used to identify, localize and characterize mononuclear cell infiltrates [48].

- CD3 for T-cells
- CD68 for macrophages
- HLA-DR-α to assess MHCII expression on antigen-presenting immune cells
- Grem1 was used to detect Grem1 expression in cardiomyocytes or macrophages

After deparaffinization slides were incubated in boiling citrate buffer pH6 in the microwave three times for 5 minutes each for antigen retrieval. After cooling down, slides were washed in PBS three times for 5 minutes each.

To inhibit endogenous peroxidase, slides were incubated in the dark for 15 minutes in 3% hydrogen peroxide and then washed in PBS. Sections were circled with a hydrophobic barrier pen and incubated with serum free blocking reagent for 15 minutes to block unspecific binding of antibodies. After decanting the blocking solution, either primary antibody or a corresponding isotype (see table below) or PBS were pipetted and incubated for 1h at room temperature or

overnight at 4°C. Slides were then washed three times in PBS, 0.05% Tween for 5 minutes each. Afterwards sections were incubated with a biotinylated secondary antibody directed against the species of the primary antibody for 30 minutes at room temperature and then washed three times in PBS, 0.05% Tween for 5 minutes each. Streptavidin-HRP was added on top of sections, incubated for 30 minutes at room temperature and washed three times in PBS, 0.05% Tween, 5 minutes each. Sections were incubated with DAB-Chromogenic-Solution for different times depending on primary antibody used (see list below), dipped in PBS to stop staining, counterstained in hemalum for 3 minutes, incubated in running tap water for 10 Minutes then dehydrated in an ascending alcohol series and mounted with Roti-Histokitt.

Antibody and dilution	Isotype Control	Secondary antibody	DAB incubation time
mouse anti human CD3	Mouse IgG1	Rabbit anti mouse	10 minutes
mouse anti human CD68	Mouse IgG1	Rabbit anti mouse	5 minutes
mouse anti human HLA-DR-a	Mouse IgG1	Rabbit anti mouse	5 minutes
rabbit anti human Gremlin	Rabbit IgG	Goat anti rabbit	5 minutes

2.6. Histopathological analysis

Histological analysis of suspected myocarditis followed the Dallas criteria defined as:

i) lymphocytic infiltrates in association with myocyte necrosis in acute myocarditis

ii) inflammatory infiltrates without microscopic signs of myocyte injury in chronic myocarditis [49, 55-60]

Stained myocardial tissue sections were evaluated by a semiquantitative score scheme ranging from 1 (very low, if any expression) to 4 (ubiquitous very strong expression) for CD 68 and MHC II expression . Grem1 staining was classified “negative” (no / low expression, score 1 or 2) or “positive” (moderate / high

expression, score 3 or 4). Scores for Grem1 were obtained in a blinded manner from 1 to 2 sections for each staining by two blinded co-investigators [61, 62]. The amount of cardiac fibrosis was defined as an index [48].

The percentage area of fibrosis in the section was obtained by dividing the sum of the fibrotic areas of the section by that of the total tissue area as described previously [63]. According to this fibrosis index, patients were classified as having no or mild, moderate, or severe myocardial fibrosis [48].

2.7 Molecular detection of viral genomes by nested PCR

PCR is a method used to amplify DNA. As a diagnostic tool PCR is used to amplify minimal amounts of DNA to detect viral or bacterial infections.

Basic PCR consists of 3 steps:

1. Denaturation of a double-stranded DNA-template, usually at a high temperature around 95°C.
2. Annealing of primers specific for the 3'-end of both strands of the DNA-sequence of interest, forming an incomplete DNA-double strand.
3. Elongation of the incomplete complementary DNA-strand by adding single deoxynucleoside triphosphates (dNTPs) at the 3'-end of the primers catalyzed by a thermostable DNA-polymerase, usually Taq-polymerase.

Steps 1 through 3 are repeated up to 35 times. Under optimal conditions each cycle would double the amount of DNA present at the start of the cycle resulting in an exponential amplification with 2^n-fold amplification after n cycles [64].

Unspecific binding of the primers can cause unspecific amplification of DNA which can be interpreted as false positive results. To increase amplification specificity necessary for reliable diagnoses a nested PCR protocol was used.

Nested PCR consists of two PCR reactions with 2 sets of primers. After a first amplification of sample DNA with the first primer set the product of this reaction is used as template for a second PCR with a second set of primers. Consequently, in the product of the second PCR the contamination of DNA fragments which are products of the non-specific DNA amplification is reduced.

Nested PCR was carried out at the Institut für Molekulare Pathologie in Tübingen, Germany. It was performed on deep-frozen or RNAlater-fixed endomyocardial biopsy samples according to manufacturer's protocol [56].

A biopsy was considered positive for viral infection, if viral genome was detected by nested PCR [65]. Samples were tested for influenza A and B, adenoviruses, parvovirus B19, enterovirus species (comprising coxsackie viruses and echo viruses), human herpes virus type 6, 7 and 8, herpes simplex virus, human cytomegalovirus, varicella-zoster virus, and Epstein-Barr virus.

2.7.1 RNA preparation and Real-Time-quantitative PCR (qPCR) analysis

In a qPCR specific sequences of a copy DNA (cDNA) are amplified using specific primers in the same way as in a basic PCR (see 2.7). The amplified sequences form DNA double strands (dsDNA) which bind SYBR-Green. SYBR-Green can be excited by light of 494nm wavelength and emits light of 521nm wavelength. Binding of SYBR-Green by dsDNA causes a local concentration of SYBR-Green resulting in a stronger signal compared to the background of free unbound SYBR-Green. With increased cycle count the amplification of primer defined cDNA grows exponentially which in turn causes an increase in fluorescence of dsDNA bound SYBR-Green. The timepoint at which the SYBR-Green fluorescence is stronger than the background signal is defined as the threshold cycle or C^t. By comparing C^t values for genes of interest compared to C^t values reference genes the relative gene expression strength can be calculated using the formula $2^{(-\Delta Ct)}$. Gene expression of reference genes needs

to be constant and not be influenced by external stimuli. So called “house-keeping” genes which are expressed constitutively in cells are chosen as reference genes. For this qPCR Glyceraldehyde 3-phosphate dehydrogenase (GAPDH) was chosen as reference gene.

Quantitative real-time PCR (qPCR) was performed to measure the relative strength of expression of Gremlin1 in mouse embryonic cardiomyocytes HL-1 compared to a reference gene. Total RNA was extracted from HL-1 cells using the RNEasy kit and reverse-transcribed into cDNA with the Im-Prom IIReverse Transcription System . 20 ng of cDNA were amplified with the iQ SYBR Green Supermix on an iCycler iQ using *GAPDH* as reference. Relative gene expression levels were quantified using the formula $2^{-(Ct(Grem1) - Ct(gapdh))}$.

2.8 Sodiumdodecylsulfate polyacrylamide gel electrophoresis (SDS-PAGE) and Western Blotting

2.8.1 SDS-PAGE

Cell lysates were analyzed using SDS-PAGE. For this cell lysates are boiled under reducing conditions in order to denature their secondary and tertiary structures. At the same time proteins are given a negative charge by uniformly covering them with SDS, masking their own negative or positive electrical charges.

Boiled lysates are then loaded onto a polyacrylamide gel near the cathode and an electric current is applied. Due to their uniform negative electric charge the proteins migrate in the electrical field through the gel towards the anode.

Proteins move through the gel at different speeds because of the mesh formed by acrylamide monomers upon polymerization. Smaller proteins are held back less than larger proteins resulting in a separation of the proteins in the lysate according to their size over the length of the gel. Acrylamide concentration can be varied according to desired resolution of separation. A higher concentration

results in a better separation of smaller proteins while a lower concentration would be used to separate larger proteins [66, 67].

A variation of the SDS-PAGE is the discontinuous SDS-PAGE. Here proteins are first concentrated in a collecting gel with a lower concentration of acrylamide and then separated in a separating gel with a higher acrylamide concentration.

2.8.1.1 SDS-PAGE protocol

30µg of HL1-cardiomyocyte cell lysate were separated using discontinuous SDS-PAGE with 1x running buffer. Lysates were boiled for 10 minutes at 95°C under reducing conditions using 5x Laemmli-buffer supplemented with 5% b-mercaptoethanol and then loaded onto a gel consisting of a collecting gel with a concentration of 4% acrylamide and a separating gel with a concentration of 15%.

2.8.2 Western Blot (WB)

Western blotting is a technique used to identify proteins in a cell lysate following separation by SDS-PAGE. Separated proteins are transferred onto a protein binding membrane by applying through an electrical field (electroblotting). The gel and membrane are sandwiched between transfer-buffer soaked Whatman-papers with the membrane closer to the anode and the gel closer to the cathode. Application of an electric current causes the negatively charged proteins to move out towards the anode onto the membrane. After blotting specific membrane bound proteins can be made visible by immune detection (chemiluminescent or fluorescent). Incubation with a protein specific primary antibody followed by incubation with a secondary antibody directed against the primary antibody and carrying a reporter molecule leads to the detection of protein of interest.

2.8.2.1 Western Blot protocol

Proteins were blotted onto a 0.45µm polyvinylidene difluoride (PVDF)-membrane using a semi-dry blotter. After activation of the PVDF membrane in methanol the gel and membrane were sandwiched between two 3mm thick pieces of Whatman-paper soaked in 1x transfer buffer and placed in the blotting device with the membrane closer to the anode. Proteins were blotted for 75 minutes with a constant current of 110 mA and 15V. The membrane was then blocked in 5% skim milk in PBS for one hour at room temperature. Murine Gremlin1 was detected with a polyclonal rabbit anti-mouse-Gremlin1 antibody used in a dilution of 1:1000 in 5% skim milk+0.1% Tween in PBS. Actin was used as internal loading control and detected with a polyclonal rabbit anti-mouse-actin, diluted 1:1000 in 5% skim milk+0.1% Tween in PBS. Incubation with primary antibodies was carried out at room temperature for one hour. Membranes were then washed three times for 5 minutes in PBS+0.1% Tween and then incubated for one hour at room temperature with a secondary donkey anti-rabbit antibody, diluted 1:15.000 in 5% skim milk+0.1% Tween in PBS, carrying a marker protein for near infrared fluorescence detection. Near-infrared-fluorescence detection on an infrared imaging system was carried out after washing again three times with PBS+0.1% Tween.

2.9 Statistical analysis

Continuous variables are expressed as mean ± standard deviation and were compared using the Mann–Whitney U-test. Categorical data are presented as proportions and were analyzed by chi-square test. Cox proportional-hazards regression analysis was performed to assess the association of risk factors with endpoint occurrence. For this analysis, continuous variables were dichotomized using the patients` median as cut-off values (LVEF<40%, LVEDD>53mm, NYHA ≥ II, TnI>0.03 µg/l, and BNP >269 ng/l). After univariate analysis, statistically significant variables ($p<0.05$) were forced to enter the multivariate model, which was adjusted for age and gender. Survival curves of patients were

calculated by Kaplan-Meier analyses and compared using the Log-Rank test. The risk for endpoint occurrence is presented as hazard ratio (HR) with 95% confidence interval (CI). Time point for begin of survival analysis was the date of the endomyocardial biopsy. Correlation of expression of Grem1 and grade of fibrosis was tested by Spearman correlation. Comparisons were considered statistically significant, if the two-sided p value was < 0.05. Statistical analyses were performed using SPSS software version 19.0 (SPSS Inc., Chicago, IL, USA) [48].

3. Results

3.1 Patient population and risk factors

We studied a consecutive cohort of 214 patients with structural myocardial disease not related to coronary artery disease. Immunohistological analysis showed that 160 of the patients (74.8%) were Grem1 positive and 54 (25.2%) were Grem1 negative. The demographic details and basic characteristics are presented in table 1 along with p-values comparing Grem1 positive and negative groups. There was no significant difference in the distribution of the clinical characteristics between the Grem1 positive and Grem1 negative groups, except for the mean LVEDD, LVEF and CRP.

Patients showed a mean age of 52 (44-66) years, with a mean age of 52 years in the Grem1 positive and Grem1 negative group as well (p=0.856). 25.7% of all patients were female and they were equally distributed in the two groups, 26.3% in the Grem1 positive group and 24.1% in the Grem1 negative group (p=0.752). Mean BMI of the patients was 26 (23-29), with no significant difference in the Grem1 positive and Greml1 negative groups (p=0.764) and 82.2% of the patients entering the study were experiencing heart failure NYHA class ≥ II, with 81.9% of the Grem1 positive and 83.3% of the Grem1 negative patients experiencing heart failure NYHA ≥ II (p=0.808).

The concomitant cardiac medication at study entry was the typical heart failure therapy with 78.5% of the patients taking β-blockers, 69.2% ACE-inhibitors, 17.3% ARB, 59.3% diuretics and 48.1% aldosterone antagonists. The cardiac medication was almost equally distributed in the Grem1 positive and negative group with p values of p=0.194 for β-blockers, p=0.203 for ACE-inhibitors, p=0.890 for ARB, p=0.988 for diuretics and p=0.059 for aldosterone antagonists.

Patients showed mean LVEDD 53(44-59) mm and mean LVEF 41(30-55) %. Between the group of Grem1 positive and Grem1 negative patients there was a significant difference in the distribution of mean LVEDD and LVEF with Grem1

positive patients having a mean LVEDD of 54mm and LVEF of 40% in comparison to the Grem1 negative patients with a mean LVEDD of 49mm and LVEF of 50% with p=0.030 and p=0.001 respectively.

Mean BNP values were 269 (73-548) ng/l, mean TnI 0.001 (0.001-0.11) µg/l, mean CK 97 (63-153) U/l and mean CRP 0.6 (0.1-1.6) mg/dl. There was no significant difference in the distribution of BNP (p=0.882), TnI (p=0.268) and CK (p=0.516) in the two groups. CRP was found to be significantly increased in the Grem1 positive patients with a mean CRP of 0.7mg/dl in comparison to the Grem1 negative patients with a mean CRP of 0.4mg/dl (p=0.015).

PCR analysis showed that 33.2% of myocardial biopsies were virus-positive; 9.8% EBV, 16.8% PBV, 8.9% HHV 6, 0.5% Influenza A and B and 0.9% CVB3. The distribution of virus positive biopsies in the Grem1 positive and negative group was almost equal with no significant difference between the two groups with p=0.492 for EBV positive, p=0.381 for PVB19 positive, p=0.909 for HHV6 positive, p=0.560 for influenza A/B positive and p=0.418 for CVB3 positive biopsies.

Further immunohistological analysis showed that 107 (50.0%) of all patient biopsies were CD 68/CD3/MHC II positive. 52.5% of Grem1 positive and 42.6% of Grem1 negative patients were found to be CD 68/CD3/MHC II positive (p=0.208).

Table 1. Baseline characteristics of the patient population, as published in [48]

Parameters	**All Patients (n=214)**	**Grem1 positive (n=160, 74.8%)**	**Grem1 negative (n=54, 25.2%)**	**P***
Clinical characteristics				
Mean Age, y	52 (44-66)	52 (43-66)	52 (47-65)	0.856
Females	55 (25.7%)	42 (26.3%)	13 (24.1%)	0.752

BMI (kg/m²)	26 (23-29)	26 (23-30)	26 (24-29)	0.764
NYHA ≥II	176 (82.2%)	131 (81.9%)	45 (83.3%)	0.808
Concomitant cardiac medication at study entry				
ß-Blockers	168 (78.5%)	129 (80.6%)	39 (72.2%)	0.194
ACE-I	148 (69.2%)	119 (74.4%)	39 (72.2%)	0.203
ARB	37 (17.3%)	22 (13.8%)	7 (13.0%)	0.890
Diuretics	127 (59.3%)	95 (59.4%)	32 (59.3%)	0.988
Aldosterone antagonists	103 (48.1%)	83 (51.9%)	20 (37.0%)	0.059
Parameters of the left ventricle				
LVEF (%)	41 (30-55)	40 (30-50)	50 (39-59)	0.001
LVEDD (mm)	53 (44-59)	54 (45-59)	49 (43-56)	0.030
Biomarkers				
BNP (ng/l)	269 (73-548)	260 (86-556)	285 (55-498)	0.882
TnI (µg/l)	0.001 (0.001-0.11)	0.03 (0.001-0.11)	0.001 (0.001-0.12)	0.268
CK (U/l)	97 (63-153)	96 (64-144)	101 (62-178)	0.516
CRP (mg/dl)	0.6 (0.1-1.6)	0.7 (0.2-1.7)	0.4 (0.1-1.1)	0.015
Virus-positive endomyocardial biopsies				
Total	71 (33.2%)	54 (33.8%)	17 (31.5%)	0.760
EBV	21 (9.8%)	17 (10.6%)	4 (7.4%)	0.492

PVB19	36 (16.8%)	29 (18.1%)	7 (13.0%)	0.381
HHV 6	19 (8.9%)	14 (8.8%)	5 (9.3%)	0.909
Influenza A/B	1 (0.5%)	1 (0.6%)	0 (0%)	0.560
CVB3	2 (0.9%)	1 (0.6%)	1 (1.9%)	0.418
Positive detection of immunohistological markers				
Inflammatory markers**	107 (50.0%)	84 (52.5%)	23 (42.6%)	0.208

Values are presented as n (%) or median (interquartile range). ACE-I, angiotensin-converting enzyme inhibitor; ARB, angiotensine receptor blocker; BMI, body mass index; BNP, brain natriuretic peptide; CRP, C-reactive protein; CK, creatinkinase; CVB3, coxsackievirus B3; EBV , Ebstein-Barr virus; HHV 6 , Human herpesvirus- 6; LVEDD , left ventricular enddiastolic diameter; LVEF , left ventricular ejection fraction; NYHA , New York Heart Association; PVB19 , Parvovirus B19; TnI, troponin I.

* comparison of Grem1 positive and negative patients; * *CD68 or CD3 or MHCII.

Cardiomyopathies were classified according to standardized clinical [1] and histological criteria [14] as shown in table 2.

Table 2. Classification of cardiomyopathies according to clinical and histological criteria.

Primary cardiomyopathy, **n (%)**	65 (30.4)
DCM	44 (20.6)
HNCM/HOCM	17 (7.9)
RCM	3 (1.4)
ARVC/D	1 (0.5)
Secondary cardiomyopathy, n (%)	149 (69.6)
iDCM	112 (52.3)
Acute myocarditis	6 (2.8)

Transplant rejection	7 (3.3)
Loeffler endocarditis	3 (1.4)
Microvascular ischemic cardiomyopathy	10 (4.7)
Cardiac amyloidosis	11 (5.1)

Values are n (%). ARVC/D – arrhythmogenic right ventricular cardiomyopathy/dysplasia, DCM - dilative cardiomyopathy, HNCM – hypertrophic non-obstructive cardiomyopathy, HOCM – hypertrophic obstructive cardiomyopathy, iDCM – inflammatory dilative cardiomyopathy/chronic myocarditis, RCM – restrictive cardiomyopathy.

Primary cardiomyopathy was found in 65 (30.4%) patients. Patients with primary cardiomyopathy presented with either DCM (n=44, 20.6%), HNCM or HOCM (n=17, 7.9%), RCM (n=3, 1.4%), and ARVC/D (n=1, 0.5%). 149 (69.6%) patients presented with secondary cardiomyopathy. Among these, inflammatory dilative cardiomyopathy (iDCM) was found in 112 (52.3%) patients. Six (2.8%) patients presented with acute myocarditis. Transplant rejection (n=7, 3.3%) or Loeffler endocarditis (n=3, 1.4%) was found in a minority of patients. 10 (4.7%) patients were diagnosed with microvascular ischemic cardiomyopathy and 11 (5.1%) with cardiac amyloidosis.

3.2 Myocardial expression of Gremlin-1 and correlation between Gremlin-1 expression and the degree of myocardial fibrosis

Protein expression of Grem1 was primarily found in mouse embryonic cardiomyocytes (HL-1 cells) by immunoblotting and real time PCR (Figure 4).

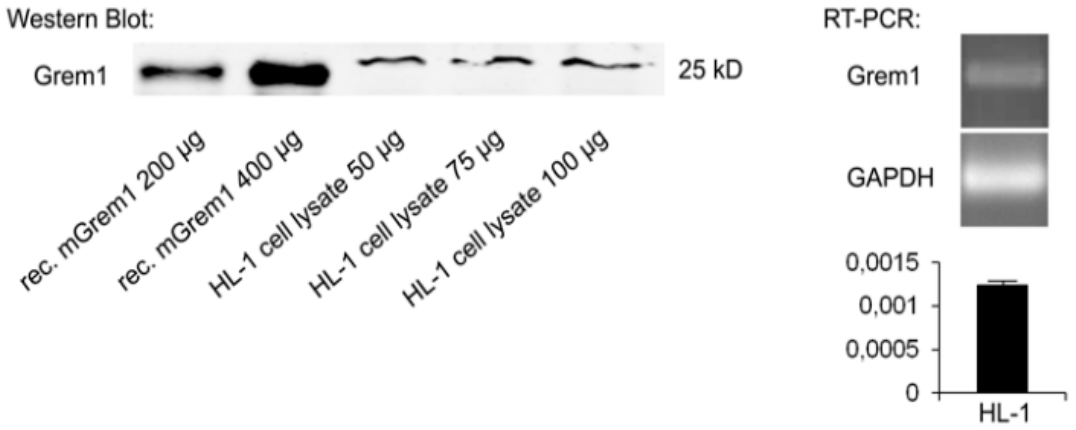

Figure 4. Protein expression of Grem1 in mouse embryonic cardiomyocytes (HL-1 cells) detected by immunoblotting and qPCR. On the right panel Grem1 expression in HL-1 cells is shown on the mRNA level by reverse transcriptase PCR (upper right panel: images of PCR products on agarose gel) and by quantitative real time PCR (lower right panel: Values of Grem1 expression are shown as relative gene expression levels using the formula $2^{(-\Delta Ct)}$).

In addition, we detected a positive myocardial expression of Grem1 in 160 (74.8%) patients out of 214 consecutive patients with structural myocardial disease in the immunohistochemical staining of myocardial tissue. Representative myocardial tissue sections of myocardium with mild, moderate and severe fibrotic remodeling are illustrated in Figure 5, as published in [48].

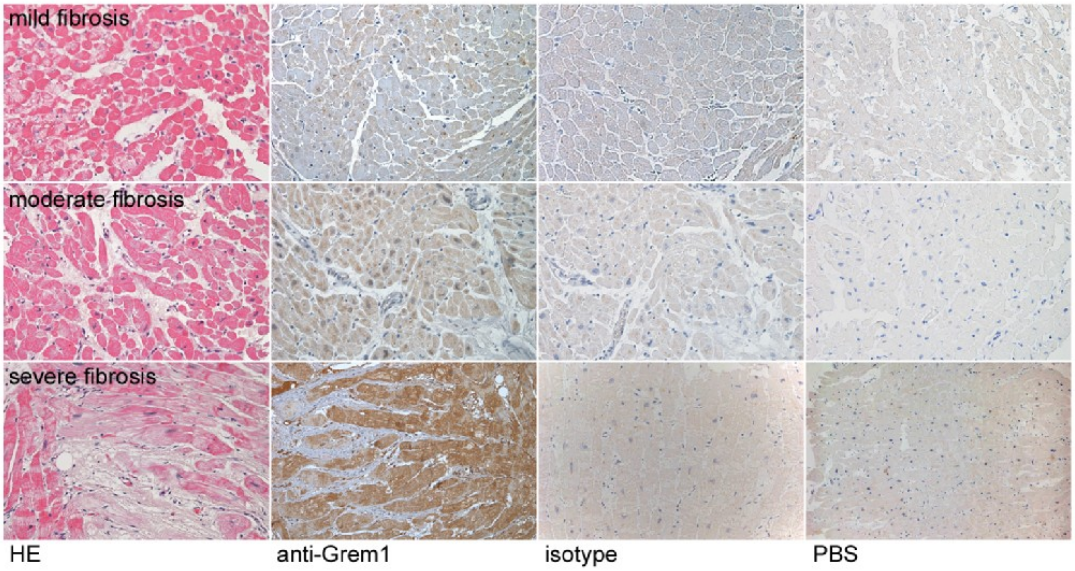

Figure 5: Immunohistochemistry detecting Grem1 expression in human myocardial tissue sections of patients with structural myocardial diseases. Myocardial tissue sections were stained with hematoxylin and eosin (HE), anti-Grem1, isotype and PBS controls. Top row: Myocardial biopsie with no/ mild fibrosis with not significantly enhanced Grem1 expression. Middle row: myocardial biopsie with moderate fibrosis and moderately enhanced Grem1 expression. Bottom row: myocardial biopsie with severe fibrosis and strongly enhanced Grem1 expression [48].

Image of mild fibrosis (top row) shows the staining of a patient with slightly reduced LVEF without signs of fibrosis. Here, Grem1 expression is not significantly enhanced. The myocardial staining of Grem1 and moderate fibrosis (middle row) depicts a patient with DCM without immunohistological signs of inflammation. In moderate fibrosis Grem1 expression is moderately enhanced. In contrast, Grem1 staining is strongly enhanced in the cardiomyocytes of a patient with severe fibrosis of the myocardium and signs of inflammation after acute myocarditis (bottom row) [48].

Of note, the levels of myocardial Grem1 expression significantly correlated with the degree of myocardial fibrosis (Spearman correlation coefficient $r=0.619$, $p<0.0001$, Figure 6), as published in [48] . Figure 6 depicts the distribution of Grem1 positive and Grem1 negative biopsies in patients with no or mild, moderate and severe fibrosis. 41 (19.1%) patients revealed no/mild myocardial

fibrosis. Among these, 34 (82.9%) patients were Grem1 negative and 7 (17.1%) were Grem1 positive. 105 (49.1%) patients showed moderate fibrosis. In this group, 15 (14.3%) were Grem1 negative and 90 (85.7%) were Grem1 positive. In 68 (31.8%) patients with severe fibrosis, 4 (5.9%) were Grem1 negative but 64 (94.1%) were Grem1 positive. In patients with enhanced myocardial fibrosis protein expression of Grem1 was significantly increased compared to patients with no or mild fibrosis [48].

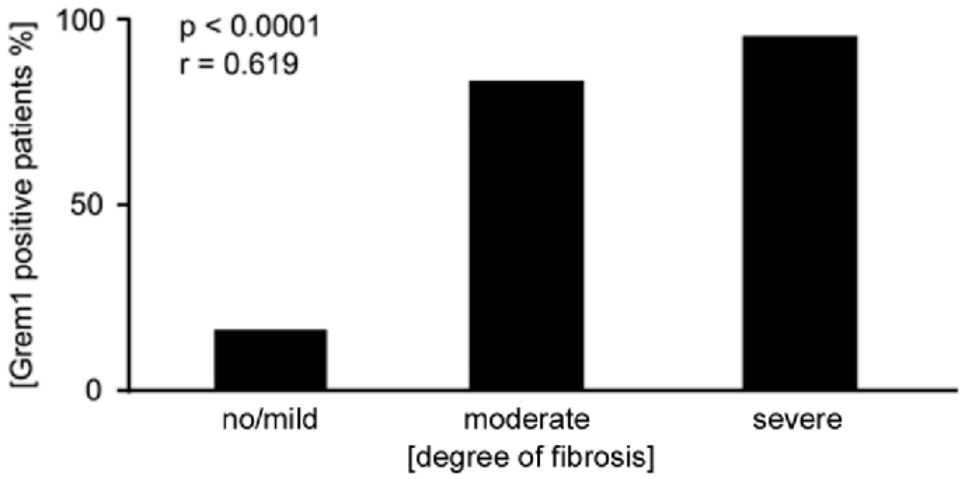

Figure 6: Distribution of Grem1 positive and Grem1 negative biopsies in patients with structural myocardial diseases according to the degree of myocardial fibrosis. Grem1 expression was significantly enhanced in patients with moderate and severe fibrosis in comparison to the patients with no/mild fibrosis. (Spearman correlation coefficient r=0.619, p<0.0001).

3.3 Association of endomyocardial expression of Gremlin-1 with left ventricular dysfunction

We also analyzed clinical parameters in our patient cohort. Patients with enhanced Grem1 expression revealed a significantly reduced LVEF compared to patients with negative Grem1 staining (Grem1 positive vs Grem1 negative: LVEF 39.4% ± 13.8 vs 48.0% ± 14.5, p = 0.001, Figure 7A), as published in [48]. Furthermore, myocardial Grem1 expression was significantly associated with a higher LVEDD. Patients with positive Grem1 staining were found to have a significantly enlarged ventricle at study entry. (Grem1 positive vs. Grem1 negative: LVEDD 53.1mm ± 10.2 versus 49.8mm ± 9.0, p = 0.03, Figure 7B), as published in [48] .

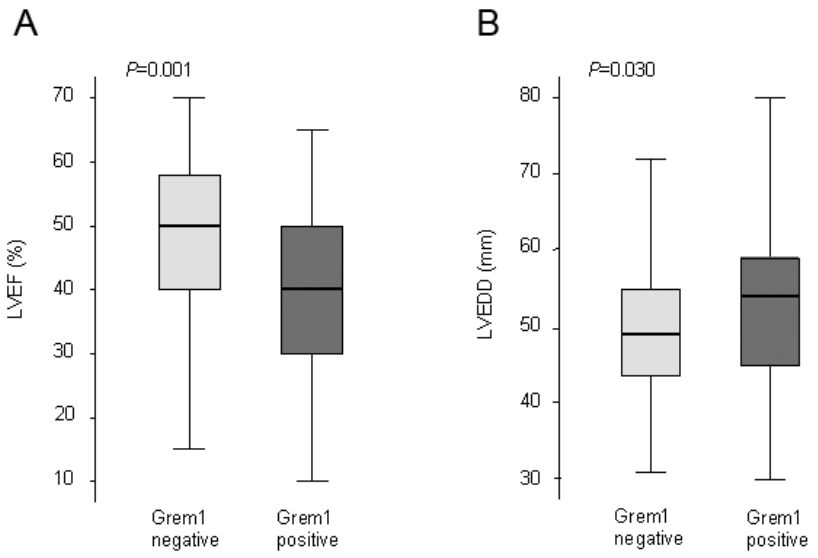

Figure 7: Association of myocardial expression of Grem1 with left ventricular risk markers. (A) LVEF in Grem1 positive patients was significantly reduced compared to Grem1 negative patients (39.4% ± 13.8 vs. 48.0% ± 14.5, p = 0.001). (B) LVEDD was significantly increased in patients with positive Grem1 immunohistochemistry in comparison to patients with Grem1 negative immunohistochemistry (53.1mm ± 10.2 vs. 49.8mm ± 9.0 in Grem1 negative patients, p = 0.03).

3.4 Association of Gremlin-1 expression with poor clinical outcome/ Gremlin-1 as independent predictor of adverse cardiac events

During follow-up 33 (15.4%) patients reached the combined end point (table 3). Out of these, 31 (93.9%) patients showed Grem1 positive myocardial staining and only 2 (6.1%) patients were Grem1 negative (p=0.006). 22 (10.3%) patients died. Out of these, 21 (95.4%) patients were Grem1 positive and 1(1.9%) was Grem1 negative (p=0.026). 11 (5.1%) patients were readmitted to the hospital due to heart failure, 10 (90.9%) of them were Grem1 positive (p=0.096), as published in [48].

Table 3. Clinical outcome during follow-up.

	All Patients (n=214)	Grem1 positive (n=160, 74.8%)	Grem1 negative (n=54, 25.2%)	P**
Combined endpoint*	33 (15.4%)	31 (19.4%)	2 (3.7%)	**0.006**
All-cause death	22 (10.3%)	21 (13.1%)	1 (1.9%)	**0.026**
HF-related rehospitalization	11 (5.1%)	10 (6.3%)	1 (1.9%)	0.096

* combination of all-cause death and heart failure-related rehospitalization.
** comparison of Greml1 positive and negative patients, tested by Cox regression analysis.

In Kaplan-Meier (Figure 8) are illustrated the estimates of the occurrence of the composite endpoint in relation to myocardial Grem1 expression. Grem1 expression was significantly related to the clinical outcome (LogRank 10.7, p=0.001). Cumulative 1 year event rate was 13.3% in Grem1 positive vs 0% in Grem1 negative patients, 2 years event rate was 22.5% vs 0%, respectively, and 3 years event rate was 35.6% vs 7.7% (p <0.05 for all), as published in [48]
.

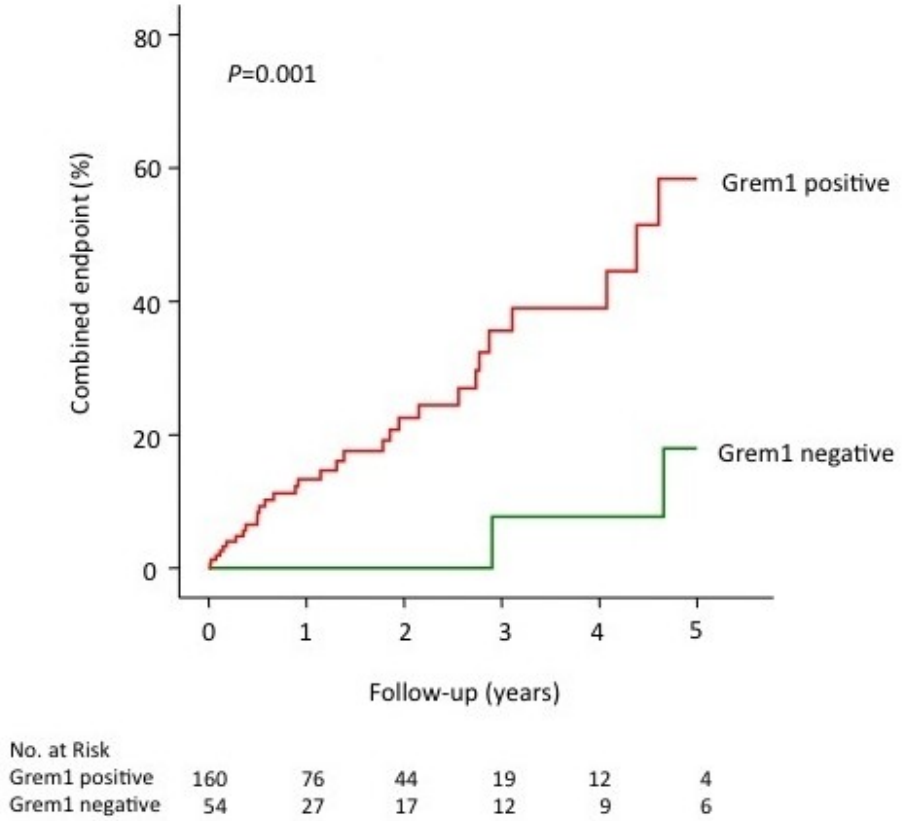

Figure 8: Kaplan-Meier-Curves of occurrence of the composite endpoint (all-cause death and heart failure-related rehospitalization) stratified by Grem1 expression in the myocardium. Myocardial Grem1 expression was significantly related to the composite endpoint (p=0.001) [48].

In univariate analysis, expression of Grem1, expression of myocardial inflammatory markers (CD68, MHCII, and CD3), viral genome, reduced LVEF<40%, LVEDD >53mm, NYHA functional class ≥ II, TnI >0.03 µg/l and BNP >269 ng/l were tested for prediction of the study endpoint (table 4). Among these variables Grem1 expression and NYHA functional class ≥ II were significant predictors of the study endpoint (Hazard ratio (HR); 95% confidence interval (CI): (Grem1: HR 7.9; 95% CI 1.9–33.6; p=0.005; NYHA≥II: HR 2.2; 95% CI 1.1–4.4; p=0.027) [48].

Multivariate analysis revealed that Grem1 expression remained an independent predictor of clinical outcome along with NYHA class ≥ II (Grem1: HR 7.5; 95%

CI 1.8–32.2; p=0.006; NYHA≥II: HR 2.0; 95% CI 1.0–4.1; p=0.048, (table 4), as published in [48].

Furthermore, the degree of myocardial fibrosis was tested as factor for prediction of the study end point. Of note, the degree of fibrosis was in contrast to Grem1 expression not significantly associated with outcome in univariate analysis (HR 1.8; 95% CI 0.8–4.0; p=0.204) [48].

Table 4. Hazard ratios for prediction of combined endpoint [48].

	Univariate Analysis		**Multivariate Analysis**	
Variable	**HR (95% CI)**	**P**	**HR (95% CI)**	**P**
Grem1 positive	7.9 (1.9 - 33.6)	**0.005**	7.5 (1.8 - 32.2)	**0.006**
Inflammatory markers	0.6 (0.3-1.3)	0.239		
Virus positive	0.8 (0.4-1.7)	0.607		
LVEF < 40%	0.9 (0.5 - 1.8)	0.785		
LVEDD > 53mm	1.1 (0.5-2.2)	0.803		
NYHA ≥ II	2.2 (1.1 - 4.4)	**0.027**	2.0 (1.0 - 4.1)	**0.048**
TnI > 0.03µg/l	1.5 (0.8 - 3.14)	0.211		
BNP > 269ng/l	2.4 (0.7 - 8.4)	0.155		

combined endpoint = combination of all-cause death and heart failure-related rehospitalization.
CI – confidence interval, HR- hazard ratio

The sensitivity and specificity of Grem1 expression for prediction of the combined endpoint was calculated with 93.9% and 28.7% respectively. The positive predictive value of Grem1 expression was 19.4%, the negative predictive value was 96.3% [48].

4. Discussion

Therapy and diagnosis of CM are a challenge in modern cardiology. Structural myocardial diseases show a poor prognosis. 80% of cases of SCD in young athletes is caused by either HCM or ARVC [68]. In children with an age below 18 years, the overall incidence of CM is 1.13 cases per 100.000 [4]. According to the report of the AHA (2011 Update) 10 per 1000 population over 65 years of age suffer from a structural myocardial disease. At the same time heart failure is mentioned on one in 9 death certificates in USA in 2011 [4].

One of the main causes leading to congestive or acute heart failure in CM is the process of cardiac remodeling of the heart muscle. Transformation of the structure of one or both ventricles leads to ventricle dysfunction and finally heart failure, life threatening arrhythmias and SCD. The quality of life of patients suffering from structural myocardial diseases gradually deteriorates leading to progressive limitation of everyday life. These patients are treated with long term medication, ICD implantation and in end stage disease with heart transplantation.

As a BMP antagonist Grem1 inhibits BMP induced cell regeneration and apoptosis of myofibroblasts and causes an accumulation of ECM [37]. It also causes an upregulation of the pro- fibrotic TGF-β signaling pathway leading to the conclusion that Grem1 overexpression could be a key player in chronic fibrotic remodeling ultimately causing organ failure [47].

Grem1 plays a crucial part in chronic fibrotic diseases of kidney, lung and liver especially in progressive fibrotic courses of the disease regulating various-signaling pathways of regeneration involving BMPs and TGF-ß. In 2006 Koli et al. established that Grem1 was overexpressed in lung interstitium of patients with IPF [47]. One year later Mezzano et al. demonstrated that Grem1 overexpression was correlated with tubulointerstitial fibrosis. The observed overexpression of Grem1 in tubular and infiltrating interstitial cells indicated that it may play a role in the fibrous process in crescentic nephritis [43]. The results of Boers et al. showed that Grem1 was not present in stellate cells of normal

liver but was strongly induced in activated human stellate cells of fibrotic liver. The enhanced expression of Grem1 in fibrotic liver suggests it as a possible specific marker of liver fibrosis [44]. However, Grem1 has not been described in structural myocardial diseases involving fibrotic remodeling so far.

Since Grem1 is a BMP antagonist that plays a role in chronic fibrotic process in lungs, kidneys and liver and since myocardial fibrosis is a key step in the pathophysiology of myocardial remodeling, we hypothesized that the expression of Grem1 may play a role in CM and might have a predictive value in the diagnostic workup of patients with structural myocardial disease.

The major findings of the present study are:

i) Grem1 is highly expressed in the myocardium of patients with structural myocardial disease and correlates with fibrosis and impaired left ventricular function.

ii) Grem1 expression in tissue derived from endomyocardial biopsies is an independent predictor of poor clinical outcome in patients with structural myocardial disease.

These findings are the first to show that Grem1 might play a pathophysiological role in ventricular remodeling and may be a useful biomarker to evaluate disease progression.

In the present study we were able to show for the first time that Grem1 is expressed in mouse embryonic cardiomyocytes as well as in a high percentage (74.8%) of human endomyocardial biopsies of unselected patients with structural myocardial disease.

The level of Grem1 expression significantly correlated with the degree of myocardial fibrosis. Our results suggest that in patients with enhanced myocardial fibrosis protein expression of Grem1 is significantly increased compared to patients with no or mild fibrosis. Therefore it may be tempting to speculate that the expression of Grem1 is only reflecting the presence of fibrosis. However, the expression of Grem1 in the myocardium was an

independent predictor of the combined endpoint whereas the degree of fibrosis was not significantly related to the outcome of the patients [48].

Patients who were Grem1 positive had a more severe left ventricular dysfunction. This was clinically expressed by a lower LVEF and a higher LVEDD. Therefore, we assume that Grem1 may play a role in the pathophysiological procedure of ventricular remodeling of structural myocardial disease.

Apart from Grem1 expression, univariate analysis was also performed in seven other factors (inflammatory markers, viral genome, LVEF <40%, LVEDD >53mm, NYHA ≥ II, TnI >0.03 µg/l, and BNP >269 ng/l) connected with the severity of CM and fibrosis in order to ascertain their respective prognostic value.

In contrast to previous findings [57], immunohistological detection of inflammation (CD3, CD68, MHC class II molecules) did not allow the prediction of adverse events in our cohort (p=0.239), which might reflect the differing patient selection criteria in our study that consecutively enrolled various entities of structural myocardial diseases [48].

The diagnostic and prognostic relevance of the detection of viral genome remains a matter of debate [54, 57]. In our patient cohort, approximately one third of endomyocardial biopsies were virus positive. However, virus genome detection was not predictive for the occurrence of clinical events during the time of follow-up (p=0.607) [48].

Established clinical risk markers were also evaluated in our patient cohort. Increased LVEDD is a parameter of systolic LV dysfunction and is shown to be increased in DCM. BNP is a proven, highly sensitive marker for heart failure [69] as it is secreted when myocytes are excessively stretched. LVEDD >53mm (p=0.803) and BNP>269 ng/l (p=0.155) were not found to have a significant correlation with the study end point.

One explanation, why BNP is not a predictor of clinical outcome in our cohort may be due to the design of our study, as our cohort included patients with

structural myocardial disease (including e.g. HOCM, HNCM, secondary CM due to amyloidosis) and not necessarily patients with heart failure where BNP is a well-known predictor of outcome. A significant proportion of patients in our study had normal LVEF. Hence, values of BNP widely differed between our patients and that might explain why BNP is not an independent predictor of outcome in our cohort. The lack of correlation between BNP and outcome could even strengthen the importance of Grem1 as a prognostic biomarker. As Grem1 expression showed a correlation with outcome but BNP didn't it can be speculated that Grem1 could be used to detect cardiomyopathies at an early stage, possibly early enough to control its severity by treatment.

Advanced NYHA functional class is a clinical sign of heart failure, representing patients with a slight or marked limitation of physical activity. NYHA ≥ II was an independent predictor of study end point (p=0.027). An elevated level of TnI is a marker of myocardial necrosis and heart failure. TnI > 0.03µg/l was not found to be significantly correlated with the study endpoint (p=0.211) [70-72].

Although decreased systolic LVEF is a significant standard parameter of systolic dysfunction, LVEF< 40% appeared to be not of predictive value in our cohort (p=0.785). This may be due to our study design that included consecutive patients with structural myocardial disease who did not necessarily have decreased LVEF (e.g. patients with HNCM, HOCM, RCM, ARVC/D or storage disease).

Furthermore, we assessed the predictive value of cardiac fibrosis for the study end point. Of note, the degree of fibrosis was in contrast to Grem1 expression not significantly associated with outcome in univariate analysis (HR 1.8; 95% CI 0.8–4.0; p=0.204). In conclusion, although expression of fibrosis and expression of Grem1 was highly correlated, fibrosis was no predictor of outcome in our patient cohort in contrast to Grem1. Therefore, the evidence of a Grem1 positive biopsy may comprise more prognostic information beyond that of the degree of fibrosis within the myocardium.

While the sensitivity of Grem1 (93.9%) for the prediction of adverse clinical events was high, the specificity (28.7%) and positive predictive value (19.4%) were quite low [48]. This might be due to the fact that 74.8% of patients were Grem1 positive. Nevertheless, the negative predictive value was high (96.3%) for the prediction of combined endpoint [48]. The fact that patients with no or low Grem1 expression showed an excellent prognosis in the long-term follow-up indicates that Grem1 is involved in pathophysiological mechanisms of myocardial remodeling in patients with structural myocardial disease.

Therefore we draw the conclusion that especially the absence of Grem1 has clinical implications as these patients have a far better outcome compared to Grem1 positive patients. These results could lead to an improvement of risk stratification and better treatment options at an early stage of the disease, as the absence of Grem1 expression may help to identify patients at low risk for adverse clinical events in contrast to patients with Grem1 who benefit from an intensified monitoring. These new findings are of importance in cardiovascular research, as we demonstrate that Grem1 could be used as a novel diagnostic and prognostic marker of myocardial disease.

Furthermore, Grem1 could be examined as a possible serum biomarker for the non-invasive assessment of myocardial fibrosis. Common serum biomarkers like PINP, PIIINP, PICP, ICTP are currently used in clinical routine and it is speculated that they may reflect collagen synthesis or degradation in the myocardium of heart failure patients. The unreliability of these markers makes the non-invasive assessment of fibrosis problematic at the moment [72]. Mechanistic studies should be performed to further evaluate not only the impact of Grem1 as serum biomarker in the non-invasive assessment of myocardial fibrosis but also the prediction of adverse outcome in patients with structural myocardial disease.

Our study may also open the way for the development of new therapeutic strategies to control and prevent inflammatory heart diseases involving remodeling mechanisms such as heart failure, one major challenge for the western medicine in the future.

5. Summary

Gremlin-1 (Grem1), an antagonist of bone morphogenetic proteins, is involved in fibrotic tissue formation in kidney, lung and liver. The impact of myocardial Grem1 expression is unknown. Therefore, we investigated the diagnostic and prognostic value of Grem1 in structural myocardial diseases.

214 patients with structural myocardial diseases consecutively underwent endomyocardial biopsy. Standard histopathology, Grem1 expression and degree of myocardial fibrosis (no/mild, moderate, severe) were assessed with immunohistology. Prognostic risk factors included markers for immuno-histological detection of inflammation (CD3, CD68, MHC class II molecules), viral genome, LVEF, LVEDD, NYHA functional class, TnI and BNP. The study endpoint was defined as a combination of death of all causes or heart failure-related re-hospitalization within a follow-up period of 3 years.

Grem1 expression correlated significantly with the degree of myocardial fibrosis (Spearman correlation coefficient r = 0.619, p<0.0001). There was no significantly enhanced Grem1 expression in patients with only mild fibrosis whereas biopsies of patients with moderate to severe fibrosis showed a moderately to strongly enhanced Grem1 expression. Grem1 positive patients showed an impaired LVEF (39.4±13.8% vs. 48.0±14.5%, p=0.001) and a larger LVEDD (53.1±10.2mm vs. 49.8± 9.0mm, p=0.03). During follow-up 33 (15.4%) patients reached the combined endpoint. In multivariate analysis, Grem1 expression and NYHA≥II were independent predictors of the study endpoint (Grem1: Hazard ratio (HR) 7.5; 95% confidence interval (CI) 1.8–32.2, p=0.006; NYHA≥II: HR 2.0; 95% CI 1.0–4.1, p=0.048). In contrast to Grem1 expression, the degree of myocardial fibrosis was not significantly associated with outcome in univariate analysis (HR 1.8, 95% CI 0.8-4.0; p=0.204).

Therefore, Grem1 is an independent predictor of adverse outcome in patients with structural myocardial disease and may serve as new immunohistochemical biomarker.

6. Zusammenfassung

Gremlin-1 (Grem1) ist ein BMP-Antagonist, der bei fibrotischen Umbauprozessen der Niere, Lunge und Leber eine Rolle spielt. Der Einfluss der Grem1-Expression auf das Myokard ist derzeit nicht bekannt. Deswegen wurde in der vorliegenden Studie die diagnostische und prognostische Rolle von Grem1 in der strukturellen Herzerkrankung untersucht.

Bei 214 Patienten mit struktureller Herzerkrankung wurden Myokardbiopsien entnommen. Histopathologische Standarduntersuchung, die Grem1-Expression und der Grad der Fibrose im Herzmuskel wurden mittels Immunhistochemie analysiert. Zu den untersuchten prognostischen Risikofaktoren zählten Marker zur immunhistologischen Detektion von Inflammation (CD3, CD68, MHC-II), Detektion viraler Genome, die linksventrikuläre Ejektionsfraktion (LVEF), der linksventrikuläre enddiastolische Durchmesser (LVEDD), die NYHA Klassifikation, Troponin I (TnI) und Brain Natriuretic Peptide (BNP). Der Studien-Endpunkt wurde als Kombination von Tod oder Rehospitalisation aufgrund von Herzinsuffizienz innerhalb eines Nachverfolgungszeitraums von 3 Jahren definiert.

Es zeigte sich eine signifikante Korrelation zwischen dem Grad der Grem1 Expression und dem Grad der Herzmuskelfibrose (Korrelationskoeffizient nach Spearman $r=0.619$, $p<0.0001$). Bei Patienten mit leichter Fibrose gab es keine signifikant erhöhte Expression von Grem1, dagegen fand sich in Biopsien von Patienten mit mittlerer bis schwerer Fibrose eine mittelmäßig bis stark erhöhte Grem1 Expression. Es konnte gezeigt werden, dass eine erhöhte Grem1 Expression mit einer eingeschränkten LVEF (39.4±13.8% vs. 48.0±14.5%, $p=0.001$) und einem vergrößerten LVEDD (53.1±10.2mm vs. 49.8± 9.0mm, $p=0.03$) signifikant korrelierte. Während der Nachverfolgungszeit erreichten 33 (15.4%) Patienten den kombinierten Endpunkt. In multivariablen Analyse erwiesen sich die Grem1 Expression und eine NYHA-Klasse ≥II als unabhängige prognostischen Faktoren für das Erreichen des Endpunktes (Grem1: Hazard ratio (HR) 7.5; 95% confidence interval (CI) 1.8–32.2, $p=0.006$;

NYHA≥II: HR 2.0; 95% CI 1.0–4.1, p=0.048). Im Gegensatz zur Grem1-Expression war der Grad der myokardialen Fibrose in einer univariaten Analyse nicht signifikant mit dem Ausgang assoziiert. (HR 1.8, 95% CI 0.8-4.0; p=0.204).

Daher kann Grem1 als neuer unabhängiger prognostischer Biomarker für das Auftreten kardiovaskulärer Ereignisse bei Patienten mit struktureller Herzmuskelerkrankung dienen und in die immunhistologischen Routine-untersuchungen von Myokardbiopsien Einlass finden.

7. Contributions

Parts of this dissertation were published in the following publication:

"Gremlin-1 identifies fibrosis and predicts adverse outcome in patients with heart failure undergoing endomyocardial biopsy", Mueller KA, Tavlaki E, Schneider M, Jorbenadze R, Geisler T, Kandolf R, Gawaz M, Mueller II, Zuern CS, J Card Fail. 2013 Oct;19(10):678-84. doi: 10.1016/j.cardfail.2013.09.001.

Professor Dr. med. Meinrad Gawaz, Professor Dr. med. Tobias Geisler and Dr. med. Karin Mueller und Dr. med. Iris Mueller were involved in the conception of the research.

Histological staining of the myocardial biopsies with HE, Masson's trichrome, Giemsa stainings and also immunohistochemical stainings with antibodies against CD3, CD68, HLA-DR-α and Grem1 were performed by me.

Light microscopy of the stainings and assessment of the grade of fibrosis and Grem1 infiltration of the specimens was assessed by me and Dr. med. Karin Mueller. Part of the follow- up interviews were performed by me.

The statistical analysis of the data was performed by Dr. med. K. Mueller, Dr. med. Christine Zuern and myself.

The data of Figure 5,6,7,8 were collected by Dr. med. K. Mueller and analyzed by me.

The research of literature references, which were also used in the publication was performed by myself. I wrote this dissertation and took part in the conception of its outline.

Nested PCR was carried out at the Institut für Molekulare Pathologie in Tübingen, Germany.

Real time PCR and Western Blot of mouse embryonic cardiomyocyte lysates were performed by Ms Schneider.

Responsible for the proofreading and content validation of this dissertation were Dr. med. K. Mueller and Dr. med. Iris Mueller.

I affirm that I wrote the manuscript by myself under the supervision of Dr. Karin Mueller and Prof. Dr. Tobias Geisler using no other sources than those cited in the manuscript.

Tuebingen, den

Unterschrift

8. Index of abbreviations

ACC	American College of Cardiology
ACE	Angiotensin-converting-enzyme
AHA	American Heart Association
ARVC	Arrhythmic right ventricular cardiomyopathy
ARB	Angiotensin receptor blocker
BMI	Body mass index
BMP	Bone morphogenetic protein
BNP	Brain natriuretic peptide
CD	Cluster of Differentiation
cDNA	Complementary DNA
CI	Confidence interval
CK	Creatine kinase
CKD	Chronic kidney disease
CM	Cardiomyopathy
CMR	Cardiovascular magnetic resonance
COPD	Chronic obstructive pulmonary disease
coSmad	Common Smad
CRP	C-reactive protein
CypA	Cyclophilin A
CypB	Cyclophilin B
DCM	Dilated cardiomyopathy
DNA	Deoxyribonucleic acid
dNTPs	Deoxynucleoside Triphosphates
dsDNA	Double strands DNA
ECM	Extracellular matrix
EMMPRIN	Extracellular Matrix Metalloproteinase inducer
EMT	Epithelial to mesenchymal transition
ESC	European Society of Cardiology
GAPDH	Glyceraldehyde 3-phosphate dehydrogenase
Grem1	Gremlin-1
HCM	Hypertrophic cardiomyopathy
HCV	Hepatitis C Virus
HE	Haematoxylin and Eosin
HF	Heart failure
HNCM	Hypertrophic non-obstructive cardiomyopathy
HOCM	Hypertrophic obstructive cardiomyopathy
HR	Hazard ratio
HSC	Hepatic stellate cells
HTX	Heart transplantation
ICD	Implantable cardioverter defibrillator
ICTP	C-terminal telopeptide of collagen I
iDCM	Inflammatory dilative cardiomyopathy
IGF	Insulin-like growth factor
IL	Interleukin
IPF	Idiopathic pulmonary fibrosis

LGE	Late gadolinium enhancement
LV	Left ventricle
LVEDD	Left ventricular enddiastolic diameter
LVEF	Left ventricular ejection fraction
MHC-II	Major Histocompatibility Complex
MMP	Matrix metalloproteinase
NCCM	Non compaction cardiomyopathy
NSVT	Non-sustained ventricular tachycardia
NYHA	New York Heart Association
NPV	Negative predictive value
PBS	Phosphate buffered saline
PCR	polymerase chain reaction
PDGF	Platelet derived growth factor
PICP	C-terminal propeptide of collagen type I
PINP	N-terminal peptide of collagen type I
PIIINP	N-terminal peptide of collagen type III
PPV	Positive predictive value
PVDF	Polyvinylidene difluoride
qRT-PCR	Real-Time-quantitative PCR
RCM	Restrictive cardiomyopathy
ROS	Reactive oxygen species
R-Smad	Receptor- associated Smad
RV	Right ventricle
RVOT	Right ventricular outflow tract
SDS-PAGE	Sodiumdodecylsulfate polyacrylamide gel electrophoresis
SCD	Sudden cardiac death
Smad	Small tail and mothers against decapentaplegic
TGFβ1	Transforming growth factor beta1
TIMP	Tissue inhibitor of metalloproteinases
TNF	Tumor necrosis factor
TnI	Troponin I
VT	Ventricular tachycardia
VF	Ventricular fibrillation
WB	Western blot

9. Index of tables

Page

Table 1: Baseline characteristics of the patient population 40

Table 2: Classification of cardiomyopathies according to clinical and histological criteria 42

Table 3: Clinical outcome during follow-up 48

Table 4: Hazard ratios for prediction of combined endpoint 50

10. Index of figures

Page

Figure 1: Grem1 antagonism in vascular cells 18

Figure 2: The process of EMT 19

Figure 3: Contribution of excessive Grem1 expression to cellular changes in the lung 20

Figure 4: Protein expression of Grem1 in mouse embryonic cardio-myocytes (HL-1 cells) detected by immunoblotting and qPCR 44

Figure 5: Immunohistochemistry detecting Grem1 expression in human myocardial tissue sections of patients with structural myocardial diseases 45

Figure 6: Distribution of Grem1 positive and Grem1 negative biopsies in patients with structural myocardial diseases according to the degree of myocardial fibrosis 46

Figure 7: Association of myocardial expression of Grem1 with left ventricular risk markers 47

Figure 8: Kaplan-Meier-Curves of occurrence of the composite endpoint stratified by Grem1 expression in the myocardium 49

11. Index of references

1. Maron, B.J., et al., *Contemporary definitions and classification of the cardiomyopathies: an American Heart Association Scientific Statement from the Council on Clinical Cardiology, Heart Failure and Transplantation Committee; Quality of Care and Outcomes Research and Functional Genomics and Translational Biology Interdisciplinary Working Groups; and Council on Epidemiology and Prevention.* Circulation, 2006. **113**(14): p. 1807-16.

2. Warner Stevenson, L. and J. Loscalzo, *Cardiomyopathy and Myocarditis*, in *Harrison's Principles of Internal Medicine*, A.S.F. Dan L. Longo, Dennis L. Kasper, Stephen L. Hauser, J. Larry Jameson, Joseph Loscalzo, Editor. 2011, Mcgraw-Hill Professional.

3. Felker, G.M., et al., *Underlying causes and long-term survival in patients with initially unexplained cardiomyopathy.* N Engl J Med, 2000. **342**(15): p. 1077-84.

4. Roger, V.L., et al., *Heart disease and stroke statistics--2011 update: a report from the American Heart Association.* Circulation, 2011. **123**(4): p. e18-e209.

5. Wilson, J.R., et al., *Prognosis in severe heart failure: relation to hemodynamic measurements and ventricular ectopic activity.* J Am Coll Cardiol, 1983. **2**(3): p. 403-10.

6. Massie, B.M. and M. Conway, *Survival of patients with congestive heart failure: past, present, and future prospects.* Circulation, 1987. **75**(5 Pt 2): p. IV11-9.

7. Massie, B., et al., *Long-term vasodilator therapy for heart failure: clinical response and its relationship to hemodynamic measurements.* Circulation, 1981. **63**(2): p. 269-78.

8. Califf, R., *The prognosis in the presence of coronary artery disease*, in *Congestive heart failure : current research and clinical applications*, M.B.M. Eugene Braunwald, John T. Watson, Editor. 1982, Grune & Stratton: New York.

9. Cohn, J.N., et al., *Effect of vasodilator therapy on mortality in chronic congestive heart failure. Results of a Veterans Administration Cooperative Study.* N Engl J Med, 1986. **314**(24): p. 1547-52.

10. Unverferth, D.V., et al., *Factors influencing the one-year mortality of dilated cardiomyopathy.* Am J Cardiol, 1984. **54**(1): p. 147-52.

11. Schwarz, F., et al., *Determinants of survival in patients with congestive cardiomyopathy: quantitative morphologic findings and left ventricular hemodynamics.* Circulation, 1984. **70**(6): p. 923-8.

12. Polak, J.F., et al., *Right ventricular ejection fraction: an indicator of increased mortality in patients with congestive heart failure associated with coronary artery disease.* J Am Coll Cardiol, 1983. **2**(2): p. 217-24.

13. Cheng, S. and R.S. Vasan, *Advances in the epidemiology of heart failure and left ventricular remodeling.* Circulation, 2011. **124**(20): p. e516-9.

14. Elliott, P., et al., *Classification of the cardiomyopathies: a position statement from the European Society Of Cardiology Working Group on Myocardial and Pericardial Diseases.* Eur Heart J, 2008. **29**(2): p. 270-6.

15. Jefferies, J.L. and J.A. Towbin, *Dilated cardiomyopathy.* Lancet, 2010. **375**(9716): p. 752-62.

16. Maron, B.J., *Hypertrophic cardiomyopathy: a systematic review.* JAMA, 2002. **287**(10): p. 1308-20.

17. Noureldin, R.A., et al., *The diagnosis of hypertrophic cardiomyopathy by cardiovascular magnetic resonance.* J Cardiovasc Magn Reson, 2012. **14**: p. 17.

18. Gregoratos, G., et al., *ACC/AHA Guidelines for Implantation of Cardiac Pacemakers and Antiarrhythmia Devices: Executive Summary--a report of the American College of Cardiology/American Heart Association Task Force on Practice Guidelines (Committee on Pacemaker Implantation).* Circulation, 1998. **97**(13): p. 1325-35.

19. Priori, S.G., et al., *Task Force on Sudden Cardiac Death of the European Society of Cardiology.* Eur Heart J, 2001. **22**(16): p. 1374-450.

20. Jain, A., et al., *Role of cardiovascular magnetic resonance imaging in arrhythmogenic right ventricular dysplasia.* J Cardiovasc Magn Reson, 2008. **10**: p. 32.

21. Corrado, D. and G. Thiene, *Arrhythmogenic right ventricular cardiomyopathy/dysplasia: clinical impact of molecular genetic studies.* Circulation, 2006. **113**(13): p. 1634-7.

22. Fontaine, G. and C. Prost-Squarcioni, *Implantable cardioverter defibrillator in arrhythmogenic right ventricular cardiomyopathies.* Circulation, 2004. **109**(12): p. 1445-7.

23. Weiford, B.C., V.D. Subbarao, and K.M. Mulhern, *Noncompaction of the ventricular myocardium.* Circulation, 2004. **109**(24): p. 2965-71.

24. Chang, N.-C. and S. Kawai, *Takotsubo cardiomyopathy is not rare in Taiwan.* Acta Cardiologica Sinica, 2009(25): p. 3.

25. Paulus, W.J., *Cytokines and heart failure.* Heart Fail Monit, 2000. **1**(2): p. 50-6.

26. Satoh, M., et al., *Immune modulation: role of the inflammatory cytokine cascade in the failing human heart.* Curr Heart Fail Rep, 2008. **5**(2): p. 69-74.

27. Li, Y.Y., C.F. McTiernan, and A.M. Feldman, *Interplay of matrix metalloproteinases, tissue inhibitors of metalloproteinases and their regulators in cardiac matrix remodeling.* Cardiovasc Res, 2000. **46**(2): p. 214-24.

28. Taipale, J. and J. Keski-Oja, *Growth factors in the extracellular matrix.* FASEB J, 1997. **11**(1): p. 51-9.

29. Sawyer, D.B., et al., *Role of oxidative stress in myocardial hypertrophy and failure.* J Mol Cell Cardiol, 2002. **34**(4): p. 379-88.

30. Seizer, P., et al., *Cyclophilin A affects inflammation, virus elimination and myocardial fibrosis in coxsackievirus B3-induced myocarditis.* J Mol Cell Cardiol, 2012. **53**(1): p. 6-14.

31. Zuern, C.S., et al., *Cyclophilin A predicts clinical outcome in patients with congestive heart failure undergoing endomyocardial biopsy.* Eur J Heart Fail, 2013. **15**(2): p. 176-84.

32. Seizer, P., et al., *EMMPRIN and its ligand Cyclophilin A as novel diagnostic markers in inflammatory cardiomyopathy.* Int J Cardiol, 2013. **163**(3): p. 299-304.

33. Hengstenberg, C., et al., *De novo expression of MHC class I and class II antigens on endomyocardial biopsies from patients with inflammatory heart disease and rejection following heart transplantation.* Eur Heart J, 1993. **14**(6): p. 758-63.

34. Topol, L.Z., et al., *Biosynthesis, post-translation modification, and functional characterization of Drm/Gremlin.* J Biol Chem, 2000. **275**(12): p. 8785-93.

35. Topol, L.Z., et al., *Identification of drm, a novel gene whose expression is suppressed in transformed cells and which can inhibit growth of normal but not transformed cells in culture.* Mol Cell Biol, 1997. **17**(8): p. 4801-10.

36. Hsu, D.R., et al., *The Xenopus dorsalizing factor Gremlin identifies a novel family of secreted proteins that antagonize BMP activities.* Mol Cell, 1998. **1**(5): p. 673-83.

37. Costello, C.M., et al., *Role of gremlin in the lung: development and disease.* Am J Respir Cell Mol Biol, 2010. **42**(5): p. 517-23.

38. Kami, D., et al., *Gremlin enhances the determined path to cardiomyogenesis.* PLoS One, 2008. **3**(6): p. e2407.

39. Mitola, S., et al., *Angiopoietin-1 mediates the proangiogenic activity of the bone morphogenic protein antagonist Drm.* Blood, 2008. **112**(4): p. 1154-7.

40. Chen, B., et al., *Cutting edge: bone morphogenetic protein antagonists Drm/Gremlin and Dan interact with Slits and act as negative regulators of monocyte chemotaxis.* J Immunol, 2004. **173**(10): p. 5914-7.

41. Stabile, H., et al., *Bone morphogenic protein antagonist Drm/gremlin is a novel proangiogenic factor.* Blood, 2007. **109**(5): p. 1834-40.

42. Roxburgh, S.A., et al., *Recapitulation of embryological programmes in renal fibrosis--the importance of epithelial cell plasticity and developmental genes.* Nephron Physiol, 2006. **103**(3): p. p139-48.

43. Mezzano, S., et al., *Expression of gremlin, a bone morphogenetic protein antagonist, in glomerular crescents of pauci-immune glomerulonephritis.* Nephrol Dial Transplant, 2007. **22**(7): p. 1882-90.

44. Boers, W., et al., *Transcriptional profiling reveals novel markers of liver fibrogenesis: gremlin and insulin-like growth factor-binding proteins.* J Biol Chem, 2006. **281**(24): p. 16289-95.

45. Rider, C.C. and B. Mulloy, *Bone morphogenetic protein and growth differentiation factor cytokine families and their protein antagonists.* Biochem J, 2010. **429**(1): p. 1-12.

46. Kalluri, R. and R.A. Weinberg, *The basics of epithelial-mesenchymal transition.* J Clin Invest, 2009. **119**(6): p. 1420-8.

47. Koli, K., et al., *Bone morphogenetic protein-4 inhibitor gremlin is overexpressed in idiopathic pulmonary fibrosis.* Am J Pathol, 2006. **169**(1): p. 61-71.

48. Mueller, K.A., et al., *Gremlin-1 identifies fibrosis and predicts adverse outcome in patients with heart failure undergoing endomyocardial biopsy.* J Card Fail, 2013. **19**(10): p. 678-84.

49. Veinot, J.P., *Diagnostic endomyocardial biopsy pathology--general biopsy considerations, and its use for myocarditis and cardiomyopathy: a review.* Can J Cardiol, 2002. **18**(1): p. 55-65.

50. Pauschinger, M., et al., *Inflammation, ECG changes and pericardial effusion: whom to biopsy in suspected myocarditis?* Clin Res Cardiol, 2006. **95**(11): p. 569-83.

51. Cooper, L.T., et al., *The role of endomyocardial biopsy in the management of cardiovascular disease: a scientific statement from the American Heart Association, the American College of Cardiology, and the European Society of Cardiology.* Circulation, 2007. **116**(19): p. 2216-33.

52. Grogan, M., et al., *Long-term outcome of patients with biopsy-proved myocarditis: comparison with idiopathic dilated cardiomyopathy.* J Am Coll Cardiol, 1995. **26**(1): p. 80-4.

53. Mahrholdt, H., et al., *Cardiovascular magnetic resonance assessment of human myocarditis: a comparison to histology and molecular pathology.* Circulation, 2004. **109**(10): p. 1250-8.

54. Klingel, K., et al., *Pathogenesis of murine enterovirus myocarditis: virus dissemination and immune cell targets.* J Virol, 1996. **70**(12): p. 8888-95.

55. Veinot, J.P., *Diagnostic endomyocardial biopsy pathology: secondary myocardial diseases and other clinical indications - a review.* Can J Cardiol, 2002. **18**(3): p. 287-96.

56. Frustaci, A., M. Pieroni, and C. Chimenti, *The role of endomyocardial biopsy in the diagnosis of cardiomyopathies.* Ital Heart J, 2002. **3**(6): p. 348-53.

57. Kindermann, I., et al., *Predictors of outcome in patients with suspected myocarditis.* Circulation, 2008. **118**(6): p. 639-48.

58. Arbustini, E., et al., *Ten-year experience with endomyocardial biopsy in myocarditis presenting with congestive heart failure: frequency, pathologic characteristics, treatment and follow-up.* G Ital Cardiol, 1997. **27**(3): p. 209-23.

59. American Heart Association Statistics, C. and S. Stroke Statistics, *American Heart Association. Heart Disease and Stroke Statistics—2003 Update.* 2002.

60. Aretz, H.T., et al., *Myocarditis. A histopathologic definition and classification.* Am J Cardiovasc Pathol, 1987. **1**(1): p. 3-14.

61. Kawai, C., *From myocarditis to cardiomyopathy: mechanisms of inflammation and cell death: learning from the past for the future.* Circulation, 1999. **99**(8): p. 1091-100.

62. Rutschow, S., et al., *Myocardial proteases and matrix remodeling in inflammatory heart disease.* Cardiovasc Res, 2006. **69**(3): p. 646-56.

63. Tanaka, M., et al., *Quantitative analysis of myocardial fibrosis in normals, hypertensive hearts, and hypertrophic cardiomyopathy.* Br Heart J, 1986. **55**(6): p. 575-81.

64. Saiki, R.K., et al., *Primer-directed enzymatic amplification of DNA with a thermostable DNA polymerase.* Science, 1988. **239**(4839): p. 487-91.

65. Smith, L.M., et al., *Fluorescence detection in automated DNA sequence analysis.* Nature, 1986. **321**(6071): p. 674-9.

66. Towbin, H., T. Staehelin, and J. Gordon, *Electrophoretic transfer of proteins from polyacrylamide gels to nitrocellulose sheets: procedure and some applications.* Proc Natl Acad Sci U S A, 1979. **76**(9): p. 4350-4.

67. Laemmli, U.K., *Cleavage of structural proteins during the assembly of the head of bacteriophage T4.* Nature, 1970. **227**(5259): p. 680-5.

68. Firoozi, S., et al., *Sudden death in young athletes: HCM or ARVC?* Cardiovasc Drugs Ther, 2002. **16**(1): p. 11-7.

69. Eindhoven, J.A., et al., *The usefulness of brain natriuretic peptide in complex congenital heart disease: a systematic review.* J Am Coll Cardiol, 2012. **60**(21): p. 2140-9.

70. Holland, R., et al., *Patients' self-assessed functional status in heart failure by New York Heart Association class: a prognostic predictor of hospitalizations, quality of life and death.* J Card Fail, 2010. **16**(2): p. 150-6.

71. Felker, G.M., et al., *Troponin I in acute decompensated heart failure: insights from the ASCEND-HF study.* Eur J Heart Fail, 2012. **14**(11): p. 1257-64.

72. Xue, Y., et al., *Serial changes in high-sensitive troponin I predict outcome in patients with decompensated heart failure.* Eur J Heart Fail, 2011. **13**(1): p. 37-42.

12. Acknowledgement

I want to thank Professor Gawaz for giving me the opportunity to work on this interesting topic in his laboratory.

I'd also like to thank Professor Geisler for being my doctoral thesis supervisor.

Moreover I want to thank Dr. Karin Mueller for her valuable advice, revising this dissertation and the support she offered throughout the writing and the opportunity to take part in her research project as well as Dr. Iris Mueller for revising the manuscript, too.

I also would like to thank Martina Schneider from Gawaz laboratory for the support during the experimental part of this study.

I thank Frederic Emschermann for his valuable advice and his willingness to share his knowledge and experience in biological methods.

Finally I want to thank my parents for continuously supporting me during each and every step of my studies and my decisions. They always gave me courage and contributed to the completion of my goals till now.