

AUS DER UNIVERSITÄTS-HAUTKLINIK TÜBINGEN
Abteilung Dermatologie (Allgemeine Dermatologie mit Poliklinik)

Ärztlicher Direktor: Professor Dr. M. Röcken

**Melanoma of the Ear:
Prognostic Factors and Surgical Strategies**

Inaugural-Dissertation
zur Erlangung des Doktorgrades der Medizin

der Medizinischen Fakultät
der Eberhard-Karls-Universität
zu Tübingen

vorgelegt von

Verena Beate Jahn

aus Hannover

2006

Dekan:	Professor Dr. I. B. Autenrieth
1. Berichterstatter:	Privatdozent Dr. M. Möhrle
2. Berichterstatter:	Professor Dr. M. M. Maassen

Für meine Oma Käthe.

Table of contents

1. Introduction	3
2. Patients and Methods	4
2.1. <i>Patients</i>	4
2.2. <i>Diagnosis and staging</i>	4
2.3. <i>Surgical therapy of primary tumours</i>	4
2.4. <i>Follow-up</i>	5
2.5. <i>Statistical evaluation</i>	5
3. Results	7
3.1. <i>Clinical and histological risk factors</i>	7
3.2. <i>Surgical treatment</i>	7
3.3. <i>Recurrence</i>	8
3.4. <i>Recurrence-free survival</i>	8
3.5. <i>Disease-specific survival</i>	9
3.6. <i>3D-histology (i.e. Micrographic surgery) and LMM</i>	10
3.6.1. <i>Disease-specific survival in LMM</i>	10
3.6.2. <i>Recurrence-free survival in LMM</i>	10
4. Discussion	11
4.1. <i>Clinical and histological risk factors</i>	11
4.2. <i>Surgical treatment</i>	12
4.3. <i>ELND and SLNB</i>	13
4.3.1. <i>Elective lymph node dissection</i>	13
4.3.2. <i>Sentinel lymph node biopsy</i>	14
4.4. <i>Prognosis</i>	15
4.5. <i>Recurrences</i>	15
4.6. <i>Clinical and surgical prognostic factors</i>	16
4.7. <i>3D-histology (i.e. Micrographic surgery) in LMM</i>	17
4.8. <i>Conclusion</i>	18
5. Summary	19

6. Figures and Tables.....	21
<i>Figure 1. Sentinel lymph node biopsy.....</i>	<i>21</i>
<i>Figure 2. Recurrence-free survival/ excision margins</i>	<i>22</i>
<i>Figure 3. Recurrence-free survival/ tumour location</i>	<i>22</i>
<i>Figure 4. Disease-specific survival/ tumour thickness</i>	<i>23</i>
<i>Figure 5. Recurrence-free survival in LMM/ 3D-histology</i>	<i>23</i>
<i>Figure 6. 3D-histology (i.e. Micrographic surgery)</i>	<i>24</i>
<i>Table 1. Excision margins recommended in Tuebingen since 1994.....</i>	<i>25</i>
<i>Table 2. Clinical and surgical parameters of 161 stage I/II patients.....</i>	<i>25</i>
<i>Table 3. Different types of 1st recurrence.....</i>	<i>28</i>
<i>Table 4. Recurrence-free survival in univariate (Kaplan-Meier) and multivariate (Cox-proportional hazard) analysis.....</i>	<i>29</i>
7. References	30
8. Acknowledgements.....	33
9. Curriculum Vitae.....	34

1. Introduction

In 1980 Byers et al. [7] stated: "Because the ear is thin-skinned and has several anatomic subdivisions and multiple areas of lymphatic drainage, a melanoma developing on the ear should perhaps be considered a unique disease. Any correlation between the biological behaviour and certain clinical criteria...may not be significant for the ear."

Few publications exist concerning malignant melanoma of the external ear [1;3;4;7;11;14;26;28;29]. Accordingly, there have been only few case reports concerning surgical strategies and SLNB for melanoma of the ear [6;9;10;15;16;21;26;29;30]. Almost no extensive prospective, randomized studies have been published concerning prognostic factors and surgical strategies [7;26].

For both functional and aesthetic reasons, smaller-than-usual excision margins are commonly used in treating facial melanomas [20]. Unfortunately, no generally accepted recommendations exist regarding excision margins or complete histological monitoring of surgical margins [11;21].

The aim of the present prospective study was to define prognostic factors for melanoma of the ear and to evaluate surgical strategies regarding excision margins, techniques of histological examination, sentinel lymph node biopsy (SLNB), and the prognostic relevance of tissue-conserving procedures.

2. Patients and Methods

2.1. Patients

161 patients (90 male/71 female) with stage I and II melanoma of the external ear were followed up prospectively at our clinic from 3/1976 to 3/2004 (median follow-up: 62 months) and were evaluated in a retrospective manner. Malignant melanomas of the external ear represented 3% of all stage I and II cutaneous melanomas and 20% of stage I and II head and neck melanomas recorded in the Melanoma Registry of the Department of Dermatology at the University of Tuebingen. The patients had given written informed consent to documentation and evaluation of their data stored in the Central Malignant Melanoma Registry of the German Dermatological Society and the Melanoma Registry of the Department of Dermatology at the University of Tuebingen.

2.2. Diagnosis and staging

The diagnosis of invasive (\geq level II) cutaneous melanoma was established by histological evaluation (haematoxylin and eosin, in some cases HMB-45 and/or protein S100 staining as well). Standardised initial clinical and technical examination was performed using chest x-ray, ultrasound of regional lymph nodes, ultrasound and/or computed tomography (CT) scan of the abdomen and, if tumour thickness exceeded 1.50 mm, cerebral CT scan. Sentinel lymph node biopsy (Figure 1) was performed as a standard procedure since October 1996 in the case of tumours thicker than 1.0 mm.

2.3. Surgical therapy of primary tumours

Recommendations for excision margins varied during the observation period and excision margins were reduced successively (Table 1). For both functional

and aesthetic reasons, these recommendations could not always be followed, especially at the ear. The recommended excision margins were 10 - 20 mm for primary nodular melanoma (NM) or superficial spreading melanoma (SSM) and 5 mm with complete three dimensional histology of excision margins (3D-histology) for Lentigo maligna melanoma (LMM) respectively. Micrographic surgery, i.e. 3D-histology, was performed with a rush-fixed paraffin technique [5] in order to reveal subclinical tumour strands. In each case, the minimum excision margins were recorded (cumulatively in the case of multiple-step surgery).

2.4. Follow-up

As recommended by the German Dermatologic Society (DDG) [24], clinical follow-up examinations were scheduled every 3 months for the first five years after the primary excision or the first recurrence and every 6 months for the next 5 years. Technical examinations (chest x-ray, ultrasound of the abdomen and regional lymph nodes) were performed at least once a year. Only those recurrences which occurred in the scar or in the graft of the primary excision were regarded as true local recurrences. True local recurrence means a clinically detectable regrowth of parts of the tumour which had not been completely excised.

The median follow-up was 62 months.

2.5. Statistical evaluation

Statistical evaluation was performed using Version 4.0.2 of the program JMP (<http://www.jmpdiscovery.com/>).

Survival time was computed beginning with the date of the first operation on the primary tumour and ending with the date of death due to melanoma or with the end of the prescribed observation period. Recurrence-free survival was

recorded as the time until first recurrence or until the end of the observation period. Death from other causes than melanoma and survival until the final follow-up examination were calculated as censored events. Survival probability and the probability of recurrence-free survival were calculated using the Kaplan-Meier method. In our analysis we preferred to use ordinal or dichotomized parameters. For age we used the mean (59.19 years) as “breakpoint” to dichotomize.

The prognostic factors were analysed for significance using the logrank test when proportional hazards were present and with the Wilcoxon test when proportional hazards were not present.

Prognostic factors which were significant in univariate analysis were examined using the multivariate Cox proportional hazard model and tested for significance using the likelihood ratio test. Non-significant parameters were eliminated step-by-step. In all tests a p-value of < 0.05 was regarded as statistically significant.

3. Results

3.1. Clinical and histological risk factors

The group studied consisted of 161 patients (stage I/II melanomas) with a median age of 59.9 years (22 - 88 years). The clinical and histological risk factors are summarized in Table 2.

3.2. Surgical treatment

Multiple-step surgery: 76.4% (n = 123) of our patients were treated with multiple-step surgery, for example excisional biopsy followed by definitive surgery with an excision margin or multiple-step 3D-histology (i.e. micrographic surgery) in the case of LMM.

Excision margins ranged from 2.0 mm to 31.0 mm (median: 11 mm, mean: 12.61 mm).

3D-histology: Thirty-nine melanomas (24.2%) of all histological types were removed with 3D-histology. 3D-histology with reduced initial excision margins was used for 22 of 42 patients with LMM.

Elective lymph node dissection (ELND) was performed in 5.6% (n = 9) of our patients from 4/1979 to 11/1991 (results: 1 positive, 8 negative).

Sentinel lymph node biopsy (SLNB) was performed on 18.0% (n = 29) of the patients from 10/1996 to 3/2004 (Figure 1). Results were positive in 2 of the 29 SLNBs (6.9%).

Defect reconstruction: Precise data about defect reconstruction were documented in 146 subjects: locoregional flaps (e.g. advancement/ rotational/ transpositional/ pedicle flaps) were created in 34.2% (n = 50) of these patients,

split skin grafts in 20.5% (n = 30), primary closure in 17.8% (n = 26), wedge excision in 5.5% (n = 8). Partial auricectomy or a combination of methods was performed in 5.5% (n = 8), full skin graft in 4.8% (n = 7), total auricectomy in 4.1% (n = 6) and excision with healing by secondary intention happened in 2.1% (n = 3).

3.3. Recurrence

Recurrences appeared in 38 patients (23.6%) during the observation period. These are summarized in Table 3 and were mostly local recurrences (8.7%) or regional LN-metastases (6.2%) as a first progression of the disease. Satellite-/in-transit-metastases (3.7%) appeared more often in conjunction with initial distant metastases (5.0%) or local recurrences (n.s.).

In particular, preauricular lesions tended to recur. Nine of 19 preauricular lesions developed recurrences, 4 of these with additional distant metastases. In all, 23 (14.3%) patients developed distant metastases during the course of their follow-up.

There were 6 prerregional recurrences after negative SLNB and 1 after positive SLNB, but none of the patients died of melanoma-related causes after SLNB during the observation period.

3.4. Recurrence-free survival

The estimated recurrence-free survival rate was 83% over 3 years and 79% over 5 years.

The following factors were not significant for recurrence-free survival: gender (p = 0.64), ulceration (present vs. absent, p = 0.50), 3D-histology (p = 0.26), and one step versus multiple-step surgery (p = 0.58).

The following risk factors were significantly correlated with recurrence-free survival in univariate analysis: histological tumour type (SSM, LMM, NM, others, $p < 0.0001$), level of invasion (Level II, Level III, \geq Level IV, $p < 0.0001$), tumour thickness (≤ 1.00 mm; 1.01-2.00 mm; > 2.0 mm, $p < 0.0001$), excision margins (≤ 5 mm, 6 - 10 mm, 11 - 15 mm, > 15 mm, $p = 0.035$) (Figure 2), tumour location (front of the ear, preauricular, back of the ear, $p = 0.002$) (Figure 3). Additionally, age was a statistically significant predictor (≤ 59.19 versus > 59.19 years, mean: 59.19 years) ($p = 0.006$). Patients younger than 59 years tended to stay free of recurrence for a longer period of time. These factors were evaluated in a Cox-proportional hazard model with step-by-step elimination of non-significant parameters.

Tumour thickness (≤ 1.00 mm; 1.01-2.00 mm; > 2.0 mm, $p < 0.0001$), tumour location (front of the ear, preauricular, back of the ear, $p = 0.011$), and the extent of the excision margins (≤ 5 mm, 6 - 10 mm, 11 - 15 mm, > 15 mm, $p = 0.049$) were independent risk factors for recurrence-free survival in multivariate analysis (Cox-proportional hazard model, Table 4).

3.5. Disease-specific survival

The prognosis for patients with stage I and II melanoma of the ear was relatively good. Fourteen of the 161 patients eventually died of melanoma-related causes. The survival rate was 98% over 3 years and 96% over 5 years.

The following factors were not significant for disease-specific survival in univariate analysis: gender ($p = 0.75$), age (≤ 59.19 versus > 59.19 years, mean 59.19 years, $p = 0.13$), ulceration (present vs. absent, $p = 0.60$), one step vs. multiple-step surgery ($p = 0.66$) and the extend of excision margins (≤ 5 mm, 6 - 10 mm, 11 - 15 mm, > 15 mm, $p = 0.95$).

Tumour thickness and invasion level according to Clark were the only significant risk factors for disease-specific survival in Kaplan-Meier univariate analysis

(respectively: $p = 0.0076$ for thicknesses of ≤ 1.00 mm, 1.01-2.00 mm, and > 2.0 mm, and $p = 0.0082$ for Levels II, III, and IV or more (see Figure 4)).

3.6. 3D-histology (i.e. Micrographic surgery) and LMM

3D-histology with initially smaller excision margins was used to treat 22 of 42 patients with LMM (52.4%).

3.6.1. Disease-specific survival in LMM

Of the 22 LMM patients who underwent micrographic surgery with 3D-histology, 3 died of melanoma-related causes 25, 74 and 93 months after the initial diagnosis of malignant melanoma. In comparison, 2 of 20 patients who underwent surgery with conventional histology died of melanoma-related causes after 64 and 74 months, respectively.

3.6.2. Recurrence-free survival in LMM

Twenty-two of the 42 LMM patients underwent surgery with 3D-histology. Of these, 3 developed recurrences (1 local, 1 regional lymph node, 1 distant). The recurrence-free survival rate remained stable at 90.9% over 3 and 5 years of follow-up. Of the remaining 20 LMM patients who underwent surgery with conventional histology, 5 developed recurrences (1 local, 2 regional lymph node, 2 distant). The recurrence-free survival rate was 90% over 3 years and 80% over 5-years (Figure 5). LMM removed surgically with 3D-histology were thicker (median: 0.93 mm vs. 0.83 mm), but it was possible to use reduced excision margins (median: 5 mm vs. 10 mm) without an increased risk of recurrence.

4. Discussion

Melanoma of the external ear represent 7% to 20% [4;7;20;22;25] for melanoma of the head and neck and only 1% to 4% [3;4;14] for all cutaneous melanomas.

The present group of 161 patients with melanoma of the ear is the largest such group studied so far. Our patients' data were collected prospectively and were evaluated in a retrospective manner. During the study period the standard of care has changed with a tendency to narrower excision margins and since 1994 using 3D-histology. Byers et al. [7] published an extensive study of 102 patients with melanoma of the ear in 1980. In that study, Byers et al. claimed that the localisation of ear melanomas holds particular position. More recent studies [4;11;12;26;30] have involved fewer patients, i.e. 2 to 78, and others have often included melanomas of the ear among melanomas of the head, neck, or face [13;20;23].

Surgical strategies and the prognosis for malignant melanoma of the ear have changed drastically in the past 20 years [1;11;26]. However, there remains little agreement about which treatment should be standard [1;9;11;21;26]. For functional and aesthetical reasons, surgeons are still searching for less invasive but nevertheless safe strategies with reduced excision margins and complete histological visualisation of excision margins (3D-histology, micrographic surgery) [3;17].

4.1. Clinical and histological risk factors

In contrast to our patient group other studies found a male predisposition of 61.5% to 90.5% [1;7;11;12;21;26]. Such differences in gender-specific ratios can be explained by different hair-styles, habits of living and UV-exposure.

Locations of melanomas at the ear were similarly distributed in the present and previous studies, with the most frequent location at the helix and the front of the ear [3;4;7;26].

SSM represented the largest group of histological types, followed by LMM and NM

Median tumour thickness in the present study was 1.08 mm, i.e. less than in most other studies [3;4;7;9;11;12;14;21;26;28].

Patients with invasion level I (in situ melanomas) were excluded from our study. Similarly to the literature invasion levels II and III were found in 36% [28] to 53% [13] and invasion levels IV and V in 40% [4] to 67% of the patients [14].

4.2. Surgical treatment

For functional and aesthetic reasons, the recommended excision margins (Table 1) were often reduced in the present study (median: 11 mm). In general the underlying cartilage was not removed in terms of radical tumour resection. In some instances, for plastic reconstructive reasons, e.g. in wedge excisions, the cartilage was removed. The defects were covered with extended locoregional flaps or primary closure in 52% of our patients; partial auricectomy was used for 5.5%, and total auricectomy for 4.1%. 3D-histology was applied in 24.2% of the cases. Multiple-step surgery (in 76.4%) in general consisted either of excisional biopsy followed by re-excisions with additional excision margins corresponding to the tumour thickness, or of multiple-step surgery for LMM using 3D-histology. According to previous studies, multiple-step surgery with 3D-histology reduces the risk of recurrence of tumours with subclinical horizontal spread in regions where reduced excision margins have been applied for cosmetic and functional reasons [20].

Regarding operative treatment and the radicality of methods, a marked change has occurred in the last 20 years. Pack et al. [25] in 1970 recommended

amputation in general: "...the amputation of the ear with total parotidectomy and radical neck dissection is the most effective plan in every case of melanoma of the ear...". Other authors also took this position [1;29].

Byers [7] first claimed that "treatment less than amputation" is sufficient. 29.4% (n = 30) of his patients underwent partial resection or total and peripheral ablation.

Despite the cosmetic consequences, wide excision margins and less than total amputation were recommended by Hudson et al. [14] for functional reasons, especially for patients wearing spectacles.

Wide local excision and reconstruction with chondrocutaneous flaps or a retroauricular advancement flap has been recommended as a useful technique to provide skin coverage for full-thickness ear defects and to achieve good cosmetic results with minimal distortion of ear shape and contour [6;21].

Median excision margins in the literature were 13.1 mm (median tumour thickness: 1.75 mm) [9], with a mean of 10 mm (n = 6: 0.5 mm, n = 8: 10 mm, n = 6: >10 mm) according to a report by Bono et al. [4].

4.3. ELND and SLNB

4.3.1. Elective lymph node dissection

Elective lymph node dissection (ELND) was performed on 9 (5.6%) of our patients from 1979 to 1991. Three patients developed preregional recurrences after negative ELND, one after positive ELND.

Fisher et al. [13] performed ELND on 11% of patients, Pockaj [26] on 25% (1985 - 2000), and Byers et al. [7] on 29% (1944 -1977). The latter author

suggested that neck dissection should be used only for patients with thick melanomas and Clark level IV or V.

In a study of the Duke University Medical Center, Durham [13], with 82 patients, elective lymph node dissection significantly reduced the incidence of recurrence for patients with head and neck melanoma ($p = 0.002$).

Until now, three prospective multicenter studies [2;8;27] have failed to demonstrate a beneficial effect of ELND on patients with cutaneous melanoma. Therefore there is only limited evidence to support the application of ELND for patients with melanoma of the ear.

4.3.2. Sentinel lymph node biopsy

Sentinel lymph node biopsy (SLNB) was performed on 29 (18.0%) of the patients in this study from 1997 to 2004 (Figure 1). Results were positive in 2 SLNBs (6.9%). No patient died of melanoma-related causes after SLNB. Six prerregional recurrences occurred after negative SLNB and 1 after positive SLNB.

In a study by Cole [9], 9 of 19 patients underwent SLNB, with negative results in all cases. Of these 9, one had a recurrence.

In a case report by Wey et al. [30], 2 patients with malignant melanoma at the helix had SLNB and remained permanently free of recurrences. The first was a primary melanoma with a thickness of 9.0 mm and Clark level III, the second was a 1.5 mm thick melanoma. Lymphatic drainage was preauricular in the first case and postauricular in the second. SLNB was negative in both cases.

Ollila et al. [23] demonstrated that for patients with primary melanoma of the scalp ($n = 19$), auricle ($n = 11$), or face ($n = 9$), sentinel lymphadenectomy could be performed accurately in the parotid region and offered a low-morbidity alternative to routine elective superficial parotidectomy.

Pockaj et al. [26] performed SLNB in 13% (n = 10) of their patients. Within the median follow up of 38 months, there were no LN recurrences after SLNB. The authors concluded that SLNB could be used to identify patients with lymph node metastases who are at high risk of recurrence.

Unfortunately, most studies [9;10;16;23;26] of SLNB for melanoma of the ear have dealt with small numbers of patients. Some head and neck surgeons argue against SLNB in the head and neck region because SLNB scars may complicate further surgical procedures in case of subsequent metastases.

Our results and data from the literature do not permit definitive conclusions regarding a prognostic or even therapeutic impact of SLNB in patients with melanoma of the ear.

4.4. Prognosis

The prognosis for patients with stage I and II melanoma of the ear in the present study was good, with a survival rate of 98% over 3 years and 96% over 5 years. In the literature, the reported 5-year survival rate varies widely, from 31% [28] to 89% [9]. In Fisher's [13] extensive study of 5109 patients with melanomas of the head and neck, all 82 patients with stage II melanoma of the ear died within 10 years. A trend towards better prognosis during recent years is possibly due to early diagnosis of thinner melanomas [3;11]. Mutual neglect by patients and physicians of early diagnosis of ear melanomas is the main factor to blame for advanced melanomas, both on the ear and any other body region. An extensive lay education campaign addressing also barbers and hair-dressers may improve this aspect.

4.5. Recurrences

The patients in this series had fewer recurrences (Table 3) than other groups studied in the literature, where recurrences reported have ranged from 31.3%

[11] to 58% [14], with local recurrences in 8% [7] to 25% [12;14], regional lymph node recurrences in 17% [14] to 42% [13], and distant recurrences in 12.5% [12] to 17% [14].

4.6. Clinical and surgical prognostic factors

In the present study, tumour thickness and the level of invasion were the only significant risk factors for overall survival in univariate analysis. They were not significant in the multivariate analysis.

Tumour thickness, tumour location, and the extent of excision margins (i.e. reduction of excision margins below the recommended guidelines) were independent risk factors for recurrence-free survival in multivariate analysis (Figure 2, 3; Table 4). In particular, preauricular melanomas tended to recur locally. Preauricular lesions had a significantly higher level of invasion but did not differ in other prognostic parameters.

Tumour thickness is often viewed as the most important prognostic factor for melanoma of the ear [3;4;7;9;11-13;26;29]. However, Hudson et al. [14] have called attention to the influence of the invasion level and excision margins for ear melanomas. In their study, 12 patients with primary melanoma of the external ear were treated during a 10-year period. Only two of seven patients with lesions > 2 mm (median 2.1 mm) survived. Six patients underwent wide-ranging excision, and none of them developed local recurrences. However, all 6 patients with wedge excision developed recurrences (3 local). Dost et al. [12] have reported that the extent of the applied resection has only a minor effect on recurrence and survival for this disease.

In the large study of Byers et al. [7], tumour thickness and nodal metastases (42% of patients) were highly significant prognostic factors for survival. These results are similar to a recent study of Pockaj et al. [26], where tumour thickness, lymph node metastases and local recurrence significantly affected

systemic recurrence. Pockaj et al. [26] also wrote that excision margins ≥ 1 cm seemed to result in a lower rate of local recurrence.

Even if the rate of local recurrence may rise because of narrower excision margins, the true local recurrences did not impair the prognosis of melanoma patients [19]. In that recent study [19] on melanomas of all body sites, tumour locality, tumour thickness and the compliance with recommended excision margins were independent risk factors for local recurrences.

In the present study on ear melanomas a univariate analysis of the local-recurrence-free survival (data not shown) showed age, locality, tumour thickness, histological type, level of invasion and excision margins to be significant risk factors for local recurrence.

Of course we should not go back to wide excision margins. The underlying cartilage should not be removed in terms of radical tumour resection, but for the intended plastic reconstructive procedure. Narrower excision margins had an effect on the incidence of local recurrence, but not on other types of recurrence. Excision margins have little impact on disease-specific survival. Local recurrence should be diagnosed early in close follow-up examinations.

4.7. 3D-histology (i.e. Micrographic surgery) in LMM

Twenty-two of 42 LMMs which were operated using 3D-histology (Figure 5, 6) were thicker compared to conventional histology, but it was possible to reduce excision margins without a higher rate of recurrence.

We recommend micrographic surgery, i.e. 3D-histology, principally for LMM [5]. It may also be useful in other types of melanoma [18]. Nevertheless in using 3D-histology, it seems reasonable to await a negative result of histological examination of excision margins before implementing more complex procedures to close a surgical defect on the ear. Multiple-step procedures may achieve better cosmetic results.

4.8. Conclusion

- The 161 patients described here represent the largest group with melanoma of the ear studied so far.
- The overall survival was related only to tumour thickness and the level of invasion (Clark).
- Tumour thickness, tumour location, and the extent of excision margins were the most important prognostic factors for recurrence-free survival.
- Local recurrence was more frequent with smaller excision margins, but there was no effect on the overall survival. Yet, we do not advocate large excision margins or even amputation of the external ear. Local recurrences should be diagnosed in follow-up examinations.
- Smaller excision margins with 3D-histology did not exhibit an increased risk of local recurrence.
- Our results do not permit conclusions regarding the prognostic impact of SLNB for patients with melanoma of the ear.

5. Summary

Background: The ear's specific anatomic and lymphatic characteristics impose special requirements on treatment of melanoma of the ear. The aim of this prospective study was to define prognostic factors for melanoma of the ear and to evaluate surgical strategies for excision margins, histological evaluation, and sentinel lymph node biopsy (SLNB) in order to achieve better cosmetic and functional results.

Patients and methods: 161 patients with stage I/II melanoma of the external ear were treated in our Department of Dermatology from 3/1976 to 3/2004 (median follow-up: 62 months). Malignant melanoma of the external ear represented 3% of the stage I/II cutaneous melanomas and 20% of the stage I/II head and neck melanomas recorded in the Melanoma Registry of the Department of Dermatology at the University of Tuebingen. Twenty of 42 Lentigo maligna melanomas (LMM) underwent conventional histological evaluation, 22 underwent complete histology of three-dimensional excision margins (3D-histology) in paraffin technique, i.e. micrographic surgery. SLNB was performed in 28 patients with melanomas thicker than 1.0 mm. Clinical, histological and surgical risk factors were evaluated by univariate and multivariate analysis.

Results: The median thickness of the tumours in the present study was 1.08 mm (mean: 1.51 mm; range: 0.18 - 8.50 mm), and the median excision margins were 11.0 mm (mean: 12.61 mm; range: 2.0 - 31.0 mm). The 3-year disease-specific survival rate was 98%, and the 3-year recurrence-free survival rate was 83%. Tumour thickness and the invasion level were the only risk factors significant for disease-specific survival. Tumour thickness, location of the tumour, and the extent of excision margins were independently significant risk factors for recurrence-free survival. LMMs removed surgically with accompanying 3D-histology were thicker than those examined by conventional histology (median: 0.93 mm vs. 0.83 mm); The use of surgery with 3D-histology,

i.e. micrographic surgery, made it possible to reduce the safety margins (median: 5 mm vs. 10 mm) without an increased risk of recurrence. Two of 29 SLNBs were positive (6.9%). There were 6 preregional recurrences after negative SLNB and 1 after positive SLNB. None of the patients with a SLNB died of melanoma-related causes during the observation period.

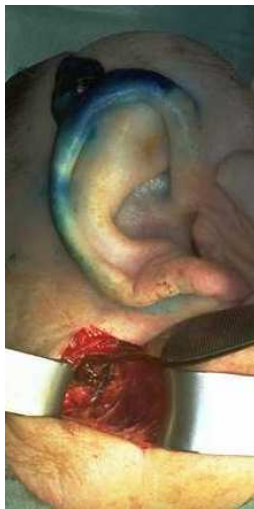Conclusion: This is the largest series of ear melanomas reported so far. The overall survival depended only on the tumour thickness and level of invasion (Clark). Local recurrence was more frequent with smaller excision margins, but this did not influence the overall survival. Smaller excision margins under 3D-histological control did not carry an increased risk of local recurrence. Our results do not permit conclusions regarding the prognostic impact of SLNB for patients with melanoma of the ear.

6. Figures and Tables

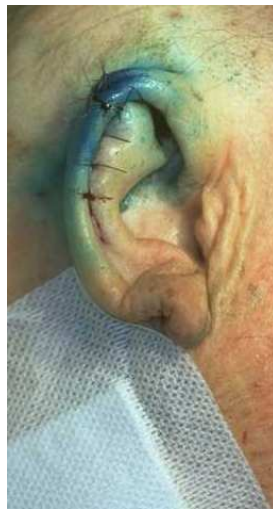Figure 1. *Sentinel lymph node biopsy*

Patient with a nodular melanoma on the right ear and sentinel lymph node biopsy.

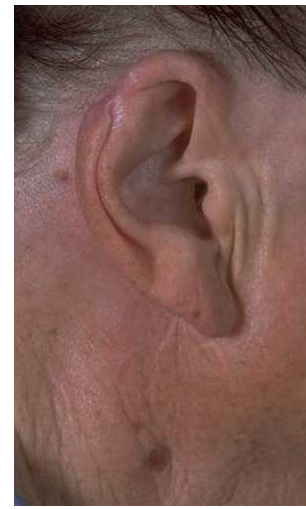- a. Lymphography with peritumoral intradermal injection of blue dye (patent blue V) and SLNB.
- b. Situation directly after excision of the melanoma and closure by a helical rim advancement flap.
- c. Result after 6 months (the patient refused further scar correction).



a.



b.



c.

Figure 2. Recurrence-free survival/ excision margins

Recurrence-free survival in patients with melanoma of the ear (n=161) in relation to excision margins (coloured lines) (p=0.035).

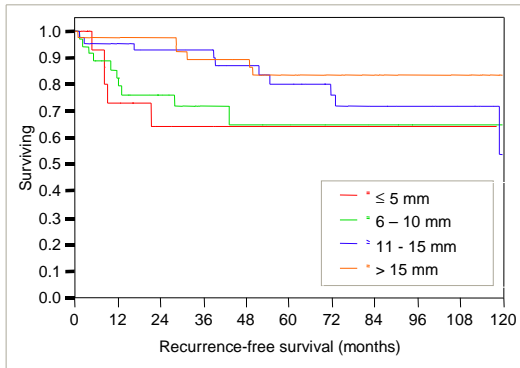


Figure 3. Recurrence-free survival/ tumour location

Recurrence-free survival in patients with melanoma of the ear (n=161) in relation to tumour location (front of the ear, preauricular, back of the ear) (p=0.002).

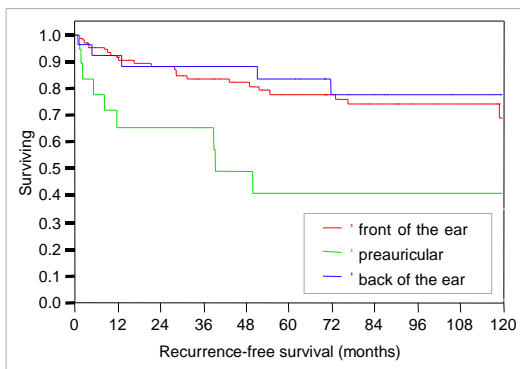


Figure 4. Disease-specific survival/ tumour thickness

Disease-specific survival in patients with melanoma of the ear (n=161) in relation to tumour thickness groups (< 1.00 mm; 1.01-2.00 mm; > 2.00 mm) (p=0.0076).

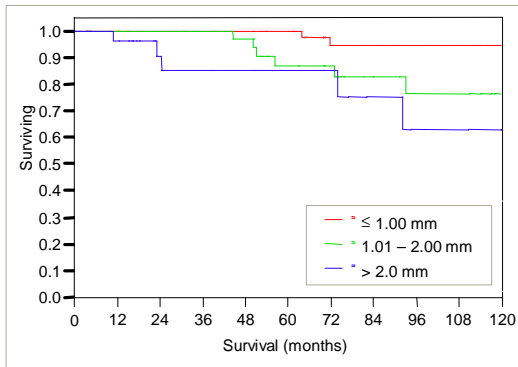


Figure 5. Recurrence-free survival in LMM/ 3D-histology

Recurrence-free survival in patients with LMM melanoma of the ear (n=42) in relation to 3D-histology (n=22) vs. conventional histology (n=20) (p=0.045).

Median tumour thickness 0.93 vs. 0.83 mm.

Median excision margin 5 mm vs. 10 mm.

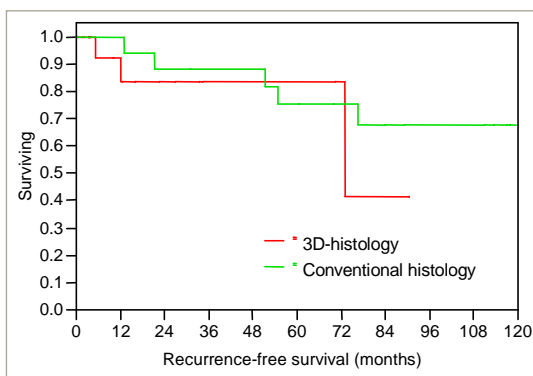


Figure 6. 3D-histology (i.e. Micrographic surgery)

- a. LMM at the right ear of a 67-year-old patient. (tumour thickness 1.20mm, Level IV). Tumour and safety margin are marked on the skin.
- b. Embedding of the tumour margins for 3D-histology.
- c. Preparation of a pedicled flap from the retroauricular region for
- d. reconstruction of the defect on the front of the ear.
- e. Result after dissection of the pedicled flap.

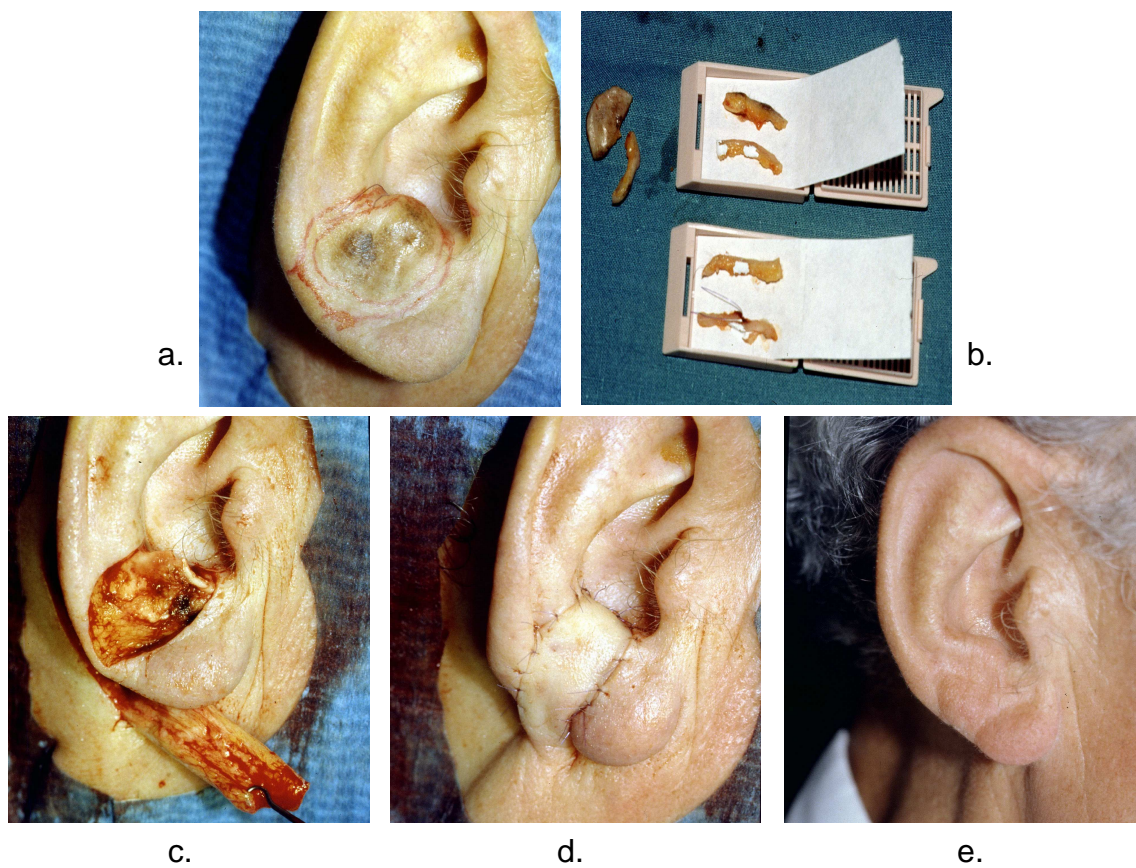


Table 1. Excision margins recommended in Tuebingen since 1994.

Tumour Thickness	Recommendation (Tuebingen 1994)
≤ 1.00 mm	10 mm
> 1.00 mm	20 mm
LMM	5 mm using 3D-histology

Table 2. Clinical and surgical parameters of 161 stage I/II patients.

Variable		n = 161	%
Sex	Male	90	55.9
	Female	71	44.1
Age (years)	Mean	59.19	
	Median	59.90	
	≤ 59.19	83	51.6
	> 59.19	78	48.4
Location	Front of the ear	115	71.4
	Preauricular	19	11.8
	Retroauricular	27	16.8
Tumour thickness (mm)	Unknown	2	
	Mean	1.5	
	Median	1.1	

	≤ 1.00	77	48.4
	1.01 - 2.00	49	30.8
	> 2.00	33	20.8
Histological type	Unknown	2	
	SSM	74	46.5
	NM	35	22.0
	LMM	42	26.4
	Other	8	5.0
Level of invasion	Unknown	4	
	II	31	19.8
	III	52	33.1
	≥ IV	74	47.1
Histological ulceration	Unknown	48	
	Ulceration	14	12.4
	No ulceration	99	87.6
Surgery	One-step	38	23.6
	Multiple-step	123	76.4
Excision margins (mm)	Unknown	17	
	Mean	12.6	
	Median	11.0	
	≤ 5 mm	24	16.7
	6 - 10 mm	37	25.7
	11 - 15 mm	43	29.9

	> 15 mm	40	24.8
3D-histology (Micrographic surgery)	3D-histology	39	24.2
	No 3D-histology	122	75.8
Defect coverage	None	15	
	Secondary healing	3	2.1
	Primary closure	26	17.8
	Locoregional flap	50	34.2
	Wedge excision	8	5.5
	Split skin graft	30	20.5
	Full skin graft	7	4.8
	Partial auricectomy	8	5.5
	Total auricectomy	6	4.1
	Combination of methods	8	5.5
ELND (Elective Lymph Node Dissection)	ELND	9	5.6
	No ELND	152	94.4
SLNB (Sentinel Lymph Node Biopsy)	SLNB	29	18.0
	No SLNB	132	82.0

Table 3. Different types of 1st recurrence.

First recurrence	n	%
Local	14	8.7
Satellite / in-transit	6	3.7
Lymph node	10	6.2
Distant	8	5.0
Total	38	23.6

Table 4. Recurrence-free survival in univariate (Kaplan-Meier) and multivariate (Cox-proportional hazard) analysis.

	Univariate	Multivariate		
Variable	P	Relative risk	95% CI	P
Age	0.006			
< 59.19 years vs. > 59.19 years				
Location	0.002			0.011
Preauricular vs. front of the ear		4.30	1.65,10.65	
Back of the ear vs. preauricular		0.55	0.13, 2.06	
Tumour thickness	0.0076			< 0.0001
1.01-2.00 mm vs. < 1.00 mm		4.79	1.71,14.97	
> 2.00 mm vs. 1.01-2.00 mm		3.67	1.47, 9.19	
Histological type	< 0.0001			
SMM, LMM, NM, others				
Level of invasion	< 0.0001			
II, III, IV, V				
Excision margins	0.035			0.049
6-10 mm vs. < 5 mm		0.62	0.20, 2.10	
11-15 mm vs. 6-11 mm		1.07	0.40, 2.81	
> 15 mm vs. 11-15 mm		0.28	0.08, 0.83	

7. References

1. Arons, M. S. and Savin, R. C. Auricular Cancer. Some Surgical and Pathologic Considerations. *Am.J.Surg.* 1971;122(6):770-6.
2. Balch, C. M., Soong, S. J., Bartolucci, A. A., Urist, M. M., Karakousis, C. P., Smith, T. J., Temple, W. J., Ross, M. I., Jewell, W. R., Mihm, M. C., Barnhill, R. L., and Wanebo, H. J. Efficacy of an Elective Regional Lymph Node Dissection of 1 to 4 Mm Thick Melanomas for Patients 60 Years of Age and Younger. *Ann.Surg* 1996;224(3):255-63.
3. Benmeir, P., Baruchin, A., Weinberg, A., Nahlieli, O., Neuman, A., and Wexler, M. R. Rare Sites of Melanoma: Melanoma of the External Ear. *J.Craniomaxillofac.Surg.* 1995;23(1):50-3.
4. Bono, A., Bartoli, C., Maurichi, A., Moglia, D., and Tragni, G. Melanoma of the External Ear. *Tumori* 1997;83(5):814-7.
5. Breuninger, H., Schlagenhauff, B., Stroebel, W., Schaumburg, Lever G., and Rassner, G. Patterns of Local Horizontal Spread of Melanomas: Consequences for Surgery and Histopathologic Investigation. *Am.J.Surg Pathol.* 1999;23(12):1493-8.
6. Butler, C. E. Extended Retroauricular Advancement Flap Reconstruction of a Full-Thickness Auricular Defect Including Posteromedial and Retroauricular Skin. *Ann.Plast.Surg* 2002;49(3):317-21.
7. Byers, R. M., Smith, J. L., Russell, N., and Rosenberg, V. Malignant Melanoma of the External Ear. Review of 102 Cases. *Am.J.Surg.* 1980;140(4):518-21.
8. Cascinelli, N., Morabito, A., Santinami, M., Mackie, R. M., and Belli, F. Immediate or Delayed Dissection of Regional Nodes in Patients With Melanoma of the Trunk: a Randomised Trial. *WHO Melanoma Programme. Lancet* 14-3-1998;351(9105):793-6.
9. Cole, M. D., Jakowatz, J., and Evans, G. R. Evaluation of Nodal Patterns for Melanoma of the Ear. *Plast.Reconstr.Surg* 2003;112(1):50-6.
10. Cordova, A. and Moschella, F. Evaluation of Nodal Patterns for Melanoma of the Ear. *Plast.Reconstr.Surg* 15-4-2004;113(5):1528.

11. Davidsson, A., Hellquist, H. B., Villman, K., and Westman, G. Malignant Melanoma of the Ear. *J.Laryngol.Otol.* 1993;107(9):798-802.
12. Dost, P., Lehnerdt, G., Kling, R., and Wagner, S. N. Zur Chirurgischen Therapie Des Malignen Melanoms Der Ohrmuschel. [Surgical Therapy of Malignant Melanoma of the External Ear]. *HNO.* 2004;52(1):33-7.
13. Fisher, S. R. Cutaneous Malignant Melanoma of the Head and Neck. *Laryngoscope* 1989;99(8 Pt 1):822-36.
14. Hudson, D. A., Krige, J. E., Strover, R. M., and King, H. S. Malignant Melanoma of the External Ear. *Br.J.Plast.Surg.* 1990;43(5):608-11.
15. Iqbal, A. and Jaffe, W. Reconstruction of Marginal Ear Defects With Modified Chondrocutaneous Helical Rim Advancement Flaps. *Plast.Reconstr.Surg* 2004;114(1):283-4.
16. Lapid, O. Re: Sentinel Lymph Node Mapping in Melanoma of the Ear. *Ann.Plast.Surg* 1999;42(2):225.
17. Moehrle M. Evaluation operativer Strategien beim malignen Melanom. Habilitationsschrift der Universität Tübingen 2002.
18. Moehrle, M. Mikrographisch Kontrollierte Chirurgie (3D-Histologie) Beim Melanom. *Micrographic Surgery (3D-Histology) in Cutaneous Melanoma.* JDDG 1-11-2003.
19. Moehrle, M., Kraemer, A., Schippert, W., Garbe, C., Rassner, G., and Breuninger, H. Clinical Risk Factors and Prognostic Significance of Local Recurrence in Cutaneous Melanoma. *Br.J Dermatol* 2004;151(2):397-406.
20. Moehrle, M., Schippert, W., Garbe, C., Rassner, G., Röcken, M., and Breuninger, H. Prognostische Faktoren Und Operative Strategien Bei Melanomen Des Gesichts. *Prognostic Parameters and Surgical Strategies for Facial Melanomas.* JDDG 1-6-2003.
21. Narayan, D. and Ariyan, S. Surgical Considerations in the Management of Malignant Melanoma of the Ear. *Plast.Reconstr.Surg* 2001;107(1):20-4.
22. O'Brien, C. J., Coates, A. S., Petersen, Schaefer K., Shannon, K., Thompson, J. F., Milton, G. W., and McCarthy, W. H. Experience With 998 Cutaneous Melanomas of the Head and Neck Over 30 Years. *Am.J.Surg* 1991;162(4):310-4.

23. Ollila, D. W., Foshag, L. J., Essner, R., Stern, S. L., and Morton, D. L. Parotid Region Lymphatic Mapping and Sentinel Lymphadenectomy for Cutaneous Melanoma. *Ann.Surg.Oncol.* 1999;6(2):150-4.
24. Orfanos, C. E., Jung, E. G., Rassner, G., Wolff, H. H., and Garbe, C. Position and Recommendations of the Malignant Melanoma Committee of the German Society of Dermatology on Diagnosis, Treatment and After-Care of Malignant Melanoma of the Skin. Status 1993/94. *Hautarzt* 1994;45(5):285-91.
25. Pack, G. T., Conley, J., and Oropeza, R. Melanoma of the External Ear. *Arch.Otolaryngol.* 1970;92(2):106-13.
26. Pockaj, B. A., Jaroszewski, D. E., Dicaudo, D. J., Hentz, J. G., Buchel, E. W., Gray, R. J., Markovic, S. N., and Bite, U. Changing Surgical Therapy for Melanoma of the External Ear. *Ann.Surg.Oncol.* 2003;10(6):689-96.
27. Veronesi, U., Adamus, J., Bandiera, D. C., Brennhovd, I. O., Caceres, E., Cascinelli, N., Claudio, F., Ikonopisov, R. L., Javorskj, V. V., Kirov, S., Kulakowski, A., Lacoub, J., Lejeune, F., Mechl, Z., Morabito, A., Rode, I., Sergeev, S., van-Slooten, E., Szczygiel, K., and Trapeznikov, N. N. Inefficacy of Immediate Node Dissection in Stage 1 Melanoma of the Limbs. *N.Engl.J Med.* 22-9-1977;297(12):627-30.
28. Wanebo, H. J., Cooper, P. H., Young, D. V., Harpole, D. H., and Kaiser, D. L. Prognostic Factors in Head and Neck Melanoma. Effect of Lesion Location. *Cancer* 15-8-1988;62(4):831-7.
29. Ward, N. O. and Acquarelli, M. J. Malignant Melanoma of the External Ear. *Cancer* 1968;21(2):226-33.
30. Wey, P. D., De La, Cruz C., Goydos, J. S., Choi, M. L., and Borah, G. L. Sentinel Lymph Node Mapping in Melanoma of the Ear. *Ann.Plast.Surg* 1998;40(5):506-9.

8. Acknowledgements

- The greatest thank I owe PD Dr. Matthias Moehrle for entrusting me with this work, for his invaluable support, supervision and encouragement. And not to forget for his “infectious” enthusiasm concerning the operative and clinical Dermatology.
- Prof. Dr. M. Roecken, head of the Department of Dermatology in Tuebingen.
- Prof. Dr. Helmut Breuninger has set substantial basics for the concept of this work with the development of the 3D-histology and, as head of the dermatological surgery, has operated numerous patients innovatively.
- Prof. Dr. Claus Garbe, head of the section dermatological oncology, has built up the Melanoma registry of the Department of Dermatology in Tuebingen. This was a substantial condition for the statistical evaluation of the patients.
- Prof. Dr. K. Dietz, head of the Institute for medical biometrics, gave very helpful advice with the statistical evaluation of the data.
- For the kind cooperation I want to thank the whole “Follow-up-team” of the Tuebingen melanoma registry and also the porters, who always helped out patiently with keys and phone calls.
- I appreciate the support of Annika Beifuß and Georg Marckmann in proof-reading the manuscript.
- Last but not least I want to thank my partner Timm for his loving companionship and support.

9. Curriculum Vitae

Personal information

Name	Jahn, Verena Beate
Date of Birth	04.04.1980
Place of Birth	Hannover
Parents	Prof. Dr. Gerhard Jahn and Dr. Sabine Jahn née Trettin

Education

1986 – 1990	Primary school (Grundschule Neunkirchen a. Br.)
1990 – 1994	Grammar school (Emil-von-Behring-Gymnasium, Erlangen)
1994 – 1999	Grammar school (Eugen-Bolz-Gymnasium, Rottenburg)
29.06.1999	School-leaving examination (Abitur)

Higher education

1999 – 2006	Study of medicine in Tuebingen
27.03.2002	Preliminary medical examination (Ärztliche Vorprüfung)
28.08.2003	First state examination (Erster Abschnitt der Ärztlichen Prüfung)
14.09.2005	Second state examination (Zweiter Abschnitt der Ärztlichen Prüfung)
16.11.2006	Third state examination (Dritter Abschnitt der Ärztlichen Prüfung)