

Aus der

Universitätsklinik für Kinder- und Jugendmedizin Tübingen

Abteilung Kinderheilkunde I mit Poliklinik

(Schwerpunkt: Hämatologie, Onkologie, Gastroenterologie,
Nephrologie, Rheumatologie)

**Analysis of the impact of clinical and molecular genetic
factors on the tumor growth velocity of pediatric low-
grade glioma**

**Inaugural-Dissertation
zur Erlangung des Doktorgrades
der Medizin**

**der Medizinischen Fakultät
der Eberhard Karls Universität
zu Tübingen**

**vorgelegt von
Gorodezki, David**

2023

Dekan: Professor Dr. Bernd Pichler

1. Berichterstatter: Professor Dr. M. Ebinger
2. Berichterstatter: Professorin Dr. M. Renovanz

Tag der Disputation: 08.11.2023

Meinen Eltern

TABLE OF CONTENTS

INTRODUCTION	1
Pediatric Low-grade glioma: Epidemiology, biology and clinical presentation	1
Diagnosis and multimodal treatment	4
Outcome and study objectives	7
CHAPTER ONE	10
Resection extent and BRAF V600E mutation status determine postoperative tumor growth velocity in pediatric low-grade glioma: Results from a single-center analysis	
Abstract	11
Introduction	12
Patients and methods	13
Results	15
Discussion	22
Conclusion	26
Supplemental data	27
Contributions statement and declarations	28
References	28
CHAPTER TWO	33
Evaluating the safety of perioperative dexamethasone treatment: A retrospective analysis of a single center pediatric low-grade glioma cohort	
Abstract	34
Abbreviations	34
Introduction	35
Materials and Methods	37
Results	39
Discussion	45
Conclusion	48
Contributions statement and declarations	49
References	50
GENERAL DISCUSSION AND OUTLOOK	54
REFERENCES	58

SUMMARY / ZUSAMMENFASSUNG	67
CONTRIBUTION STATEMENT	70
PUBLICATIONS	71
ACKNOWLEDGMENTS	72

INTRODUCTION

Pediatric Low-grade glioma: Epidemiology, biology and clinical presentation

Brain tumors are the most frequent solid tumors of childhood and adolescence, representing a leading cause of death from malignancies to this day [1, 2]. Pediatric low-grade gliomas (pLGG) comprise a heterogeneous set of central nervous system (CNS) WHO grade I or II tumors of astrocytic, glial, and mixed glial-neural histology [3]. Among brain tumors, pediatric low-grade gliomas represent the most frequent entities, estimated to account for approximately 30 – 50 % of CNS tumors in children and adolescents [4, 5]. The incidence rate in Germany is estimated at 2 to 3 per 100.000 children, as approximately 250 patients under the age of 18 years are newly diagnosed with LGG in Germany each year [6]. Pediatric low-grade gliomas occur in all age groups and show a peak incidence in children 5 to 9 years of age [3].

As summarized in the most recent WHO classification of central nervous system tumors of 2021 (5th edition), pediatric low-grade gliomas comprise the following entities [7, 8]:

Pilocytic astrocytoma ° 1

- Pilomyxoid astrocytoma

Subependymal giant-cell astrocytoma (SEGA) ° 1

Other glial or mixed glial-neural tumors ° 1

- Ganglioglioma
- Dysembryoblastic neuroepithelial tumor
- Desmoplastic infantile astrocytoma and ganglioglioma
- Rosette-forming glioneural tumor
- Papillary glioneural tumor
- Angiocentric glioma
- Diffuse leptomeningeal glioneural tumor

Pleomorphic xanthoastrocytoma ° 2

Diffuse glioma ° 2

- Diffuse astrocytoma, IDH-mutant
- Diffuse astrocytoma, IDH-wildtype
- Diffuse astrocytoma, NOS
- Oligodendroglioma, IDH-mutant and 1p/19q codeleted
- Oligodendroglioma, NOS
- Oligoastrocytoma, NOS

Pediatric low-grade gliomas occur at any central nervous system site, with cerebellar low-grade gliomas representing the most frequent pediatric brain tumors (approximately 25% of cases), followed by gliomas of the cerebral hemispheres (10 – 15%), of the deep midline structures (10 – 15%), gliomas of the optic pathway (5%) and the brain stem (2 – 4 %) [3, 9]. The relative frequency of LGG entities varies by tumor site, as Pilocytic astrocytoma °1 represents the predominant type of cerebellar glioma, optic pathway glioma and glioma of the deep midline structures, while ganglioglioma °1 is the predominant entity in gliomas of the cerebral hemispheres in children and adolescents [3, 10 - 12].

Pediatric low-grade gliomas show substantial differences in biology and clinical behavior to LGG in adult patients, dictating different treatment strategies and resulting in distinct prognostic outlooks. While pediatric low-grade gliomas in most cases show indolent tumor growth, rarely progress to high grade lesions, and show favorable overall survival rates, malignant transformation is commonly observed in adult patients, resulting in a comparatively dismal prognosis [13].

Detailed studies on the biology and the genomic profiling of pediatric LGG identified underlying genetic alterations resulting in an upregulation of the RAS-mitogen-activated protein kinase (RAS/MAPK) pathway as a near universal biological feature, contributing to a more profound understanding of these tumors and representing a promising target for molecular therapies [14 - 17]. Common molecular driver mutations include KIAA1549-BRAF fusion, which is most

frequently found in Pilocytic astrocytoma (approx. 70%) and Rosette-forming glioneural tumors (approx. 30%), as well as BRAF V600E mutations, which are common in Pleomorphic xanthoastrocytoma (approx. 80%), Ganglioglioma (approx. 45 %) and Diffuse astrocytoma (approx. 40%). Further less frequent RAS/MAPK activating molecular alterations among others include FGFR1 mutations, ALK fusions and rare fusions and mutations of BRAF. Mutations in IDH1, which are often detected in adult glioma, scarcely appear in pediatric low-grade glioma [17].

A further distinctive biological feature of pediatric LGG is its association to predisposition syndromes, including Neurofibromatosis Type I (NF-1) and Tuberous sclerosis complex (TSC) [13]. Patients with NF-1 are at comparatively high risk of developing Optic pathway glioma (OPG), which occurs in up to 20 % of NF-1 patients with the highest incidence at 3-4 years of age and is most commonly showing the histological characteristics of Pilocytic astrocytoma ° 1 [18 - 20]. Conversely, approx. 40% of OPG patients harbor Neurofibromatosis Type 1 [21]. Furthermore, approximately 1 % of NF-1 patients develop brainstem glioma [20]. A distinct LGG entity, which almost exclusively appears in TSC patients, a predisposition syndrome characterized by genetic alterations in the mTOR pathway, is Subependymal giant-cell astrocytoma (SEGA) °1. The incidence of SEGA in TSC patients is estimated to approximately 20% [13, 22].

Clinical presentation of pediatric low-grade glioma can vary significantly, and highly depends on the tumor location. Patients with tumors of the posterior fossa mainly exhibit signs of raised intracranial pressure caused by impaired circulation of cerebral spinal fluid (CSF), furthermore, visual impairment, double vision and cerebellar signs including ataxia and dysarthria occur. Scarce manifestations of posterior fossa tumors include preterm puberty or hearing loss [23]. Low-grade gliomas of the brain stem may cause lower cranial nerve deficits or long tract signs, such as hemiparesis or spasticity [3]. Optic pathway glioma of the anterior optic pathway mainly presents with visual loss, while, remarkably, there is no clear correlation between visual impairment and tumor size. Further visual

symptoms including various vision field defects, relative afferent pupillary defect, nystagmus, strabismus, or exophthalmos are commonly observed [24]. Optic pathway glioma of the posterior optic pathway extending into the hypothalamic region, as well as tumors originating from other supratentorial midline structures may furthermore present with impaired CSF circulation, endocrinological impairments or diencephalic syndrome [21]. Low-grade gliomas of the cerebral hemispheres often present with seizures, often resistant to anticonvulsant treatment. Focal cortical symptoms may occur depending on the involved cortical region. LGG originating from the spinal cord characteristically cause long tract signs such as hemiparesis, spasticity, and hyperreflexia [3].

Diagnosis of pediatric low-grade glioma can be severely delayed due to its characteristically indolent growth. As previously reported from a consecutive cohort, almost half of the children and adolescents diagnosed with LGG have had symptoms associated to their disease at least 6 months prior to the eventual diagnosis [25]. On some occasions, pediatric LGG present with acute neurologic symptoms, not uncommonly caused by intratumoral hemorrhage [23].

Diagnostic procedures and multimodal treatment approaches

Gadolinium-enhanced magnet resonance imaging (MRI) is the modality of choice in diagnosis, staging, follow-up, and treatment response evaluation of pediatric brain tumors. Pediatric low-grade gliomas show characteristic MR imaging features and appear hypo- or isointense in T1-weighted MRI, hyperintense in T2-weighted imaging and appear hyperintense in fluid-attenuated inversion recovery (FLAIR) imaging. Inhomogeneous gadolinium enhancement appears to various degrees. While pilocytic tumors characteristically show well-circumscribed borders with cystic components, calcification can occasionally be apparent in ganglioglioma or in case of leptomeningeal involvement. In computer tomography (CT) scans, pediatric low-grade gliomas characteristically appear as hypo- or isodense lesions. Based on its inferior soft tissue contrasting compared to MR imaging, computer tomography is not the imaging modality of choice. However,

due to its broad availability and frequent application in case of acute neurological disorders, brain tumors are frequently first detected in CT scans [3, 26 - 28].

Gadolinium-enhanced MRI is commonly repeated within 24 – 48 hours after surgical resection for evaluation of resection extent and as a baseline for evaluation of possible residual tumor expansion during the follow-up period [29]. Complementary imaging of the spine is necessary for comprehensive assessment of the neural axis, as metastatic spread is observed in up to 6% of diagnosed cases [30]. Successive Follow-up MRI examinations of the tumor site are ordinarily repeated in three-month periods and are routinely extended in case of stable disease or sustained absence of recurrence.

Histopathological examination of tumor tissue is essential for diagnostic confirmation, stratification and thus determination of a surveillance and treatment protocol. Surgical biopsy is commonly required in case of unfeasible resection. However, in patients with confirmed NF-1 and characteristic imaging findings of optic pathway glioma, diagnostic biopsy is consensually considered an individual case decision [31].

Histopathological diagnosis is based on pathomorphological criteria and complemented by molecular tests, which include testing for mutations in IDH 1/2, BRAF V600E and FGFR1, deletion of the CDKN2A/B locus at 9p21, as well as testing for KIAA1549-BRAF translocation. Complementary molecular testing is based on the emerging concept of an integrated diagnosis embedding histopathological and molecular criteria and plays an emerging role in risk stratification and currently evaluated individualized molecular therapies [32].

For a detailed assessment of CNS functions, additional examinations including ophthalmological, endocrinological and electroencephalographic assessment is routinely complemented, depending on the location of the tumor.

Treatment of pediatric low-grade glioma should be managed by multidisciplinary team decisions and guided by comprehensive treatment study protocols. In

Germany, the updated treatment recommendations of the German speaking Society of Pediatric oncology are summarized in the HIT-LOGGIC 2019 registry protocol (Version 1.1, 2019).

Surgical resection is a pivotal element in case of symptomatic or progressive pediatric LGG, as surgical extent remains the crucial prognostic factor and significantly affects subsequent individual surveillance and treatment proceedings [33, 34]. Ever since the first successful surgical resection of a brain tumor was documented roughly 150 years ago, continuous advances in neurosurgical technology improved the outcome of CNS tumors [35]. Today, modern neuronavigational technology, neuromonitoring and intraoperative imaging-based resection control including intraoperative ultrasound and MRI applications facilitate maximal resection while preserving neurological function [36 - 38]. In case of tumor-related obstructive hydrocephalus, external ventricular drain (EVD) or ventriculoperitoneal shunt placement can be inevitable to restore CSF circulation. Furthermore, short-term perioperative steroid treatment is broadly applied and has proven to be beneficial in patients presenting with symptoms induced by tumor-related vasogenic edema or obstructive hydrocephalus [39, 40].

Although gross-total resection could only be achieved in 30 – 50% of cases in previous population-based cohort studies, observation is the primary approach in case of asymptomatic tumor remnants. In case of tumor recurrence or progress post incomplete resection, a multidisciplinary assessment should balance individual risks and potential benefits of repeated surgery and adjuvant salvage therapy approaches [41 - 43].

Radiation therapy has historically dominated salvage therapy regimens in pediatric LGG due to its efficacy in tumor control. However, due to age dependent substantial long-term side effects as cognitive decline, secondary malignancies, and endocrine disorders, conventional photon radiation nowadays is reserved for older patients, and led to development of innovative radiation methods including proton beam therapy and stereotactic radiation, contemplating to improve local tumor control while minimizing long-term side effects [44 - 48].

The first chemotherapy regimens for pediatric LGG were introduced and evaluated approximately 40 years ago, aiming to delay radiotherapy and to provide a potential alternative treatment for NF-1 patients, who naturally bear a significantly higher risk of radiation-induced secondary malignancies. Currently, the commonly used chemotherapy regimens contain either carboplatin and vincristine, vinblastine alone or a combination of thioguanine, procarbazine, CCNU and vincristine [44, 49].

Incremental discovery of the underlying molecular alterations of pediatric LGG over the past decade may offer novel mechanisms of tumor control bearing reduced toxicity. Numerous orally available selective molecular agents, including MEK-1/2 inhibitors selumetinib, trametinib, binimetinib and cobemetinib, as well as direct BRAF inhibitors vemurafenib and dabrafenib offer promising results from preclinical studies and are currently under evaluation in phase 1/2 trials in pediatric LGG patients. Although some of these agents are an integral part of the treatment protocols of different tumor entities like malignant melanoma, their role in the management of pediatric LGG remains open [44].

Treatment outcome and study objectives

Compared to adult low-grade glioma, pediatric LGG show crucially superior survival rates in long-term observational studies. Its less aggressive clinical course, a comparatively low rate of malignant transformation to high-grade glioma and its scarcity of metastatic dissemination emphasizes the distinct biology of pediatric low-grade gliomas compared to its adult counterparts [13, 30, 50]. More recent population-based cohort studies constantly reported 5-year overall survival rates of well over 90% [34, 51 - 53]. However, favorable progression-free survival (PFS) depends on complete tumor resection, as recent studies reported 5-year PFS rates of 45 to 65% post incomplete resection, contrary to gross-totally resected pediatric low-grade glioma, which rarely show tumor recurrence [3, 34, 51, 52, 54, 55].

The clinical course of pediatric Low-grade gliomas following incomplete resection yet shows a vast variability. While senescence or spontaneous regression are observed, patients experiencing multiple progressions and unsatisfactory tumor control often suffer from neurological and endocrine disorders and are prone to bear severe long-term morbidity [56 - 59].

Although several risk factors, including young age, fibrillary histology or supratentorial midline location were associated with a comparatively high risk of tumor progression in multivariate analyses of pediatric LGG cohorts, the ambivalent growth behavior of these tumors appears barely understood and commonly issues a challenge to oncologists attending these patients following incomplete resection [17, 51, 52].

In chapter one, we report of a retrospective analysis studying the ambivalent tumor growth behavior of pediatric low-grade gliomas of a large representative pediatric LGG cohort [60]. By using a novel approach, we analyze the tumor kinetics based on sequential MRI-based volumetric analyses, aiming to calculate individual tumor growth velocities of 191 patients diagnosed with pediatric LGG at a large single-center institution within the past 15 years [60]. In a subsequent analysis, we aim to evaluate the potential impact of clinical, pathological and molecular genetic variables including the extent of resection, histology, tumor location and molecular BRAF status on pre- and postoperative tumor growth rates, aiming to provide data to support treatment decisions following incomplete resection of pediatric LGG [60].

As previously mentioned, corticosteroids have shown a beneficial impact in the treatment of acute impairments related to tumor-associated vasogenic edema and impaired CSF circulation, and are frequently used in perioperative settings in pediatric brain tumor patients. Based on experience and pharmacokinetic considerations, dexamethasone is the preferably used agent [39, 40, 61, 62]. Remarkably, lately published preclinical and clinical data may raise concerns regarding the safety of corticosteroid treatment in pediatric LGG patients. A comprehensive analysis of oncogene-induced senescence in a preclinical pLGG model, which has recently been published, reported of an in vitro suppression of

the senescence associated phenotype of pLGG cells by incubation with dexamethasone [63]. Furthermore, clinical data derived from adult glioma cohorts partly indicates an association of a comparatively poor treatment outcome in dexamethasone-treated patients, while this effect appeared mostly pronounced in perioperative use of dexamethasone [64, 65]. Prior to this, no significant data on the safety of dexamethasone treatment in pediatric low-grade glioma patients has been published [66].

In chapter two, we report of a comprehensive analysis of the impact of perioperative dexamethasone application on postoperative tumor growth rates and progression-free survival in a large single-center pediatric low-grade glioma cohort. We study the clinical implication of a potential dexamethasone-induced senescence inhibition in these tumors, intending to provide evidence-based guidance for clinical decision making [66].

**Resection extent and BRAF V600E mutation status
determine postoperative tumor growth velocity in pediatric
low-grade glioma: Results from a single-center cohort
analysis**

**David Gorodezki¹, Julian Zipfel², Manon Queudeville¹, Jordana Sosa²,
Ursula Holzer¹, Jan Kern³, Andrea Bevot³, Jens Schittenhelm⁴, Thomas
Nägele⁵, Martin Ebinger^{1*} and Martin U Schuhmann^{2*}**

¹ Department of Hematology and Oncology, University Children's Hospital Tübingen, Tübingen, Germany

² Department of Neurosurgery, Section of Pediatric Neurosurgery, University Hospital Tübingen, Tübingen, Germany

³ Department of Neuropediatrics and Developmental Neurology, University Hospital Tübingen, Tübingen, Germany

⁴ Institute of Pathology, Department of Neuropathology, University Hospital Tübingen, Tübingen, Germany

⁵ Department of Neuroradiology, University Hospital Tübingen, Tübingen, Germany

* both authors contributed equally

Key words

low-grade glioma, surgery, senescence, BRAF V600E

J Neurooncol. 2022 Dec;160(3):567-576. doi: 10.1007/s11060-022-04176-4.

Epub 2022 Nov 1.

Abstract

Purpose

Despite excellent long-term overall survival rates, pediatric low-grade gliomas (pLGG) show high variety of clinical behavior regarding progress or senescence post incomplete resection (IR). This study retrospectively analyzes tumor growth velocity (TGV) of pLGG before surgery and after IR to investigate the impact of surgical extent, tumor location and molecular BRAF status on postoperative residual tumor growth behavior.

Methods

Of a total of 172 patients with pLGG receiving surgical treatment, 107 underwent IR (66%). Fifty-three vs 94 patients could be included in the pre- and post-operative cohort, respectively, and were observed over a mean follow-up time of 40.2 vs 60.1 months. Sequential three-dimensional MRI-based tumor volumetry of a total of 407 MRI scans was performed to calculate pre- and postoperative TGV.

Results

Mean preoperative TGV of 0.264 cm³/month showed significant deceleration of tumor growth to 0.085 cm³/month, 0.024 cm³/month and -0.016 cm³/month after 1st, 2nd, and 3rd IR, respectively ($p < 0.001$). Results remained significant after excluding patients undergoing (neo)adjuvant treatment. Resection extent showed correlation with postoperative reduction of TGV ($R = 0.97$, $p < 0.001$). ROC analysis identified a residual cut-off tumor volume > 2.03 cm³ associated with a higher risk of progress post IR (sensitivity 78,6%, specificity 76.3%, AUC 0.88). Postoperative TGV of BRAF V600E-mutant LGG was significantly higher than of BRAF wild-type LGG (0.123 cm³/month vs. 0.016 cm³/month, $p = 0.047$).

Conclusion

This data suggests that extensive surgical resection may impact pediatric LGG growth kinetics post incomplete resection by inducing a significant deceleration

of tumor growth. BRAF-V600E mutation may be a risk factor for higher postoperative TGV.

Introduction

Pediatric low-grade glioma (pLGG) comprise the most common CNS tumors of childhood, accounting for 30–50% of primary brain tumors in children and adolescents [1]. Despite excellent long-term overall survival rates (OS) following various degree of resection, survivors of pLGG are prone to suffer from functional, neurologic, and endocrine complications from their disease or treatment. Therapeutic strategies are challenged to provide maximum tumor control while minimizing irreversible long-term functional impairment [2, 3, 4].

Compared to LGG in adults, pLGG shows high variety of clinical behavior and limited predictability in terms of progress or senescence of tumor residuals, as prospective studies have reported 5-year PFS of 45% to 65% after incomplete resection (IR). Although the majority of LGG show indolent growth rates and spontaneous regression has been observed, late progression after years of senescence post primary therapy has been reported [3, 6, 7, 10, 11, 12]. Malignant transformation occurs scarcely in childhood LGG [13, 14].

As population-based cohort studies have identified the extent of surgery as the predominant factor for favorable OS and PFS, surgery remains the crucial element among advancing therapeutic approaches [2, 3, 5, 6, 7, 8, 9, 10]. However, resectability can be severely limited by surrounding eloquent anatomical structures, as population-based cohort studies show consistently high rates of IR in 65–73% of cases [2, 5, 6, 7].

As molecular profiling studies have incrementally identified key genetic alterations in pLGG affecting the RAS/MAPK pathway over the last decade, most somatic events appear to include BRAF alterations. [15, 16]. While the most frequent molecular alteration in pLGG (KIAA1549-BRAF fusion) is currently suspected to have a favorable impact on OS and PFS, pediatric LGG harboring

the most common mutation in BRAF (BRAF V600E) is presumably associated with unfavorable PFS [17, 18, 19]. By contrast, in vitro studies on pilocytic astrocytoma cells with BRAF alterations showed a tendency to senescence after an initial period of growth, suggesting that a subgroup of pLGG may exhibit growth deceleration over time [20, 21]. However, the prognostic role of these aberrations is currently discussed and remains unclear [15, 16, 17, 18, 19, 20, 21, 22, 23].

In this study, we analyzed the tumor growth velocity (TGV) of pLGG to investigate the impact of resection extent, tumor location and the most frequent BRAF aberrations on postoperative growth following IR. Therefore, using residual tumor volumetry to calculate tumor growth velocity, we compared tumor kinetics in sequential MRI follow-up examinations before and after surgical resection in a retrospective approach, aiming to identify potential variables to prognosticate further progress or senescence post subtotal resection.

Patients and Methods

Selection criteria

We searched the database of the Children's University Hospital of Tübingen for patients at the age of < 18 years at time of diagnosis, treated with LGG CNS WHO grade I or II according to the 2021 WHO classification of tumors at all CNS sites between 2006 and 2020 [24].

Inclusion criteria for this study were the availability of a minimum of two sequential MRI scans with defined sequences over a period no shorter than 6 months both before surgery (preoperative cohort) and after IR (postoperative cohort). Patients with radiographically confirmed GTR and no signs of relapse during the observation period were excluded from the postoperative cohort.

Methods

Patient data concerning tumor site, resection status and (neo)adjuvant treatment were obtained from the hospital database. Histopathological diagnoses, BRAF-KIAA1549 fusion status and BRAF-V600E mutation status were obtained from institutional and central pathology reports (German Reference Center for Paediatric Brain Tumors). Testing for BRAF V600E-mutation was performed via pyrosequencing following PCR amplification of the BRAF gene from extracted tumor DNA.

For patients with hypothalamic chiasmatic tumors associated with NF-1, radiological diagnosis of pilocytic astrocytoma was accepted, as biopsy has shown to be redundant in this constellation [25]. Radiological diagnosis of LGG was furthermore accepted in three non-NF-1 patients with characteristic imaging features of optic pathway glioma and no current indication for treatment.

MRI-based volumetry of pre- and postoperative tumor burden was serially performed on sequential axial MRI scans. Most images were taken at 1.5 T MRI with 1–3 mm slices. Three-dimensional tumor volumetry was performed using BrainLab Elements (version 3.0, BrainLab, Munich, Germany). Repeated volumetries of various investigators showed negligible variation of tumor volume measurements. A total of 407 MRI scans were analyzed, corresponding to 3.1 MRI scans per eligible patient.

Statistical analyses

Most analyses were performed using JMP 15.2.0 (SAS Institute Inc., Cary, North Carolina, USA). Anderson–Darling test was applied to analyze distribution of pre- and postoperative tumor growth rates. Due to not normally distributed data, nonparametric testing was performed for further analysis using Kruskal–Wallis test and Mann–Whitney rank sum test. Linear regression analysis, log rank test, one sample t-test and ROC analysis were performed using GraphPad Prism 8.0 (GraphPad Software, Inc., California, USA). Statistical significance was defined at p values ≤ 0.05 .

Results

A total of 191 patients were treated at our institution for pLGG between 2006 and 2020. Diagnoses included pilocytic astrocytoma °1 (137), ganglioglioma °1 (36), astrocytoma °2 (14), oligodendroglioma °2 (1), pleomorphic xanthoastrocytoma °1 (1), rosette-forming glioneural tumor (RGNT) °1 (1) and subependymal giant cell astrocytoma (SEGA) °1 (1). Tumor sites included the posterior fossa (80), supratentorial midline and optic nerve (55), cerebral hemispheres (46), spinal cord (8) and lateral ventricles (2). Overall, 172/191 patients (90.1%) underwent surgical therapy. GTR was achieved in 65 cases (38%), of whom 5 patients (7.7%) showed recurrence during follow-up. 107 patients (62%) received IR, defined as visible tumor remnants described by institutional and reference neuroradiology reports.

Ninety-four patients with tumor residuals could be included into in postoperative cohort, 53 patients met eligibility criteria for the preoperative cohort. Mean follow-up period of the pre- and postoperative cohort was 40.2 ± 36.1 and 60.1 ± 42.3 months, respectively.

Within the postoperative cohort, 51 patients (54%) fulfilled definition of subtotal resection ($> 90\%$ resection of initial tumor volume, STR). Partial resection (classified as $< 90\%$ resection of initial tumor volume, PR) was achieved in 43 patients (46%). STR was achieved in 30 (65%) of tumors located in the posterior fossa, 16 (76%) tumors located in the cerebral hemispheres and 5 (29%) of supratentorial midline gliomas.

Fifty-five (59%) patients showed no significant tumor growth following IR, including 36 (71%) of subtotally resected tumors and 19 (44%) of partially resected tumors.

Within the postoperative cohort, 22 patients (23%) after IR underwent second surgery following significant growth of residual tumor remnants within a mean follow-up period of 25 ± 17 months. Twenty patients (21%) post IR received further oncological treatment other than surgery due to progress and limited surgical options. A third intervention was necessary in 5 patients (5.3%) after a

further mean FU of 21 ± 10 months. Distribution of cases in a CONSORT flow diagram is illustrated in *figure 1*.

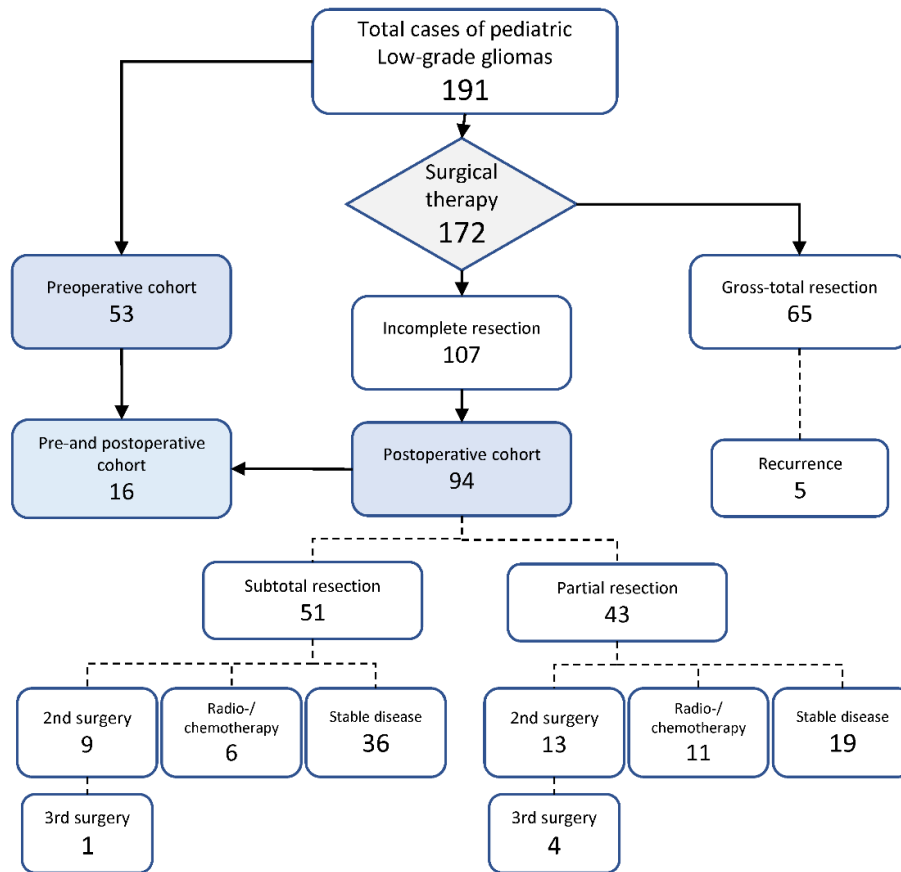


Figure 1 Distribution of cases within the analyzed single-center cohort of 191 patients treated with pediatric LGG at our institution between 2006 and 2020.

Comparison of pre- and postoperative tumor growth velocity (TGV)

Comparative analysis of pre- and postoperative TGV showed a mean preoperative growth velocity of $0.264 \text{ cm}^3/\text{month}$ ($n = 53$), while postoperative TGV after first IR accounted for $0.085 \text{ cm}^3/\text{month}$ ($n = 85$). After eliminating 46/85 patients (54%) with no measurable postoperative growth of residual tumor from the cohort, postoperative TGV after first STR accounted for $0.112 \text{ cm}^3/\text{month}$ ($n = 39$). Postoperative TGV after second and third STR showed a mean of $0.024 \text{ cm}^3/\text{month}$ ($n = 22$) and $-0.016 \text{ cm}^3/\text{month}$ ($n = 5$), respectively (see *figure 2A*). Tumor regression in 3/5 cases after third STR resulted in a slightly negative mean

TGV. Data sets showed non-standard distribution and variate analysis showed a significant difference (Kruskal–Wallis test, $p = 0.001$). Pairwise Mann–Whitney tests showed significant difference of mean preoperative TGV and mean growth rate following 1st STR ($p = 0.02$), 2nd STR ($p = 0.015$) and 3rd STR ($p < 0.001$).

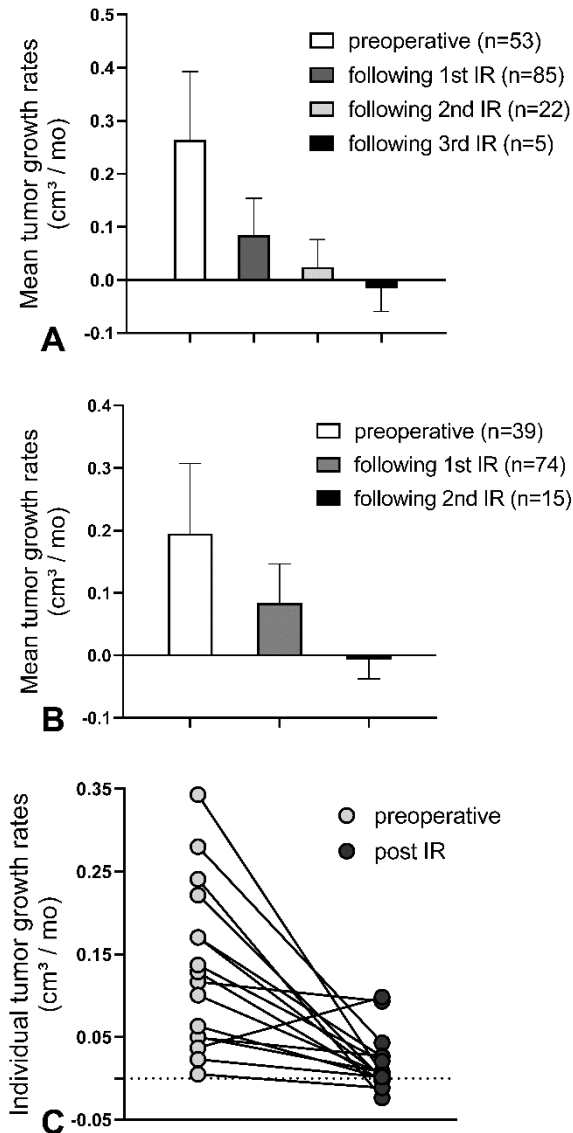


Figure 2 **A** Comparison of pre- and postoperative mean tumor growth rates showed a significant deceleration of tumor growth after 1st, 2nd and 3rd IR (Kruskal–Wallis test, $p = 0.001$, bars show mean and 95% CI). Pairwise Mann–Whitney tests showed significant difference of mean preoperative growth velocity and mean growth rate following 1st IR ($p < 0.02$), 2nd IR ($p = 0.015$) and 3rd IR ($p < 0.001$). **B** Results remained significant after excluding patients undergoing (neo)adjuvant treatment (Kruskal–Wallis test, $p = 0.037$, bars show mean and 95% CI). **C** Intra-patient comparison of individual tumor growth rates before and after IR. Tumor growth rates decreased by an average of 84.7% ($p = 0.0024$)

To investigate solely the impact of surgery on postoperative TGV, for all subsequent analyses patients who had obtained neoadjuvant oncological treatment (chemotherapy, radiotherapy, or targeted therapy) were further on excluded from both cohorts, and radiological follow-up post IR was ended when adjuvant treatment was administered. Comparison of pre- and postoperative tumor growth rates showed a mean preoperative TGV of 0.195 cm³/month (n = 39). Postoperative TGV showed an average of 0.038 cm³/month after first surgery (n = 74) and -0.007 cm³/month (n = 15) after second surgery (*figure 2B*). Variate analysis showed a significant difference (Kruskal–Wallis test, p = 0.037).

For a subset of 12 patients receiving surgery as the only oncological treatment, observation both before and after STR accounted for a minimum of 6 months respectively, allowing intra-patient comparison of pre- and postoperative TGV. Individual differences in TGV before and after STR are comparatively shown in *figure 2C*. Tumor growth rates decreased by an average of 84.7% (p = 0.0024). Increase of TGV after STR has been observed in one case.

Impact of resection extent on postoperative tumor growth velocity (TGV)

Resection extent was quantified on basis of tumor burden in consecutive pre- and postoperative MRI scans. Linear regression showed a minor, but significant negative correlation between extent of resection and TGV after IR (n = 71, R = -0.02, R squared = 0.07, p = 0.025), as shown in *figure 3A*.

Within the postoperative cohort, partially resected LGG showed a mean TGV of 0.113 cm³/month (n = 39), while mean postoperative TGV after subtotal resection (STR) was 0.047 cm³/month (n = 46). Mann–Whitney rank sum test showed a significant difference (p = 0.02).

For a subset of 16 patients not receiving any (neo)adjuvant treatment, follow-up period of > 6 months both prior and post STR allowed illustration of correlation between individual percental resection extent and relative decrease of individual tumor growth velocity compared to preoperative tumor growth rates. Linear regression showed significant correlation, as shown in *figure 3B* (R = 0.974, R squared 0.719, p < 0.001).

Impact of residual tumor volume on postoperative growth velocity (TGV) and calculation of a cut-off tumor volume to predict potential progress post IR

A significant positive correlation could be shown between the amount of residual tumor volume and postoperative TGV by linear regression, as illustrated in *figure 3C* ($n = 85$, $R = 0.025$, $R \text{ squared} = 0.3$, $p < 0.001$). Comparing mean residual tumor volumes of cases with radiologically measurable tumor growth vs tumor residuals with no signs of growth during the observation period post IR showed a significant difference of mean tumor volumes (9.308 cm^3 vs 2.308 cm^3 , $p = 0.011$), see *figure 3D*.

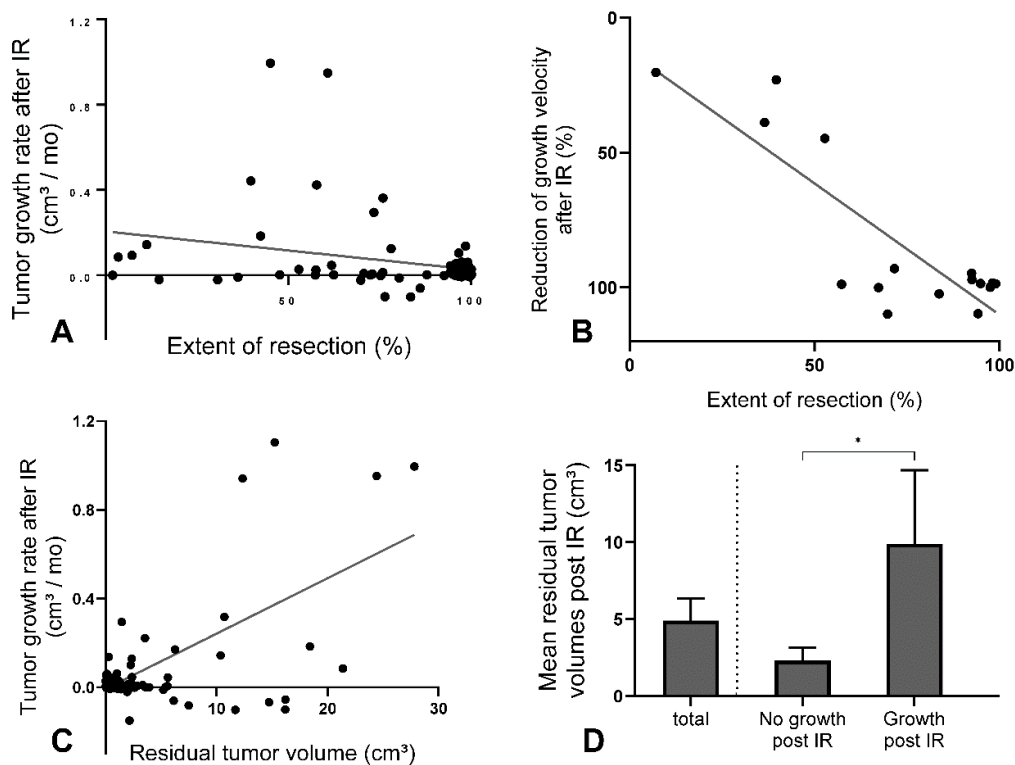


Figure 3 **A** Linear regression including 71 cases of incomplete resection showed a minor, thus significant negative correlation between extent of resection and postoperative growth rates ($R = -0.02$, $R \text{ squared} = 0.07$, $p = 0.027$). **B** A significant correlation between resection extent (%) and percental reduction of growth velocity after STR could be shown in 16 patients not receiving (neo)adjuvant treatment ($R = 0.974$, $R \text{ squared} = 0.719$, $p < 0.001$). **C** Linear regression analysis revealed a significant impact of residual tumor burden post incomplete resection on postoperative growth velocity ($R = 0.025$, $R \text{ squared} = 0.3$, $p < 0.001$). **D** Comparing mean residual tumor volumes of cases with measurable tumor growth vs tumor residuals with no signs of growth during the observation period post IR showed a significant difference of mean tumor volumes (9.308 cm^3 [$n = 19$] vs 2.308 cm^3 [$n = 55$], $p = 0.011$)

We conducted a ROC analysis in order to identify a potential cut-off tumor value post IR associated with a higher risk of radiologically detectable tumor growth during the follow up period within the postoperative cohort. A feasible cut-off tumor value was found at 2.03 cm³ (sensitivity 78.6%, specificity 76.3%, AUROC curve 0.88, p < 0.001).

Impact of tumor location on resection extend and pre- and postoperative tumor growth velocity

Furthermore, we compared pre- and postoperative TGV stratified by tumor location. Incomplete resection induced a significant deceleration of mean TGV in LGG located in the posterior fossa and the cerebral hemispheres (Mann–Whitney rank sum test, p=0.025 and p=0.018, respectively), the two main tumor locations in which the highest rates of STR could be achieved. However, significant impact of IR on TGV in supratentorial midline glioma could not be shown (p = 0.11). Results are listed in *table 1*.

Table 1 Illustration of mean pre- and postoperative tumor growth rates ± SD distinguished by tumor location.

Tumor location	Preoperative tumor growth rate	Postoperative tumor growth rate	Statistical significance
Posterior fossa (PF)	0.22 ± 0.2 n = 7	0.04 ± 0.102 n = 36	p = 0.025
Supratentorial midline (SMG) ^a	0.169 ± 0.472 n = 13	0.11 ± 0.261 n = 16	p = 0.11
Cerebral hemispheres (CH)	0.179 ± 0.212 n = 20	0.004 ± 0.019 n = 17	p = 0.018
total	0.1847 ± 0.357 n = 38	0.057 ± 0.180 n = 80	p = 0.37

^a included: opticohypothalamic tumors and tumors of the basal ganglia

Impact of BRAF V600E mutation and BRAF-KIAA1549 fusion on pre- and postoperative tumor growth velocity

We investigated the impact of BRAF V600E mutation status on pre- and postoperative growth rates. BRAF V600E mutation status was analyzed in 18/53 cases (34%) within the preoperative cohort during a later performed resection, and BRAF V600E mutation was detected in 8/18 cases (44%).

In postoperative cohort, BRAF V600E mutation status was tested in 55/94 cases (59%), and 12/55 (21%) cases were positive. In the preoperative cohort, BRAF V600E-mutated LGG showed a mean TGV of 0.305 cm³/month (n = 8), while BRAF wild-type glioma showed a mean TGV of 0.082 cm³/month (n = 10), while missing statistical significance (p = 0.09). Within the postoperative cohort, BRAF V600E-mutated glioma showed a mean TGV of 0.123 cm³/month (n = 12), while BRAF wild-type glioma showed a significantly lower mean TGV of 0.016 cm³/month (n = 43, p = 0.047). Results are illustrated in *figure 4A*.

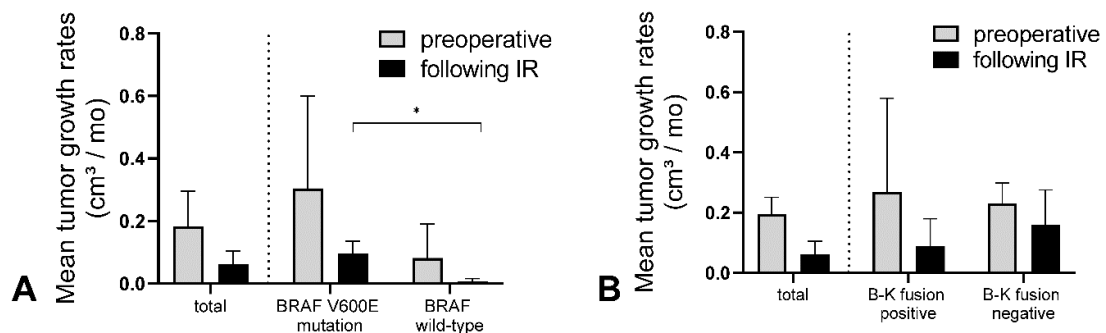


Figure 4 **A** Comparison of postoperative growth velocities of BRAF V600E mutant LGG and BRAF wild-type LGG showed significant difference of means (0.123 cm³/month and 0.016 cm³/month). **B** Comparative analysis of pre- and postoperative tumor growth rates in BRAF-KIAA1549 fusion positive and negative LGG showed no significant differences of means (p = 0.17 and p = 0.09, respectively)

BRAF-KIAA1549 (B-K) fusion was only detected in pilocytic astrocytoma and tumors histologically classified as diffuse astrocytoma. Among cases of pilocytic

astrocytoma, B-K fusion was detected in 37/49 cases (75%) and showed the highest frequency in midline glioma (11/11, 100%).

B-K fusion negative and B-K fusion positive tumors showed a mean preoperative TGV of 0.23 cm³/month (n = 10) and 0.27 cm³/month (n = 3), respectively. Analyzing the postoperative cohort, B-K fusion negative tumors showed a mean TGV of 0.16 cm³/month (n = 16), while B–K fusion positive tumors showed a mean TGV of 0.09 cm³/month (n = 33). No statistical significance was found in either group. Results are illustrated in *figure 4B*.

Discussion

Of 191 Patients treated with pLGG between 2006 and 2020 at our institution, a total of 53 vs 94 patients in the pre- and postoperative cohort, respectively, could be included in our analyses. Distribution of both histopathological diagnoses and tumor sites within the cohorts showed similarity to previously published population-based cohort studies [2, 5, 6].

Mean follow-up period within our cohorts of 60.1 vs 40.1 months outlasted the median time to progression of approximately 28 months in a previously published pLGG cohort [19].

To decode the ambivalent biological behavior of pLGG after IR most precisely, we determined TGV in sequentially performed volumetric analyses using a specialized neuronavigational software, which has shown favorable intra-rater variability in previous evaluation [26]. Three-dimensional volumetric measures on the base of planimetry were used due to superior sensitivity to change in growth tracking compared to linear measurements, as previously shown in vestibular schwannoma [27].

Comparative analysis of pre- and postoperative TGV showed a significant decrease of tumor growth after surgical intervention, as this effect showed continuity after second and third IR. As this data implies, relative extent of resection and residual tumor volume appear to have a significant impact on

postoperative TGV. This tendency appeared even more visible and highly significant in intra-patient analysis within the subgroup of patients with available pre- and postoperative tumor growth rates.

Further stratification of cases towards subtotally resected and partially resected tumors showed significantly lower mean tumor growth rates post STR compared to PR. Remarkably, 39/51 (70%) of subtotally resected tumors vs 19/43 (44%) of partially resected tumors showed stable disease without any radiological indication of progression within the observation period, thus providing no indication for further local or systemic therapy, similar to cases post GTR with no sign of recurrence. Those 'silent' tumor residuals post IR showed a significantly lower mean tumor volume compared to pLGG with radiographically detectable tumor growth post IR. ROC analysis identified a residual cut-off tumor volume $> 2.03 \text{ cm}^3$ associated with a higher risk of radiologically detectable progress post IR.

The impact of tumor location on resection extent and thus postoperative tumor growth rates is well illustrated by the comparative analysis of pre- and postoperative TGV distinguished by tumor location. As the highest rates of STR could be achieved in pLGG located in the cerebral hemispheres and the posterior fossa (76% and 65%, respectively) compared to supratentorial midline (29%), a significant deceleration of tumor growth post IR could solely be shown in the first two subgroups. Lower rates of STR in tumors surrounded by highly eloquent brain tissue located in the supratentorial midline appears to be in line with previous publications, showing that extensive resection of pLGG in deep-seated midline locations appears rarely possible, often associated with unsatisfactory tumor control and long-term morbidity [28, 29]. In contrast, this might indicate a lower surgical risk profile of glioma located in the cerebral hemispheres and the posterior fossa, consistent to previous data, attesting glioma of the cerebral hemisphere and posterior fossa a comparatively superior PFS [5].

As this data emphasizes the impact of resection extent and residual tumor volume in pediatric low-grade glioma surgery, it subsequently highlights the importance of preoperative risk assessment and the role of technical modalities for

intraoperative resection control including intraoperative ultrasound, high-field intraoperative MRI (iMRI) and electro-physiological intraoperative neuromonitoring (IOM), as some of these modalities have shown to play a crucial role in maximizing resection extent while preventing irreversible long-term neurologic impairment [30,31,32].

The underlying molecular mechanisms causing a tendency to growth deceleration of tumor residues still remain unclear. In a detailed in vitro analysis of oncogene-induced senescence (OIS) in a pilocytic astrocytoma model, Buhl et al. have demonstrated a significant reduction of growth by stimulation of pilocytic astrocytoma cells with rIL1B, while anti-inflammatory treatment with dexamethasone induced regrowth of senescent cells and inhibited the senescence-associated secretory phenotype (SASP) [21]. Based on the assumption of surgical intervention leading to the induction of local inflammatory processes in surrounding tissues, this may outline a possible explanation for indolent growth rates after radical resection, as cytokine concentrations and exposure to inflammatory processes may be considerably higher in smaller tumor residuals post extensive resection. Further investigation of molecular mechanisms of postoperative senescence in pLGG is warranted.

Comparison of postoperative TGV of BRAF V600E mutant LGG and BRAF wild-type LGG showed significantly higher postoperative tumor growth rates in BRAF V600E mutant LGG, which may suggest incompletely resected BRAF V600E positive pLGG as a high-risk subgroup, in line with previously published clinical data [17, 18].

Comparative analysis of pre- and postoperative tumor growth rates in BRAF-KIAA1549 (B-K) fusion positive and negative LGG showed no significant difference of mean TGV. B-K fusion was only detected in pilocytic astrocytoma and diffuse astrocytoma, consistent to a previously published screening of a large brain tumor cohort [33]. Notably, B-K fusion showed the highest frequency in supratentorial midline glioma excluding opticohypothalamic tumors (11/11, 100%), in line with previous publications [34]. Despite a limited overall conclusiveness of this data due to low case numbers, these key molecular

alterations may play a significant role in terms of risk stratification and moreover represent a promising target for molecular therapies [16].

Moreover, the results of this study emphasize the distinct biology of pediatric versus adult LGG, as in a comparable study, Mandonnet et al. have shown no significant difference of growth rates before and after IR in adult WHO grade II glioma [35]. In consistence with the significantly higher tendency of adult LGG to evolve into higher-grade lesions, this may be considered as a consequence of fundamental molecular and genetic differences between these tumor entities [8]. As previously published by Pallud et al., the initial MRI growth rates of WHO II° gliomas in adult patients have shown long-term prognostic value [36].

The limitations of this study include the limited validity due to its retrospective approach. Moreover, overall conclusiveness of the data on the impact of BRAF alterations on postoperative TGV may be limited due to low case numbers included in the corresponding analyses. A significant number of cases were diagnosed before molecular testing for BRAF alterations was routinely performed, which resulted in a relatively high number of cases with unknown molecular BRAF aberration status in our cohort.

Regarding the method of tumor volume measurement and calculation of growth velocity it should be pointed out, that a reliable differentiation of residual tumor burden from unspecific postoperative signal intensity alterations in postoperative MRI scans can be very difficult, particularly in small potential postoperative residuals. To address this potential bias, only 3-month follow-up MRI examinations with contrast enhanced sequences were used as the earliest postoperative reference scan instead of immediate postoperative MRI data for a more reliable differentiation of residual tumor burden from unspecific postoperative signal intensity alterations. Moreover, central radiologic review reports of the Neuroradiology Reference Center of the German Society of Pediatric Oncology were consulted in all disputable cases. Patients were only included to the IR group in case of a confirmed tumor residual by the Neuroradiology Reference Center report. Nonetheless, a possible misinterpretation in distinct cases of very small tumor residuals cannot be

excluded for sure, and might lead to an underestimated rate of achieved GTR and thus a relatively higher rate of achieved IR. Moreover, a possible misinterpretation in distinct cases of very small tumor residuals may possibly have an impact on calculated mean postoperative TGV, and may be—in contrast to a possible actual tumor regression—an alternative explanation for a slightly negative mean TGV after 2nd or 3rd IR (as illustrated in *figure 2A, B*).

Conclusion

This study underscores the role of surgery within the treatment of pediatric LGG. Besides reduction of tumor mass effects to restore functional integrity of surrounding brain tissue and CSF circulation, the extent of surgery may impact the kinetics of pediatric low-grade glioma residuals post IR by inducing a significant deceleration of tumor growth, emphasizing the role of pursuing maximal possible tumor resection while preventing irreversible long-term neurologic impairment.

Supplemental data

Low-grade glioma (LGG)								
	total	PA °1 ^a	GG °1 ^b	A °2 ^c	RGNT °1 ^d	SEGA °1 ^e	PXA °2 ^f	OGD °II ^g
Sex								
Male	95	66	20	7	1	1		
Female	96	71	16	7			1	1
Age at diagnosis 7.9 years (1 – 17)								
0 - 4	52	43	7	2				
5 - 9	55	44	6	4	1			
10 - 14	44	33	8	2		1		
15 - 17	40	17	15	6			1	1
NF-1	22	22						
Localization								
PF ^h	80	75	5	2	1			
SMG and OG ⁱ	55	49	2	4				
CH ^j	46	9	28	7			1	1
LV ^k	2			1		1		
Spinal cord	8	5						
Resection extent								
GTR ^m	65	38	18	8				1
STR ⁿ	58	42	10	3	1	1	1	
PR ^o	49	38	8	3				
No surgery	19	19						
(Neo)adjuvant therapy								
Chemotherapy	29	29						
Radiation	15	12		2			1	
Targeted therapy	5	5						
total	191	137	36	14	1	1	1	1

^a Pilocytic astrocytoma °1

^b Ganglioglioma °1

^c Astrocytoma °2

^d Rosette-forming glioneural tumor °1

^e Subependymal giant cell astrocytoma °2

^f Pleomorphic Xanthoastrocytoma °2

^g Oligodendroglioma °2

^h Posterior fossa

ⁱ Supratentorial midline glioma and Optic pathway glioma

^j Cerebral hemisphere

^k Lateral ventricle

^m Gross-total resection

ⁿ Subtotal resection

^o Partial resection

Supplemental table S1 Detailed demographic and clinical data of a single center cohort of 191 patients treated with LGG between 2006 and 2020.

Contributions statement and declarations

Author contributions

All Authors contributed to the study's conception and design. Material preparation und data collection were performed by DG, MS, ME, JS and JZ, data analysis was performed by DG. The first draft of the manuscript was written by DG. MS and ME supervised the study and edited the manuscript. All authors commented on previous versions of the manuscript. All authors read and approved the final manuscript.

Funding

Open Access funding enabled and organized by Projekt DEAL. The author(s) reported there is no funding associated with the work featured in this article.

Data availability

The datasets analyzed during the current study are available from the corresponding author on reasonable request.

Conflict of interest

No potential conflict of interest was reported by the authors.

Ethical approval

This study was performed in line with the principles of the Declaration of Helsinki. Approval was granted by the Ethics Committee of the Medical Faculty and the University Hospital of Tübingen (NO 762/2021B02). Individual consent was waived.

References

1. Rickert CH, Paulus W. Epidemiology of central nervous system tumors in childhood and adolescence based on the new WHO classification. Childs Nerv Syst. 2001 Sep;17(9):503-11. doi: 10.1007/s003810100496.

2. Bandopadhyay P, Bergthold G, London WB, et al: Long-term outcome of 4,040 children diagnosed with pediatric low-grade gliomas: an analysis of the Surveillance Epidemiology and End Results (SEER) database. *Pediatr Blood Cancer*. 2014 Jul;61(7):1173-9. doi: 10.1002/pbc.24958.
3. Sievert AJ, Fisher MJ. Pediatric low-grade gliomas. *J Child Neurol*. 2009 Nov;24(11):1397-408. doi: 10.1177/0883073809342005.
4. Armstrong GT, Liu Q, Yasui Y, et al. Long-term outcomes among adult survivors of childhood central nervous system malignancies in the Childhood Cancer Survivor Study. *J Natl Cancer Inst*. 2009;101(13):946-958. doi: 10.1093/jnci/djp148.
5. Stokland T, Liu JF, Ironside JW, et al: A multivariate analysis of factors determining tumor progression in childhood low-grade glioma: a population-based cohort study (CCLG CNS9702). *Neuro Oncol*. 2010 Dec;12(12):1257-68. doi: 10.1093/neuonc/noq092.
6. Gnekow AK, Falkenstein F, von Hornstein S, et al: Long-term follow-up of the multicenter, multidisciplinary treatment study HIT-LGG-1996 for low-grade glioma in children and adolescents of the German Speaking Society of Pediatric Oncology and Hematology. *Neuro Oncol*. 2012 Oct;14(10):1265-84. doi: 10.1093/neuonc/nos202.
7. Jeffrey H. Wisoff, MD, Robert A. Sanford, MD, Linda A. Heier, MD, et al: Primary Neurosurgery for Pediatric Low-Grade Gliomas: A Prospective Multi-Institutional Study From the Children's Oncology Group, *Neurosurgery*, Volume 68, Issue 6, June 2011, 1548–1555. doi: 10.1227/NEU.0b013e318214a66e.
8. Collins KL, Pollack IF. Pediatric Low-Grade Gliomas. *Cancers (Basel)*. 2020 May 4;12(5):1152. doi: 10.3390/cancers12051152.
9. Fisher BJ, Leighton CC, Vujovic O, Macdonald DR, Stitt L. Results of a policy of surveillance alone after surgical management of pediatric low grade gliomas. *Int J Radiat Oncol Biol Phys*. 2001 Nov 1;51(3):704-10. doi: 10.1016/s0360-3016(01)01705-9.
10. Shaw EG, Wisoff JH. Prospective clinical trials of intracranial low-grade glioma in adults and children. *Neuro Oncol*. 2003 Jul;5(3):153-60. doi: 10.1215/S1152851702000601.
11. Rozen WM, Joseph S, Lo PA. Spontaneous regression of low-grade gliomas in pediatric patients without neurofibromatosis. *Pediatr Neurosurg*. 2008;44(4):324-8. doi: 10.1159/000134925.

12. Schmandt SM, Packer RJ, Vezina LG, Jane J. Spontaneous regression of low-grade astrocytomas in childhood. *Pediatr Neurosurg*. 2000 Mar;32(3):132-6. doi: 10.1159/000028917.
13. Broniscer A, Baker SJ, West AN, et al. Clinical and molecular characteristics of malignant transformation of low-grade glioma in children. *J Clin Oncol* 2007; 25: 682– 689. doi: 10.1200/JCO.2006.06.8213.
14. Avinash KS, Thakar S, Aryan S, Ghosal N, Hegde AS. Malignant Transformation of Pediatric Low-grade Gliomas: Report of Two Cases and Review of a Rare Pathological Phenomenon. *Neurol India*. 2019 Jul-Aug;67(4):1100-1106. doi: 10.4103/0028-3886.266259.
15. Ryall S, Zapotocky M, Fukuoka K, et al: Integrated Molecular and Clinical Analysis of 1,000 Pediatric Low-Grade Gliomas. *Cancer Cell*. 2020 Apr 13;37(4):569-583.e5. doi: 10.1016/j.ccell.2020.03.011.
16. Ryall, S., Tabori, U. & Hawkins, C. Pediatric low-grade glioma in the era of molecular diagnostics. *acta neuropathol commun* 8, 30 (2020). <https://doi.org/10.1186/s40478-020-00902-z>
17. Lassaletta A, Zapotocky M, Mistry M, et al: Therapeutic and prognostic implications of BRAF V600E in pediatric low-grade gliomas. *J Clin Oncol* 35: 2934-2941, 2017. doi: 10.1200/JCO.2016.71.8726.
18. Mistry M, Zhukova N, Merico D, Rakopoulos P, Krishnatry R, Shago M, Stavropoulos J, Alon N, Pole JD, Ray PN, Navickiene V, Mangerel J, Remke M, Buczkowicz P, Ramaswamy V, Guerreiro Stucklin A, Li M, Young EJ, Zhang C, Castelo-Branco P, Bakry D, Laughlin S, Shlien A, Chan J, Ligon KL, Rutka JT, Dirks PB, Taylor MD, Greenberg M, Malkin D, Huang A, Bouffet E, Hawkins CE, Tabori U. BRAF mutation and CDKN2A deletion define a clinically distinct subgroup of childhood secondary high-grade glioma. *J Clin Oncol*. 2015 Mar 20;33(9):1015-22. doi: 10.1200/JCO.2014.58.3922.
19. Hawkins C, Walker E, Mohamed N, Zhang C, Jacob K, Shirinian M, Alon N, Kahn D, Fried I, Scheinemann K, Tsangaris E, Dirks P, Tressler R, Bouffet E, Jabado N, Tabori U. BRAF-KIAA1549 fusion predicts better clinical outcome in pediatric low-grade astrocytoma. *Clin Cancer Res*. 2011 Jul 15;17(14):4790-8. doi: 10.1158/1078-0432.CCR-11-0034.
20. Raabe EH, Lim KS, Kim JM, Meeker A, Mao XG, Nikkhah G, Maciaczyk J, Kahlert U, Jain D, Bar E, Cohen KJ, Eberhart CG. BRAF activation induces transformation and then senescence in human neural stem cells: a pilocytic astrocytoma model. *Clin Cancer Res*. 2011 Jun 1;17(11):3590-9. doi: 10.1158/1078-0432.CCR-10-3349.

21. Buhl JL, Selt F, Hielscher T, Guiho R, et al: The Senescence-associated Secretory Phenotype Mediates Oncogene-induced Senescence in Pediatric Pilocytic Astrocytoma. *Clin Cancer Res.* 2019 Mar 15;25(6):1851-1866. doi: 10.1158/1078-0432.CCR-18-1965.
22. Horbinski C, Hamilton RL, Nikiforov Y, Pollack IF. Association of molecular alterations, including BRAF, with biology and outcome in pilocytic astrocytomas. *Acta Neuropathol.* 2010 May;119(5):641-9. doi: 10.1007/s00401-009-0634-9.
23. David T.W. Jones, Olaf Witt, and Stefan M. Pfister: *BRAF* V600E Status Alone Is Not Sufficient as a Prognostic Biomarker in Pediatric Low-Grade Glioma. *Journal of Clinical Oncology* 2018 36:1, 96-96. doi: 10.1200/JCO.2017.75.8987.
24. Louis DN, Perry A, Wesseling P, Brat DJ, Cree IA, Figarella-Branger D, Hawkins C, Ng HK, Pfister SM, Reifenberger G, Soffiotti R, von Deimling A, Ellison DW. The 2021 WHO Classification of Tumors of the Central Nervous System: a summary. *Neuro Oncol.* 2021 Aug 2;23(8):1231-1251. doi: 10.1093/neuonc/noab106.O.D.
25. Leonard JR, Perry A, Rubin JB, King AA, Chicoine MR, Gutmann DH. The role of surgical biopsy in the diagnosis of glioma in individuals with neurofibromatosis-1. *Neurology.* 2006 Oct 24;67(8):1509-1. doi: 10.1212/01.wnl.0000240076.31298.47.
26. Kollmann, P., Mautner, VF., Koeppen, J. *et al.* MRI based volumetric measurements of vestibular schwannomas in patients with neurofibromatosis type 2: comparison of three different software tools. *Sci Rep* 10, 11541 (2020). <https://doi.org/10.1038/s41598-020-68489-y>.
27. Harris GJ, Plotkin SR, Maccollin M, Bhat S, Urban T, Lev MH, Slattery WH. Three-dimensional volumetrics for tracking vestibular schwannoma growth in neurofibromatosis type II. *Neurosurgery.* 2008 Jun;62(6):1314-9; doi: 10.1227/01.neu.0000333303.79931.83.
28. Krishnatry R, Zhukova N, Guerreiro Stucklin AS, Pole JD, Mistry M, Fried I, Ramaswamy V, Bartels U, Huang A, Laperriere N, Dirks P, Nathan PC, Greenberg M, Malkin D, Hawkins C, Bandopadhyay P, Kieran MW, Manley PE, Bouffet E, Tabori U. Clinical and treatment factors determining long-term outcomes for adult survivors of childhood low-grade glioma: A population-based study. *Cancer.* 2016 Apr 15;122(8):1261-9. doi: 10.1002/cncr.29907.
29. Nageswara Rao AA, Packer RJ. Advances in the management of low-grade gliomas. *Curr Oncol Rep.* 2014;16(8):398. doi: 10.1007/s11912-014-0398-9.

30. C Roder, M Breitkopf, S Bisdas, R da Silva Freitas, A Dimostheni, M Ebinger, M Wolff, M Tatagiba, M U. Schuhmann. Beneficial impact of high-field intraoperative MRI on effectivity of pediatric low-grade glioma surgery. *Neurosurg Focus*. 2016 Mar;40(3):E13. doi: 10.3171/2015.11.FOCUS15530.
31. Lorenzen A, Groeschel S, Ernemann U, Wilke M, Schuhmann MU. Role of presurgical functional MRI and diffusion MR tractography in pediatric low-grade brain tumor surgery: a single-center study. *Childs Nerv Syst*. 2018 Nov;34(11):2241-2248. doi: 10.1007/s00381-018-3828-4.
32. Carai A, De Benedictis A, Calloni T, Onorini N, Paternò G, Randi F, Colafati GS, Mastronuzzi A, Marras CE. Intraoperative Ultrasound-Assisted Extent of Resection Assessment in Pediatric Neurosurgical Oncology. *Front Oncol*. 2021 Apr 21;11:660805. doi: 10.3389/fonc.2021.660805.
33. Lawson AR, Tatevossian RG, Phipps KP, Picker SR, Michalski A, Sheer D, Jacques TS, Forsheew T. RAF gene fusions are specific to pilocytic astrocytoma in a broad paediatric brain tumour cohort. *Acta Neuropathol*. 2010 Aug;120(2):271-3. doi: 10.1007/s00401-010-0693-y.
34. Faulkner C, Ellis HP, Shaw A, et al. BRAF Fusion Analysis in Pilocytic Astrocytomas: KIAA1549-BRAF 15-9 Fusions Are More Frequent in the Midline Than Within the Cerebellum. *J Neuropathol Exp Neurol*. 2015;74(9):867-872. doi: 10.1097/NEN.0000000000000226.
35. Mandonnet E, Pallud J, Fontaine D, et al: Inter- and inpatient comparison of WHO grade II glioma kinetics before and after surgical resection. *Neurosurg Rev*. 2010 Jan;33(1):91-6. doi: 10.1007/s10143-009-0229-x.
36. Pallud J, Mandonnet E, Duffau H, Kujas M, Guillemin R, Galanaud D, Taillandier L, Capelle L. Prognostic value of initial magnetic resonance imaging growth rates for World Health Organization grade II gliomas. *Ann Neurol*. 2006 Sep;60(3):380-3. doi: 10.1002/ana.20946. PMID: 16983683.

Evaluating the safety of perioperative dexamethasone treatment: A retrospective analysis of a single center pediatric low-grade glioma cohort

David Gorodezki¹, Julian Zipfel², Manon Queudeville^{1,6}, Ursula Holzer¹, Andrea Bevot³, Jens Schittenhelm⁴, Thomas Nägele⁵, Martin U Schuhmann^{2*} and Martin Ebinger^{1*}

¹ Department of Hematology and Oncology, University Children's Hospital Tübingen, Tübingen, Germany

² Department of Neurosurgery, Section of Pediatric Neurosurgery, University Hospital Tübingen, Tübingen, Germany

³ Department of Neuropediatrics and Developmental Neurology, University Hospital Tübingen, Tübingen, Germany

⁴ Institute of Pathology, Department of Neuropathology, University Hospital Tübingen, Tübingen, Germany

⁵ Department of Neuroradiology, University Hospital Tübingen, Tübingen, Germany

⁶ Department of Pediatric Hematology and Oncology, University Medical Center Hamburg-Eppendorf, Hamburg, Germany

* both authors contributed equally

Key words

low-grade glioma, surgery, dexamethasone

Int J Cancer. 2023 May 1;152(9):1875-1883. doi: 10.1002/ijc.34399. Epub

2022 Dec 23.

Abstract

In addition to surgical management, corticosteroids have proven to be beneficial in the management of acute symptoms related to CNS tumors, and have been widely used for many decades, with dexamethasone (DM) representing the most commonly used agent. However, lately published in vitro data possibly indicates a DM-induced suppression of oncogene-induced senescence (OIS) in a preclinical pediatric low-grade glioma (pLGG) model, which, alongside data associating perioperative DM treatment with reduced event-free survival in adult glioma, raises questions concerning the safety of DM treatment in pLGG. A total of 172 patients with pLGG were retrospectively analyzed concerning the impact of perioperative DM application on postoperative short- and long-term tumor growth velocity and progression-free survival (PFS). Three-dimensional volumetric analyses of sequential MRI follow-up examinations were used for assessment of tumor growth behavior. Mean follow-up period accounted for 60.1 months. Sixty-five patients (45%) were perioperatively treated with DM in commonly used doses. Five-year PFS accounted for 93% following gross-total resection (GTR) and 57% post incomplete resection (IR). Comparison of short- and long-term postoperative tumor growth rates in patients with vs without perioperative DM application showed no significant difference (short-term: 0.022 vs 0.023 cm³/month, respectively; long-term: 0.019 vs 0.023 cm³/month, respectively). Comparison of PFS post IR (5-year-PFS: 65% vs 55%, respectively; 10-year-PFS: 52% vs 53%, respectively) and GTR (5- and 10-years-PFS: 91% vs 92%, respectively) likewise showed similarity. This data emphasizes the safety of perioperative DM application in pLGG, adding further evidence for decision making and requested future guidelines.

Abbreviations

CNS	central nervous system
CSF	cerebral spinal fluid

DM	dexamethasone
GTR	gross-total resection
ICP	intracranial pressure
IR	incomplete resection
LGG	low-grade glioma
MRI	magnetic resonance imaging
NF-1	neurofibromatosis type I
OIS	oncogene-induced senescence
OS	overall survival
PFS	progression-free survival
pLGG	pediatric low-grade glioma
WHO	World Health Organization

Introduction

Tumors of the central nervous system (CNS) are the most frequent solid malignancies of childhood and adolescence, representing the leading cause of cancer-related death in pediatric cohorts to this day [1, 2]. Unlike in adult cohorts, in which high-grade lesions show significantly higher prevalence, pediatric low-grade glioma (pLGG), comprising a large and heterogeneous group of tumors, represent the most common entities within pediatric brain tumor cohorts and account for 45% to 50% of newly diagnosed CNS malignancies [3].

Despite favorable overall survival rates (OS) and, compared to low-grade glioma (LGG) in adults, a comparatively low tendency to evolvement into high-grade lesions or metastatic spread within the CNS, patients with diagnosed pLGG often

suffer from long-term neurologic impairment or endocrine disorders, caused by tumor burden or treatment sequelae [4 - 8].

As previous analyses show, both incidence of neurologic impairments at the time of initial diagnosis, as well as long-term neurologic outcomes vary by tumor location, and are partially affected by a long prediagnosis symptom interval [9]. Before diagnosis, children and adolescents with LGG often exhibit symptoms of increased intracranial pressure, induced or consolidated by impaired cerebral spinal fluid (CSF) circulation. Focal symptoms, including seizures or endocrine disorders highly depend on tumor location [10, 11].

In addition to surgical management, including removal of tumor mass to preserve functional integrity of surrounding brain tissue and external ventricular drainage to reconstitute CSF drainage, corticosteroids have proven to be beneficial in the management of acute symptoms related to CNS tumors, and have been widely used for many decades [12, 13]. Due to its lack of mineralocorticoid activity and prolonged symptom control (biological $t^{1/2}$: 36-54 hours), dexamethasone (DM) is the most commonly used agent [14]. Lately, a multicentric survey among members of a national pediatric neuro-oncology consortium suggested a conformal recommendation of perioperative DM use for patients with vasogenic edema and obstructive hydrocephalus caused by newly diagnosed brain tumors [15]. However, unlike in adult patients, no guidelines concerning the use and dosage of DM in pediatric brain tumors exist up to this day, consolidating its broad and frequent application on “conventional wisdom and use” [12, 13, 16].

Dose-dependent gastrointestinal, metabolic and psychological side effects are well described [17, 18]. Moreover, in a previously published detailed analysis of oncogene-induced senescence in a BRAF-KIAA1549 positive pilocytic astrocytoma model, Buhl et al have demonstrated a significant induction of regrowth of senescent cells after treatment with DM, inhibiting the senescence-associated secretory phenotype (SASP) on a molecular level and possibly indicating a suppression of senescence in a preclinical pLGG model [19].

However, the literature on the prognostic role of corticosteroid administration in pediatric brain tumors is scarce. While the effects of DM on cell growth and OS in adult glioma remains controversial, independent studies, as well as a meta-analysis partly confirmed association of a poor treatment outcome with use of DM in adult glioma [20, 21]. To our knowledge, no significant clinical data regarding the impact of DM on progression-free survival (PFS) and OS in pLGG has been published to this day.

In our study, we investigated the impact of perioperative DM application on PFS within a single-center pediatric low-grade glioma cohort. Furthermore, we studied the impact of DM administration on short- and long-term tumor growth rates after incomplete resection (IR) by analyzing tumor kinetics in sequential MRI follow-up examinations in a retrospective approach, aiming to add further evidence for decision making and future guidelines concerning the use and dosage of DM in newly diagnosed pLGG.

Materials and Methods

Patient selection criteria

We searched the database of University Children's Hospital Tuebingen, a tertiary care medical center, for patients treated with pLGG between 2006 and 2020. Eligibility criteria included age <18 years and histological diagnosis of glioma grade I or II according to WHO criteria at all CNS sites. Both patients with and without diagnosis of neurofibromatosis type I (NF-1) and other phacomatoses were included. Histological diagnoses were obtained from pathology reports, contributed by the Department of Neuropathology at University Hospital Tuebingen. In case of inconclusive pathologic diagnosis, central pathology review, provided by German Reference Center for Brain Tumors (Institute of Neuropathology, University of Bonn) was consulted. For patients with optico-hypothalamic tumors associated with NF-1 or for tumors extending along visual

pathways, radiological diagnosis was accepted, as biopsy is not common practice in this constellation [22].

Methods

Patient data including age, pathologic diagnosis, tumor location, dose and duration of potential DM administration, as well as time to potential progression were obtained from the database.

For calculation of tumor growth rates, MRI-based volumetric analyses of postoperative tumor burden were serially performed on sequential axial MRI scans. Most images were taken by a 1.5 T MRI with 1 to 3 mm slices without intersectional gaps. For reliable differentiation of residual tumor burden and unspecific postoperative signal intensity alterations after surgical intervention, 3-month follow-up MRI examinations were used for volumetry of residual tumor mass as the earliest reference value for calculation of individual tumor growth rates after IR. Three-dimensional volumetric measures were used due to superior sensitivity to change in growth tracking compared to linear measurements, as previously shown in vestibular schwannoma [23]. Tumor volumetry was performed using BrainLab Elements (version 3.0, BrainLab, Munich, Germany), a specialized and broadly used Windows-based neuronavigational software, which has shown superior intrarater variability compared to different tools in previous evaluation of tumor volume measurements in intracranial tumors [24]. To calculate tumor volumes, lesional areas were manually determined for each slice using T2-weighted sequences, following semiautomated calculation of volume. Repeated volumetry of various investigators showed negligible variation of tumor volumes.

MIB-1 proliferation index (PI) was retrieved from the pathological records. Slides from paraffin-embedded tumor samples were routinely immunostained using Ki-67 antibody (DakoCytomation, Glostrup, Denmark, clone MIB-1, dilution 1:200) on an automated immunohistochemistry staining system (BenchMark, Ventana Medical Systems, Tucson, Arizona). The automated standard protocol uses cell conditioning pretreatment, a universal biotinylated immunoglobulin secondary

antibody and diaminobenzidine as substrate. The sections were counterstained with hemalaun. The LI was estimated by experienced neuropathologists as an overall percentage of positive tumor nuclei of the immunostained tumor cells.

Statistical analyses

Most analyses were performed using JMP 15.2.0 (SAS Institute Inc., Cary, North Carolina). Anderson-Darling test was applied to analyze distribution of postoperative tumor growth rates. Due to not normally distributed data, nonparametric testing was performed for further analysis using Mann-Whitney rank sum test. Log-rank (Mantel-Cox) test was performed for PFS curve comparison using GraphPad Prism 8.0 (GraphPad Software, Inc., California). P values <.05 were considered statistically significant.

Results

A total of 191 patients diagnosed with pLGG were treated at our institution during the enquiry period. Mean age at diagnosis was 7.9 years (range, 2.9-17.2). Histopathological diagnoses comprehended Pilocytic astrocytoma (137), Ganglioglioma °I (36), Astrocytoma °II (14), Pilomyxoid astrocytoma °II (2), Oligodendroglioma °II (2), Pleomorphic xanthoastrocytoma °II (1), Rosette-forming glioneural tumor °I (1) and Subependymal giant cell astrocytoma °I (1). Tumor sites of cases in our cohort involved the posterior fossa (80), supratentorial midline and optic nerve (55), cerebral hemispheres (46), spinal cord (8) and lateral ventricles (2). Distribution showed approximate conformity to previously published population-based cohort studies [25 – 27].

A total of 172 patients (91%) received surgical therapy. Gross-total resection (GTR) could be achieved in 65 (38%) of cases, while subtotal resection (STR, defined as removal of >90% of initial tumor mass) was achieved in 59 cases (34%). Partial resection (PR, defined as removal of <90% of initial tumor mass) was performed in 48 cases (28%). Twenty-seven patients (16%) received adjuvant chemo-, radio- or targeted therapy, 19 patients (9%) were treated with

chemo-, radio- or targeted therapy only. An overview on distribution of cases within the cohort is displayed in *table 1*.

Table 1 Distribution of histological diagnoses, resection extent, perioperative DM treatment and progression-free survival of 172 surgically treated cases of pediatric Low-grade glioma

Low-grade Glioma	Total	Resection extent			Perioperative DM	5-year PFS post GTR	5-year PFS post IR
		GTR	STR	PR			
Pilocytic astrocytoma °I	117	39 (33 %)	44 (37 %)	34 (29 %)	49	88 %	54 %
Ganglioglioma °I	35	19 (54 %)	9 (26 %)	7 (20 %)	8	100 %	66 %
Astrocytoma °II	14	6 (40 %)	3 (20 %)	5 (33 %)	4	100 %	41 %
RGNT °I ^a	1	-	-	1 (100 %)	1		
PXA °II ^b	1	-	1 (100 %)	-	1		
SEGA °I ^c	1	-	1 (100 %)	-	1		
Pylomyxoid astrocytoma	2	-	1 (100 %)	1 (100 %)	1		
Oligodendroglioma °II	1	1 (100 %)	-	-	-		
total	172	65	59	48	65^d	93 %	57 %

^a Rosette-forming glioneural tumor °I

^b Pleomorphic xanthoastrocytoma °II

^c Subependymal giant cell astrocytoma °I

^d No retrospectively accessible data regarding possible perioperative dexamethasone application was available in 27 cases (15 %).

A total of 22 patients with gross-total resection (34%) and 43 patients with IR (44%) were perioperatively treated with DM, in most cases due to clinical and radiographical signs of obstructive hydrocephalus (44 patients, 68%). Mean DM dosing accounted for 0.27 mg (± 0.09) per kilogram or 7.87 mg (± 2.4) per square meter body surface area daily, spread in three doses. Mean duration of treatment accounted for 82 hours (± 47) with various length of tapering. No retrospectively accessible data regarding perioperative DM application was available in 27 cases (15%).

To study the clinical implication of senescence inhibition of dexamethasone as observed in vitro by Buhl et al more comprehensively, we analyzed the MIB-1 proliferation index (PI) for indirect estimation of senescent vs proliferating cells in the tumors included in our cohort. MIB-1 PI was obtainable in 57/73 patients

(78%) within the cohort of incompletely resected pLGG, of whom 36 patients (63%) were perioperatively treated with dexamethasone.

Mean MIB-1 PI accounted for 2.12% (± 1.7) and ranged from 0.1% to 8%, as the results approximately match the data of a previous analysis of MIB-1 PI in pLGG cohorts, indicating comparatively low proliferation indices in these tumor entities, with only a vanishingly low fraction of pLGGs showing a MIB-1 PI >10% [28, 29].

Impact of perioperative DM application on long- and short-term postoperative tumor growth rates after IR

For calculation of short-term postoperative tumor growth rates, tumor volumetry of follow-up MRI scans over a period of 12 months after surgical therapy were included. Individual postoperative short-term tumor growth rates showed a mean of 0.022 cm³/month (range: -0.008 to 0.18). Comparison of short-term tumor growth rates within the first year showed a mean growth velocity of 0.022 cm³/month (n = 43) in patients who were perioperatively treated with DM, while mean first year postoperative tumor growth velocity within the control group (patients not treated with DM perioperatively) accounted for 0.023 cm³/month (n = 30). Postoperative tumor growth rates in both groups showed nonstandard distribution, Mann-Whitney rank sum test showed no significance in difference (P = .19). Results are illustrated in *figure 1A*.

Mean observation time for calculation of postoperative long-term tumor growth rates accounted for 60.1 months. A total of 407 tumor volumetric analyses were performed, equivalent to an average of 4.3 per eligible patient. In cases of second (n = 22) or third IR (n = 5), tumor volume 3 months postsurgical re-intervention was used as a reference for further calculations of tumor growth velocity. Individual long-term tumor growth rates showed a mean of 0.021 cm³/month (range, -0.05 to 0.33). Comparison of long-term tumor growth rates after IR showed similarity as mean growth velocity of accounted for 0.019 cm³/month (n = 43) in patients treated with DM perioperatively, while mean postoperative tumor growth velocity within the control group accounted for 0.023 cm³/month (n = 30). Data showed nonstandard distribution, mean tumor growth velocities of both

groups showed no significant difference ($P = .12$, Mann-Whitney rank sum test). Results are illustrated in *figure 1B*.

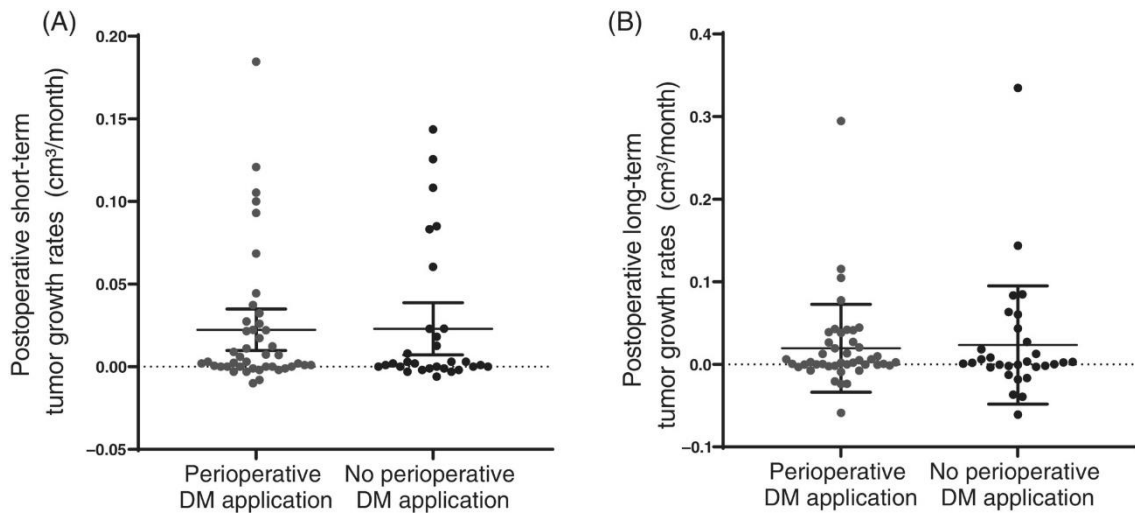


Figure 1 (A) Comparison of short-term postoperative tumor growth rates in patients with perioperative DM treatment ($n = 43$) vs patients with no perioperative DM application ($n = 30$) showed no significant difference (0.022 vs 0.023 cm^3/month , respectively, $P = .19$). **(B)** Postoperative long-term tumor growth rates show no significant difference (0.019 vs 0.023 cm^3/month , respectively, $P = .12$) in patients perioperatively treated with DM ($n = 43$) vs patients without perioperative DM application ($n = 30$).

A total of seven patients (6.5%) were excluded due to either unavailability of follow-up MRI data or insufficient comparability of MRI imaging for sequential tumor volumetry.

For further analysis of the impact of perioperative DM treatment on tumors with a relatively low fraction of proliferating cells vs tumors with a relatively high fraction of proliferating cells, we divided our cohort into tumors with MIB-1 PI $\leq 1\%$ ($n = 24$) vs tumors with MIB-1 PI $\geq 2\%$ ($n = 33$).

Comparison of mean short-term tumor growth velocity within the group of tumors with a relatively high fraction of proliferating cells showed no significant difference in patients perioperatively treated with DM vs patients with no DM treatment (0.033 vs 0.029 cm^3/month , $P = .81$, Kruskal-Wallis test), while comparison of short-term tumor growth velocity in patients of both groups with tumors containing a relatively low fraction of proliferating cells likewise showed no significant

difference (0.012 vs 0.018 cm³/month, respectively, $P = .19$, Kruskal-Wallis test, see figure 2A).

Comparing mean long-term tumor growth velocity within the group of tumors with a relatively high fraction of proliferating cells showed no significant difference in patients perioperatively treated with DM vs patients with no DM treatment (0.035 vs 0.039 cm³/month, respectively, $P = .78$, Kruskal-Wallis test), while comparison of long-term tumor growth velocity in patients of both groups with tumors containing a relatively low fraction of proliferating cells likewise showed no significant difference (0.012 vs 0.006 cm³/month, respectively, $P = .12$, Kruskal-Wallis test, see figure 2B).

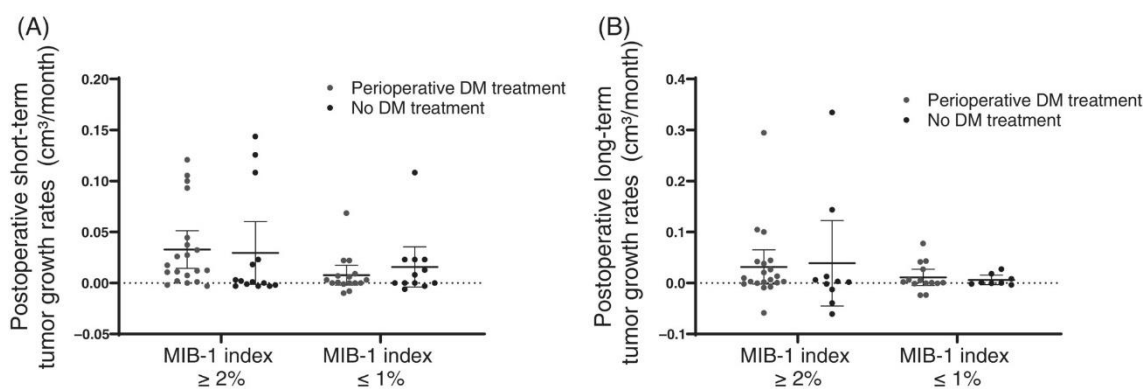


Figure 2 Comparison of mean short-term **(A)** and long-term **(B)** tumor growth velocity within the groups of tumors with both a relatively low (MIB-1 PI ≤1) and high (MIB-1 PI ≥2) fraction of proliferating cells showed no significant difference in patients perioperatively treated with DM vs patients with no DM treatment.

Impact of perioperative DM application on PFS after GTR and IR

Survival analysis showed a 5-year progression-free survival (PFS) of 57% in incompletely resected pLGG (n = 105), as a total of 46 patients experienced progression during the first 60 months of follow up. Five patients experienced relapse within 5 years after surgical removal of all radiologically detectable tumor, resulting in a 5-year PFS of 93% post GTR (n = 65).

Comparison of PFS after IR showed a 5-year PFS of 65% within the group of patients treated with DM perioperatively (n = 43) vs 55% within the control group

(n = 30). 10-year PFS after IR accounted for 52% in the DM group vs 53% within the control group. Curve comparison showed no significant difference of survival curves (Log-rank test, $\chi^2 = 0.59$, $P = .18$). Further stratification of patients treated with DM perioperatively to patients who received higher doses (>0.3 mg/kg bodyweight DM daily, n = 8) vs patients treated with lower doses (<0.3 mg/kg bodyweight DM daily, n = 35) likewise showed no significant difference (5- and 10-year-PFS: 62% vs 55%, respectively; Log-rank test, $\chi^2 = 0.05$, $P = .82$). Comparison of PFS post-IR is illustrated in *figure 3A*. Comparison of PFS after GTR showed a 5-year PFS of 91% within the group of patients treated with DM perioperatively (n = 22) vs 92% within the control group (n = 43). Ten-year PFS after IR accounted for 91% in the DM group vs 92% within the control group. Curve comparison again showed no significant difference of survival curves (Log-rank test, $\chi^2 = 0.03$, $P = .58$). None of the patients who received GTR was treated with DM doses >0.3 mg/kg bodyweight daily, thus further stratification to patients treated with higher vs lower doses perioperatively was not feasible. Results are illustrated in *figure 3B*.

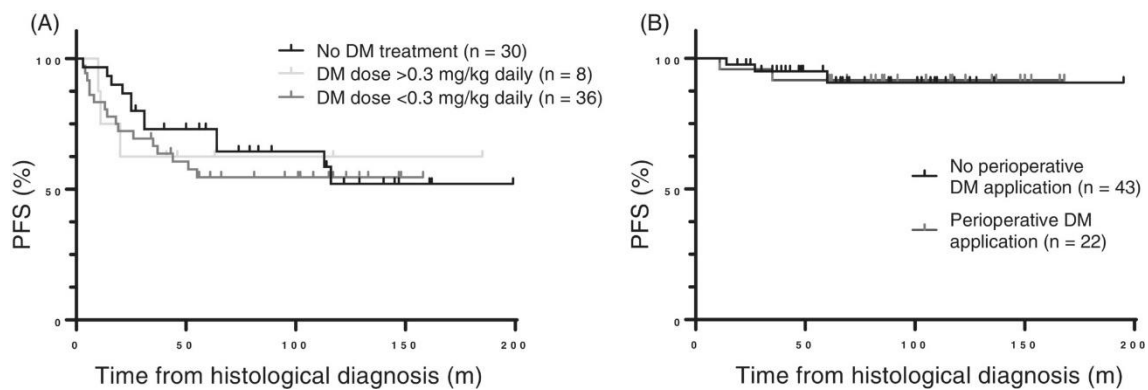


Figure 4 (A) Comparison of PFS of patients with perioperative high- and low-dose DM treatment with (n = 43) vs patients with no perioperative DM application (n = 30) post-IR showed no significant difference (Log-rank test, $\chi^2 = 0.05$, $P = .82$). **(B)** PFS of patients perioperatively treated with DM (n = 22) vs patients without perioperative DM application (n = 43) post GTR showed no significant difference (5- and 10-years-PFS: 91% vs 92%, respectively, $P = .58$)

We furthermore compared PFS curves within the group of tumors characterized by MIB-1 PI $\geq 2\%$ of patients perioperatively treated with DM vs patients with no DM treatment. No significant difference of PFS curves could be shown (Log-rank test, $\chi^2 = 0.01$, $P = .83$, see *figure 4A*). Similar comparison of PFS curves of

patients with MIB-1 PI $\leq 1\%$ of patients treated with DM vs patients with no DM likewise showed no significant difference (Log-rank test, $\chi^2 = 0.12$, $P = .73$, see figure 4B).

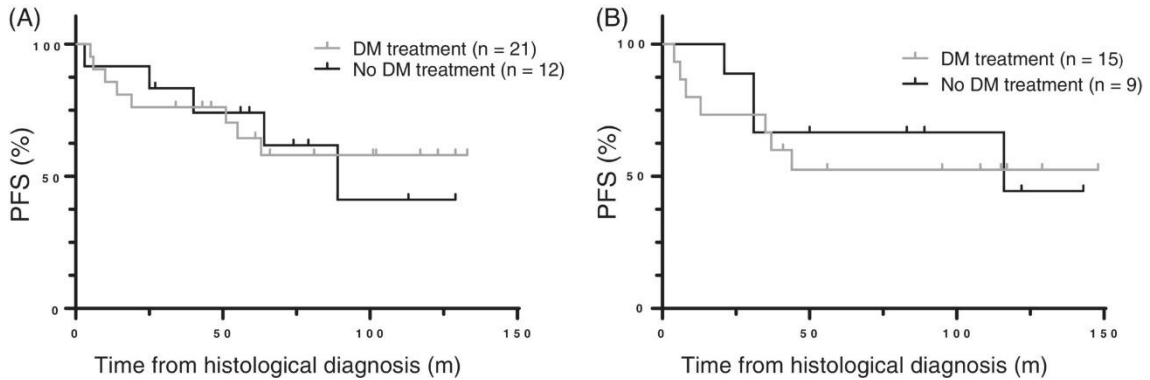


Figure 4 (A) Comparison of PFS curves post IR within the group of tumors characterized by a higher fraction of proliferating cells (MIB-1 PI $\geq 2\%$) showed no significant difference between patients perioperatively treated with DM vs patients with no DM treatment (Log-rank test, $\chi^2 = 0.01$, $P = .83$). **(B)** Similar comparison of PFS curves within the group of tumors characterized by a lower fraction of proliferating cells (MIB-1 PI $\leq 1\%$) between patients treated with DM vs patients with no DM likewise showed no significant difference (Log-rank test, $\chi^2 = 0.12$, $P = .73$).

Discussion

In our study, we analyze the impact of perioperative DM application on postoperative short-/long-term tumor growth rates and PFS in a large single center cohort of 191 patients treated with pLGG in a retrospective approach, aiming to provide more evidence regarding the safety of the broad and frequent use of corticosteroids for symptom control in newly diagnosed pediatric brain tumor patients.

Distribution of histological diagnoses and tumor sites, as well as relative frequency of achieved gross-total resections and PFS data of our cohort showed approximate compliance to cohorts of previously published population-based cohort studies, underlining the representative characteristics of the studied cohort despite using a single center approach [25 – 27].

Mean dosing and treatment durations were in approximate consistency with suggested recommendations in a previously mentioned multicentric survey among members of a national pediatric neuro-oncology consortium [15]. As the use of dexamethasone in symptomatic management of newly diagnosed CNS tumors in children is empirically based on the experience in adult patients, similar treatment durations with rounding adjustment of doses to children's body weight were used in most cases. However, retrospective analysis revealed significant variations in prescription practices in several cases based on clinician preference, resulting in a dosing range from 0.07 to 0.61 mg/kg bodyweight daily. This is in accordance to what was most recently reported from the retrospective observational study on the utility and prescription standards from a different tertiary care center, and may be seen as a consequence of the absence of evidence-based guidelines [30].

To study the effect of DM application on postoperative tumor growth rates, tree-dimensional volumetric analysis was used. As previously shown in a comparative study of MRI-based growth assessment in vestibular schwannoma, volumetric analyses showed superior sensitivity in assessment of tumor expansion of intracranial lesions compared to diameter measurements [23].

Within our cohort, 65 patients (45%) were perioperatively treated with DM in commonly used doses and treatment durations, mostly due to clinical or radiological signs of obstructive hydrocephalus, a common and severe condition in newly diagnosed pLGG patients, mostly in tumors located in the posterior fossa [10]. In these patients, application of corticosteroids is highly valued for its remarkable benefits in symptom control. The underlying mechanisms of intracranial pressure (ICP) reduction by DM application in brain tumor patients have solely been studied in adult patients to this day, and possibly indicate a reduction of ICP plateau waves and brain edema, as well as a decrease of CSF production, as shown in previous studies on the effects of DM in these patients [17, 31 – 33].

However, lately published preclinical data raises the question regarding the safety of DM application in pLGG patients. In a detailed analysis of oncogene-

induced senescence in a preclinical BRAF-KIAA1549 positive pLGG model, Buhl et al showed a significant regrowth of senescent glioma cells after DM application, possibly indicating a suppression of senescence in a preclinical LGG model [19]. Clinical data lately likewise raised the question regarding the safety of DM treatment for symptom control in glioma patients, as in a retrospective analysis, Medikonda et al showed that perioperative dexamethasone use may negatively impact survival in adult glioma patients. This effect was most pronounced in patients receiving only preoperative dexamethasone [20]. Likewise, a meta-analysis including 2230 adult glioblastoma patients partly confirmed an association of DM application with poor treatment outcome [21]. However, there is no significant data derived from pediatric cohorts available to this day.

Our data show no significant difference in both postoperative short- and long-term tumor growth rates, as well as PFS in patients with vs without perioperative DM treatment within our pediatric cohort. A slight difference in long-term tumor growth rates post-IR showed no statistical significance. To study the clinical implication of senescence inhibition of dexamethasone as observed in vitro by Buhl et al more comprehensively, we furthermore split the cohort in patients with tumors bearing a relatively low fraction of proliferating cells vs tumors with a relatively high fraction of proliferating cells. Comparison of postoperative tumor growth rates, as well as PFS post-IR of patients treated with DM perioperatively vs patients without DM treatment showed no significant differences within both groups. This data underlines the absence of an impact of perioperative DM treatment on senescence inhibition within our cohort, contrary to what was observed in vitro by Buhl et al [19].

Although these results underscore the safety of perioperative DM application in newly diagnosed pLGG patients, the presented data; however, does not make any implications on the safety of long-term use of corticosteroids in pLGG, as perioperative DM treatment duration did not exceed the course of 129 hours within our cohort. A significantly longer treatment duration may possibly show a clinically relevant effect on tumor growth rates. However, this data emphasizes the safety of commonly used perioperative treatment regimens applied in children

with acute symptoms caused by CNS tumors, as treatment durations barely outlast 3- to 8-day periods in this group of patients, as complementarily shown by a previously published retrospective analysis of the utility and prescriptions standards by a further tertiary care center [30].

As an evident explanation on why the previously mentioned in vitro effect of senescence inhibition observed by Buhl et al did not translate into clinical implications in our cohort cannot be derived from this data, we have to underline, that the regulatory mechanisms of oncogene-induced senescence in vivo are complex and multifaceted, with DM application potentially playing a subordinate role among distinct molecular factors balancing senescence and proliferation in incompletely resected pLGG [19, 34, 35].

However, this data should not encourage the unquestioned use of DM in these patients, as dose-dependent significant side effects, which include metabolic, gastrointestinal and psychological side effects, as well as possible growth retardation in long-term use in pediatric patients are well describe [17, 18, 36]. In a previously mentioned, recently published retrospective observational study on the utility and prescription standards of DM in pediatric neuro-oncosurgery, the authors conclude in requesting a multicenter prospective study, which may provide evidence-based dosing recommendations considering the age, weight and symptoms of the patient, possibly paving the way to more steroid-sparing regimens. Based on their experience, the authors of the study recommend a standardized dosing of 0.2 mg/kg/day given OD or BD, and recommend limiting treatment of acute presentation to <14 days [30]. We support the request for development of guidelines regarding the use of corticosteroids in pediatric CNS malignancies.

Conclusion

This data emphasizes the safety of short-term perioperative DM application in newly diagnosed pLGG, adding further evidence for decision making. We

recommend future guidelines concerning the use and dosage of DM in pediatric CNS malignancies.

Contributions statement and declarations

Author contributions

David Gorodezki: Material preparation and data collection, data analysis, wrote the first draft of the article. Jens Schittenhelm: Material preparation and data collection. Thomas Nägele: Material preparation and data collection. Martin U. Schuhmann: Material preparation and data collection; supervised the study and edited the article. Martin Ebinger: Material preparation and data collection; supervised the study and edited the article. The work reported in the article has been performed by the authors, unless clearly specified in the text. All authors commented on previous versions of the article. All authors read and approved the final article.

Acknowledgement

Open Access funding enabled and organized by Projekt DEAL.

Conflict of interest

The authors declare no conflicts of interest.

Ethics statement

Our study was performed in line with the principles of the Declaration of Helsinki. Approval was granted by the Ethics Committee of the Medical Faculty and the University Hospital of Tübingen (NO 762/2021B02). Individual consent was waived.

Data availability statement

The datasets analyzed during the current study are available from the corresponding author on reasonable request.

References

- 1) Johnson KJ, Cullen J, Barnholtz-Sloan JS, Ostrom QT, Langer CE, Turner MC, McKean-Cowdin R, Fisher JL, Lupo PJ, Partap S, Schwartzbaum JA, Scheurer ME. Childhood brain tumor epidemiology: a brain tumor epidemiology consortium review. *Cancer Epidemiol Biomarkers Prev*. 2014 Dec;23(12):2716-36.
- 2) Curtin SC, Minino AM, Anderson RN. Declines in Cancer Death Rates Among Children and Adolescents in the United States, 1999-2014. *NCHS Data Brief*. 2016 Sep;(257):1-8. PMID: 27648773.
- 3) Blaney SM, Kun LE, Hunter J, et al. Tumors of the Central Nervous System. In: Pizzo PA, Poplack DG, editors. *Principles and Practice of Pediatric Oncology*. 5th. Philadelphia: Lippincott Williams & Wilkins; 2006. pp. 786–864.
- 4) Broniscer A, Baker SJ, West AN, Fraser MM, Proko E, Kocak M, Dalton J, Zambetti GP, Ellison DW, Kun LE, Gajjar A, Gilbertson RJ, Fuller CE. Clinical and molecular characteristics of malignant transformation of low-grade glioma in children. *J Clin Oncol*. 2007 Feb 20;25(6):682-9.
- 5) Chamdine O, Broniscer A, Wu S, Gajjar A, Qaddoumi I. Metastatic Low-Grade Gliomas in Children: 20 Years' Experience at St. Jude Children's Research Hospital. *Pediatr Blood Cancer*. 2016 Jan;63(1):62-70.
- 6) Liu APY, Hastings C, Wu S, Bass JK, Heitzer AM, Ashford J, Vestal R, Hoehn ME, Ghazwani Y, Acharya S, Conklin HM, Boop F, Merchant TE, Gajjar A, Qaddoumi I. Treatment burden and long-term health deficits of patients with low-grade gliomas or glioneuronal tumors diagnosed during the first year of life. *Cancer*. 2019 Apr 1;125(7):1163-1175.
- 7) van Iersel L, van Santen HM, Potter B, Li Z, Conklin HM, Zhang H, Chemaitilly W, Merchant TE. Clinical impact of hypothalamic-pituitary disorders after conformal radiation therapy for pediatric low-grade glioma or ependymoma. *Pediatr Blood Cancer*. 2020 Dec;67(12).
- 8) Armstrong GT, Liu Q, Yasui Y, Huang S, Ness KK, Leisenring W, Hudson MM, Donaldson SS, King AA, Stovall M, Krull KR, Robison LL, Packer RJ. Long-term outcomes among adult survivors of childhood central nervous system malignancies in the Childhood Cancer Survivor Study. *J Natl Cancer Inst*. 2009 Jul 1;101(13):946-58.
- 9) Sadighi ZS, Curtis E, Zabrowski J, Billups C, Gajjar A, Khan R, Qaddoumi I. Neurologic impairments from pediatric low-grade glioma by tumor location and timing of diagnosis. *Pediatr Blood Cancer*. 2018 Aug;65(8):e27063.

- 10) Sridhar K, Sridhar R, Venkatprasanna G. Management of posterior fossa gliomas in children. *J Pediatr Neurosci*. 2011;6(Suppl 1):S72-S77.
- 11) Sievert AJ, Fisher MJ. Pediatric low-grade gliomas. *J Child Neurol*. 2009;24(11):1397-1408.
- 12) Morrison, Scott R., and Chandrasekaran Kaliaperumal. "Letter to the Editor. Standardization of dexamethasone utility in pediatric neuro-oncosurgery". *Journal of Neurosurgery: Pediatrics* 27.4 (2021): 494-494.
- 13) Glaser AW, Buxton N, Walker D. Corticosteroids in the management of central nervous system tumours. *Archives of Disease in Childhood* 1997;76:76-78.
- 14) Schiff D, Lee EQ, Nayak L, Norden AD, Reardon DA, Wen PY. Medical management of brain tumors and the sequelae of treatment. *Neuro Oncol*. 2015 Apr;17(4):488-504.
- 15) Malbari F, Staggers KA, Minard CG, Weiner HL, Chintagumpala MM, Levy AS. Provider views on perioperative steroid use for patients with newly diagnosed pediatric brain tumors. *J Neurooncol*. 2020 Mar;147(1):205-212.
- 16) Kostaras X, Cusano F, Kline GA, Roa W, Easaw J. Use of dexamethasone in patients with high-grade glioma: a clinical practice guideline. *Curr Oncol*. 2014 Jun;21(3):e493-503.
- 17) Koehler PJ. Use of corticosteroids in neuro-oncology. *Anticancer Drugs*. 1995 Feb;6(1):19-33.
- 18) Stuart FA, Segal TY, Keady S. Adverse psychological effects of corticosteroids in children and adolescents. *Arch Dis Child* 2005;90:500-506.
- 19) Buhl JL, Selt F, Hielscher T, Guiho R, Ecker J, Sahm F, Ridinger J, Riehl D, Usta D, Ismer B, Sommerkamp AC, Martinez-Barbera JP, Wefers AK, Remke M, Picard D, Pusch S, Gronych J, Oehme I, van Tilburg CM, Kool M, Kuhn D, Capper D, von Deimling A, Schuhmann MU, Herold-Mende C, Korshunov A, Brummer T, Pfister SM, Jones DTW, Witt O, Milde T. The Senescence-associated Secretory Phenotype Mediates Oncogene-induced Senescence in Pediatric Pilocytic Astrocytoma. *Clin Cancer Res*. 2019 Mar 15;25(6):1851-1866.
- 20) Medikonda R, Patel K, Jackson C, Saleh L, Srivastava S, Feghali J, Mohan A, Pant A, Jackson CM, Weingart J, Mukherjee D, Bettgowda C, Gallia GL, Brem H, Lim M. The safety and efficacy of dexamethasone in the perioperative management of glioma patients. *J Neurosurg*. 2021 Sep 24;136(4):1062-1069.

- 21) Zhou L, Shen Y, Huang T, et al. The Prognostic Effect of Dexamethasone on Patients With Glioblastoma: A Systematic Review and Meta-Analysis. *Front Pharmacol.* 2021;12:727707. Published 2021 Aug 31.
- 22) Leonard JR, Perry A, Rubin JB, King AA, Chicoine MR, Gutmann DH. The role of surgical biopsy in the diagnosis of glioma in individuals with neurofibromatosis-1. *Neurology.* 2006 Oct 24;67(8):1509-1.
- 23) Harris GJ, Plotkin SR, Maccollin M, Bhat S, Urban T, Lev MH, Slattery WH. Three-dimensional volumetrics for tracking vestibular schwannoma growth in neurofibromatosis type II. *Neurosurgery.* 2008 Jun;62(6):1314-9.
- 24) Kollmann P, Mautner VF, Koeppen J, Wenzel R, Friedman JM, Salamon J, Farschtschi S. MRI based volumetric measurements of vestibular schwannomas in patients with neurofibromatosis type 2: comparison of three different software tools. *Sci Rep.* 2020 Jul 14;10(1):11541.
- 25) Bandopadhyay P, Bergthold G, London WB, Goumnerova LC, Morales La Madrid A, Marcus KJ, Guo D, Ullrich NJ, Robison NJ, Chi SN, Beroukhim R, Kieran MW, Manley PE. Long-term outcome of 4,040 children diagnosed with pediatric low-grade gliomas: an analysis of the Surveillance Epidemiology and End Results (SEER) database. *Pediatr Blood Cancer.* 2014 Jul;61(7):1173-9.
- 26) Stokland T, Liu JF, Ironside JW, Ellison DW, Taylor R, Robinson KJ, Picton SV, Walker DA. A multivariate analysis of factors determining tumor progression in childhood low-grade glioma: a population-based cohort study (CCLG CNS9702). *Neuro Oncol.* 2010 Dec;12(12):1257-68.
- 27) Gnekow AK, Falkenstein F, von Hornstein S, Zwiener I, Berkefeld S, Bison B, Warmuth-Metz M, Driever PH, Soerensen N, Kortmann RD, Pietsch T, Faldum A. Long-term follow-up of the multicenter, multidisciplinary treatment study HIT-LGG-1996 for low-grade glioma in children and adolescents of the German Speaking Society of Pediatric Oncology and Hematology. *Neuro Oncol.* 2012 Oct;14(10):1265-84.
- 28) Horbinski C, Hamilton RL, Lovell C, Burnham J, Pollack IF. Impact of morphology, MIB-1, p53 and MGMT on outcome in pilocytic astrocytomas. *Brain Pathol.* 2010 May;20(3):581-8.
- 29) Horbinski C, Nikiforova MN, Hagenkord JM, Hamilton RL, Pollack IF. Interplay among BRAF, p16, p53, and MIB1 in pediatric low-grade gliomas. *Neuro Oncol.* 2012 Jun;14(6):777-89.
- 30) Chumbala Na Ayudhaya A, Morrison SR, Kaliaperumal C, Gallo P. A 10-year retrospective observational study on the utility and prescription standards of dexamethasone in pediatric neuro-oncosurgery in a tertiary care center. *Childs Nerv Syst.* 2022 Sep;38(9):1707-1715.

- 31) Behrens PF, Ostertag CB, Warnke PC. Regional cerebral blood flow in peritumoral brain edema during dexamethasone treatment: a xenon-enhanced computed tomographic study. *Neurosurgery*. 1998 Aug;43(2):235-40; discussion 240-1.
- 32) Nahaczewski AE, Fowler SB, Hariharan S. Dexamethasone therapy in patients with brain tumors--a focus on tapering. *J Neurosci Nurs*. 2004 Dec;36(6):340-3.
- 33) Koehler PJ. Use of corticosteroids in neuro-oncology. *Anticancer Drugs*. 1995 Feb;6(1):19-33.
- 34) Van Roost, D., Hartmann, A. & Quade, G. Changes of Cerebral Blood Flow Following Dexamethasone Treatment in Brain Tumour Patients. A Xe/CT Study. *Acta Neurochir (Wien)* 143, 37–44 (2001).
- 35) Jacob K, Quang-Khuong DA, Jones DT, Witt H, Lambert S, Albrecht S, Witt O, Vezina C, Shirinian M, Faury D, Garami M, Hauser P, Klekner A, Bogner L, Farmer JP, Montes JL, Atkinson J, Hawkins C, Korshunov A, Collins VP, Pfister SM, Tabori U, Jabado N. Genetic aberrations leading to MAPK pathway activation mediate oncogene-induced senescence in sporadic pilocytic astrocytomas. *Clin Cancer Res*. 2011 Jul 15;17(14):4650-60.
- 36) Raabe EH, Lim KS, Kim JM, Meeker A, Mao XG, Nikkhah G, Maciaczyk J, Kahlert U, Jain D, Bar E, Cohen KJ, Eberhart CG. BRAF activation induces transformation and then senescence in human neural stem cells: a pilocytic astrocytoma model. *Clin Cancer Res*. 2011 Jun 1;17(11):3590-9.
- 37) Chrysis D, Ritzen EM, Sävendahl L. Growth retardation induced by dexamethasone is associated with increased apoptosis of the growth plate chondrocytes. *J Endocrinol*. 2003 Mar;176(3):331-7.

DISCUSSION AND GENERAL OUTLOOK

In the previous chapters, we report a comprehensive analysis of the pre- and postoperative tumor growth velocity of pediatric low-grade glioma, aiming to add to the understanding of the ambivalent growth behavior of these tumors. Therefore, we used a novel approach by quantifying tumor growth rates using sequential MRI based volumetric analyses. Furthermore, the impact of various potential clinical and molecular genetic influencing factors on the growth velocity of these tumors were evaluated [60, 66].

Although a single center approach was applied, we report of a representative cohort, as the distribution of age, histological diagnoses, tumor locations and treatment patterns showed reasonable conformity to previous multicentric population-based studies reporting of larger pediatric low-grade glioma cohorts [60, 66].

To calculate tumor growth rates, semiautomated calculation of sequential segmentation-based volumetric measurements of tumor burden was applied. This method for tracking of tumor growth and treatment response assessment has been forwarded by recent advances in imaging technology and the development of image segmentation software within the last decade, and provides a significant improvement in volumetric assessment of inhomogeneous and irregularly shaped lesions [67]. As previously reported from comparative studies on growth analyses in distinct intracranial malignancies, this method has shown superior sensitivity in the detection of volumetric changes compared to linear measurements [68, 69]. Within our study, repeated tumor volume assessments by various investigators have shown a favorable inter- and intra-observer variability [60, 66].

In chapter one, we illustrate the impact of the scope of surgical therapy on the postoperative tumor growth behavior of these tumors post incomplete resection. As mentioned before, previous population-based cohort studies have repeatedly reported an association between a greater extent of surgical resection and a

favorable progression-free survival [3, 34, 51, 52, 54, 55]. This shows conformity to our data, suggesting a clear correlation between the extent of surgical resection and the postoperative growth velocity of incompletely resected low-grade glioma [60]. Moreover, a cut-off residual tumor volume of $< 2,0 \text{ cm}^3$ associated with a significantly lower risk of progression post incomplete resection within our cohort may provide an approximate idea of a minimal residual tumor volume to strive for in presumably non-completely resectable tumors [60]. Although the conclusiveness of this data might notably be limited by the retrospective approach of this study and is to be verified on a wider scope, it possibly underlines the significance of striving to achieve exhaustive resection of these tumors, if feasible supported by intraoperative neuromonitoring (IONM) for sparing of eloquent areas and image-guided intraoperative resection control [60].

The observation of a sustained growth deceleration caused by extensive subtotal resection may furthermore be underlined as a substantial difference in clinical behavior of pediatric low-grade glioma compared to its counterparts in adult patients, added to the previously described distinct biology and underlying genetic alterations of pediatric and adult LGG [13]. In contrast, a comparable investigation of the tumor growth velocity of adult LGG has shown no significant changes in tumor growth behavior after incomplete resection [70].

The cellular and molecular background of potential postoperative senescence in incompletely resected pediatric low-grade glioma cannot be derived from this data and requires further molecular studies of the cellular mechanisms of senescence in MAPK-driven pediatric LGG.

In chapter one, we furthermore provide a subsequent analysis studying the impact of the most common molecular MAPK alterations on the pre- and postoperative growth velocity of incompletely resected pediatric low-grade glioma. As previously mentioned, molecular testing for these alterations has not only contributed to a more profound understanding of these tumors, but furthermore found its way into diagnostic routine, providing an essential tool for risk stratification and for guiding promising personalized molecular therapies [14 - 17]. Notably, the prognostic value of the distinct MAPK alterations is still under

debate and not yet conclusively assessed [71 - 75]. Within our cohort, comparison of tumor growth velocity of BRAF V600E positive pediatric LGG and BRAF wild-type LGG showed significantly higher tumor growth rates of BRAF V600E mutated LGG post incomplete resection [60]. This observation is consistent with previous reports, suggesting BRAF V600E mutated glioma, particularly in combination with a CDKN2A deletion, as a high-risk subgroup of pediatric LGG [71, 75]. The conclusiveness of this data is however limited due to low case numbers, as a significant number of patients within the reported cohort has been diagnosed before molecular testing for the most common MAPK alterations has routinely been performed [60].

In chapter two, we report the first data on the impact of perioperative dexamethasone application on postoperative tumor growth rates and progression-free survival in a large pediatric low-grade glioma cohort.

Ever since the benefits of corticosteroids in the management of acute symptoms related to CNS tumors have been described around 65 years ago, those agents are prevalently applied in patients with newly diagnosed brain tumors and signs of raised intracranial pressure or tumor related cerebral edema [39, 40, 61, 62]. Over the past years, however, several studies and meta-analyses raised concerns about the safety of dexamethasone use in adult glioma patients, possibly linking a dexamethasone treatment with an unfavorable progression-free survival [64, 65]. Up to today, no significant data regarding the safety of its use in pediatric brain tumor patients has been published. Studying postoperative tumor growth behavior and progression-free survival of patients perioperatively treated with dexamethasone compared to a control group within our cohort, we illustrate the absence of a significant difference in tumor growth velocity and treatment outcome between both groups [66].

Based on previous in vitro observations of a possible senescence inhibition of dexamethasone in a preclinical pediatric low-grade glioma model, we furthermore analyzed the clinical implications of dexamethasone treatment after subdividing our cohort in patients with tumors bearing various fractions of senescent cells,

based on the MIB-1/KI-67 proliferation index [63, 66]. A clinical implication of possible senescence inhibition could not be observed within our cohort [66].

While this data emphasizes the safety of short-term perioperative dexamethasone use in patients with pediatric low-grade glioma, it should be pointed out, that this data notably does not make any conclusion about its less common long-term use in these patients [66]. However, treatment periods observed in our study concur with commonly applied dosing and treatment regimens observed in a large observational study regarding the prescription standards of corticosteroids in pediatric brain tumor patients [61].

Taken together, the data presented in this work may add to the understanding of the ambivalent postoperative growth behavior of pediatric low-grade glioma, which commonly issue a challenge to oncologists attending these patients following incomplete resection. While this data supports previous data suggesting low resection extent and BRAF V600E mutation as a possible risk factor for progression following incomplete resection, it illustrates the tendency towards a state of senescence in minor tumor residues, and furthermore forecloses a possible clinical implication of a possible dexamethasone-induced senescence inhibition [60, 66].

REFERENCES

- 1) Linabery AM, Ross JA. Trends in childhood cancer incidence in the U.S. (1992-2004). *Cancer*. 2008 Jan 15;112(2):416-32. doi: 10.1002/cncr.23169.
- 2) Ostrom QT, Cioffi G, Waite K, Kruchko C, Barnholtz-Sloan JS. CBTRUS Statistical Report: Primary Brain and Other Central Nervous System Tumors Diagnosed in the United States in 2014-2018. *Neuro Oncol*. 2021 Oct 5;23(12 Suppl 2):iii1-iii105. doi: 10.1093/neuonc/noab200.
- 3) Sievert AJ, Fisher MJ. Pediatric low-grade gliomas. *J Child Neurol*. 2009 Nov;24(11):1397-408. doi: 10.1177/0883073809342005.
- 4) Rickert CH, Paulus W. Epidemiology of central nervous system tumors in childhood and adolescence based on the new WHO classification. *Childs Nerv Syst*. 2001 Sep;17(9):503-11. doi: 10.1007/s003810100496.
- 5) Blaney SM, Kun LE, Hunter J, et al. Tumors of the Central Nervous System. In: Pizzo PA, Poplack DG, editors. *Principles and Practice of Pediatric Oncology*. 5th. Philadelphia: Lippincott Williams & Wilkins; 2006. pp. 786–864.
- 6) Kaatsch P, Rickert CH, Kühl J, Schüz J, Michaelis J. Population-based epidemiologic data on brain tumors in German children. *Cancer*. 2001 Dec 15;92(12):3155-64. doi: 10.1002/1097-0142(20011215)92:12<3155::aid-cncr10158>3.0.co;2-c.
- 7) WHO Classification of Tumours Editorial Board. *World Health Organization Classification of Tumours of the Central Nervous System*. 5th ed. Lyon: International Agency for Research on Cancer; 2021.
- 8) Louis DN, Perry A, Wesseling P, Brat DJ, Cree IA, Figarella-Branger D, Hawkins C, Ng HK, Pfister SM, Reifenberger G, Soffiotti R, von Deimling A, Ellison DW. The 2021 WHO Classification of Tumors of the Central Nervous System: a summary. *Neuro Oncol*. 2021 Aug 2;23(8):1231-1251. doi: 10.1093/neuonc/noab106.
- 9) Freeman CR, Farmer JP, Montes J. Low-grade astrocytomas in children: evolving management strategies. *Int J Radiat Oncol Biol Phys*. 1998 Jul 15;41(5):979-87. doi: 10.1016/s0360-3016(98)00163-1.
- 10) Hayostek CJ, Shaw EG, Scheithauer B, O'Fallon JR, Weiland TL, Schomberg PJ, Kelly PJ, Hu TC. Astrocytomas of the cerebellum. A comparative clinicopathologic study of pilocytic and diffuse astrocytomas. *Cancer*. 1993 Aug 1;72(3):856-69. doi: 10.1002/1097-0142(19930801)72:3<856::aid-cncr2820720335>3.0.co;2-k.

- 11) Hoffman HJ, Humphreys RP, Drake JM, Rutka JT, Becker LE, Jenkin D, Greenberg M. Optic pathway/hypothalamic gliomas: a dilemma in management. *Pediatr Neurosurg*. 1993 Jul-Aug;19(4):186-95. doi: 10.1159/000120729.
- 12) Johnson JH Jr, Hariharan S, Berman J, Sutton LN, Rorke LB, Molloy P, Phillips PC. Clinical outcome of pediatric gangliogliomas: ninety-nine cases over 20 years. *Pediatr Neurosurg*. 1997 Oct;27(4):203-7. doi: 10.1159/000121252.
- 13) Greuter L, Guzman R, Soleman J. Pediatric and Adult Low-Grade Gliomas: Where Do the Differences Lie? *Children (Basel)*. 2021 Nov 22;8(11):1075. doi: 10.3390/children8111075.
- 14) Collins VP, Jones DT, Giannini C. Pilocytic astrocytoma: pathology, molecular mechanisms and markers. *Acta Neuropathol*. 2015 Jun;129(6):775-88. doi: 10.1007/s00401-015-1410-7.
- 15) Jones DT, Gronych J, Lichter P, Witt O, Pfister SM. MAPK pathway activation in pilocytic astrocytoma. *Cell Mol Life Sci*. 2012 Jun;69(11):1799-811. doi: 10.1007/s00018-011-0898-9.
- 16) Northcott PA, Pfister SM, Jones DT. Next-generation (epi)genetic drivers of childhood brain tumours and the outlook for targeted therapies. *Lancet Oncol*. 2015 Jun;16(6):e293-302. doi: 10.1016/S1470-2045(14)71206-9.
- 17) Ryall S, Tabori U, Hawkins C. Pediatric low-grade glioma in the era of molecular diagnostics. *Acta Neuropathol Commun*. 2020 Mar 12;8(1):30. doi: 10.1186/s40478-020-00902-z.
- 18) Shofty B, Ben Sira L, Constantini S. Neurofibromatosis 1-associated optic pathway gliomas. *Childs Nerv Syst*. 2020 Oct;36(10):2351-2361. doi: 10.1007/s00381-020-04697-1.
- 19) Campen CJ, Gutmann DH. Optic Pathway Gliomas in Neurofibromatosis Type 1. *J Child Neurol*. 2018 Jan;33(1):73-81. doi: 10.1177/0883073817739509.
- 20) Evans DGR, Salvador H, Chang VY, Erez A, Voss SD, Schneider KW, Scott HS, Plon SE, Tabori U. Cancer and Central Nervous System Tumor Surveillance in Pediatric Neurofibromatosis 1. *Clin Cancer Res*. 2017 Jun 15;23(12):e46-e53. doi: 10.1158/1078-0432.CCR-17-0589.
- 21) Fried I, Tabori U, Tihan T, Reginald A, Bouffet E. Optic pathway gliomas: a review. *CNS Oncol*. 2013 Mar;2(2):143-59. doi: 10.2217/cns.12.47.

- 22)Adriaensen ME, Schaefer-Prokop CM, Stijnen T, Duyndam DA, Zonnenberg BA, Prokop M. Prevalence of subependymal giant cell tumors in patients with tuberous sclerosis and a review of the literature. *Eur J Neurol*. 2009 Jun;16(6):691-6. doi: 10.1111/j.1468-1331.2009.02567.x.
- 23)Sridhar K, Sridhar R, Venkatprasanna G. Management of posterior fossa gliomas in children. *J Pediatr Neurosci*. 2011 Oct;6(Suppl 1):S72-7. doi: 10.4103/1817-1745.85714.
- 24)Suharwardy, J., Elston, J. The clinical presentation of children with tumours affecting the anterior visual pathways. *Eye* **11**, 838–844 (1997). doi: 10.1038/eye.1997.215
- 25)Fisher, P.G., Tihan, T., Goldthwaite, P.T., Wharam, M.D., Carson, B.S., Weingart, J.D., Repka, M.X., Cohen, K.J. and Burger, P.C. (2008), Outcome analysis of childhood low-grade astrocytomas. *Pediatr. Blood Cancer*, 51: 245-250. Doi: 10.1002/pbc.21563
- 26)Jaju A, Yeom KW, Ryan ME. MR Imaging of Pediatric Brain Tumors. *Diagnostics (Basel)*. 2022 Apr 12;12(4):961. doi: 10.3390/diagnostics12040961.
- 27)Brandão LA, Young Poussaint T. Posterior Fossa Tumors. *Neuroimaging Clin N Am*. 2017 Feb;27(1):1-37. doi: 10.1016/j.nic.2016.08.001. PMID: 27889018.
- 28)AlRayahi J, Zapotocky M, Ramaswamy V, Hanagandi P, Branson H, Mubarak W, Raybaud C, Laughlin S. Pediatric Brain Tumor Genetics: What Radiologists Need to Know. *Radiographics*. 2018 Nov-Dec;38(7):2102-2122. doi: 10.1148/rg.2018180109.
- 29)Lescher S, Schniewindt S, Jurcoane A, Senft C, Hattingen E. Time window for postoperative reactive enhancement after resection of brain tumors: less than 72 hours. *Neurosurg Focus*. 2014 Dec;37(6):E3. doi: 10.3171/2014.9.FOCUS14479.
- 30)Chamdine O, Broniscer A, Wu S, Gajjar A, Qaddoumi I. Metastatic Low-Grade Gliomas in Children: 20 Years' Experience at St. Jude Children's Research Hospital. *Pediatr Blood Cancer*. 2016 Jan;63(1):62-70. doi: 10.1002/pbc.25731.
- 31)Leonard JR, Perry A, Rubin JB, King AA, Chicoine MR, Gutmann DH. The role of surgical biopsy in the diagnosis of glioma in individuals with neurofibromatosis-1. *Neurology*. 2006 Oct 24;67(8):1509-12. doi: 10.1212/01.wnl.0000240076.31298.47.
- 32)Jones DTW, Kieran MW, Bouffet E, Alexandrescu S, Bandopadhyay P, Bornhorst M, Ellison D, Fangusaro J, Fisher MJ, Foreman N, Fouladi M,

- Hargrave D, Hawkins C, Jabado N, Massimino M, Mueller S, Perilongo G, Schouten van Meeteren AYN, Tabori U, Warren K, Waanders AJ, Walker D, Weiss W, Witt O, Wright K, Zhu Y, Bowers DC, Pfister SM, Packer RJ. Pediatric low-grade gliomas: next biologically driven steps. *Neuro Oncol.* 2018 Jan 22;20(2):160-173. doi: 10.1093/neuonc/nox141.
- 33) Collins KL, Pollack IF. Pediatric Low-Grade Gliomas. *Cancers (Basel).* 2020 May 4;12(5):1152. doi: 10.3390/cancers12051152.
- 34) Wisoff JH, Sanford RA, Heier LA, et al. Primary neurosurgery for pediatric low-grade gliomas: a prospective multi-institutional study from the Children's Oncology Group. *Neurosurgery.* 2011 Jun;68(6):1548-54; discussion 1554-5. DOI: 10.1227/neu.0b013e318214a66e.
- 35) Karajannis, M., Allen, J.C. and Newcomb, E.W. (2008), Treatment of pediatric brain tumors. *J. Cell. Physiol.*, 217: 584-589. doi: 10.102/jcp.21544
- 36) Berger M.S., Kincaid J., Ojemann G.A., Lettich E. Brain mapping techniques to maximize resection, safety, and seizure control in children with brain tumors. *Neurosurgery.* 1989;25:786–792. doi: 10.1227/00006123-198911000-00015.
- 37) Roder C, Breikopf M, Ms, Bisdas S, Freitas Rda S, Dimostheni A, Ebinger M, Wolff M, Tatagiba M, Schuhmann MU. Beneficial impact of high-field intraoperative magnetic resonance imaging on the efficacy of pediatric low-grade glioma surgery. *Neurosurg Focus.* 2016 Mar;40(3):E13. doi: 10.3171/2015.11.FOCUS15530.
- 38) Carai A, De Benedictis A, Calloni T, Onorini N, Paternò G, Randi F, Colafati GS, Mastronuzzi A, Marras CE. Intraoperative Ultrasound-Assisted Extent of Resection Assessment in Pediatric Neurosurgical Oncology. *Front Oncol.* 2021 Apr 21;11:660805. doi: 10.3389/fonc.2021.660805.
- 39) Glaser AW, Buxton N, Walker D. Corticosteroids in the management of central nervous system tumours. *Archives of Disease in Childhood* 1997;76:76-78. doi: 10.1136/adc.76.1.76
- 40) Morrison SR, Kaliaperumal C. Letter to the Editor. Standardization of dexamethasone utility in pediatric neuro-oncosurgery. *J Neurosurg Pediatr.* 2021 Feb 5;27(4):494. doi: 10.3171/2020.11.PEDS20842.
- 41) Saunders DE, Phipps KP, Wade AM, Hayward RD. Surveillance imaging strategies following surgery and/or radiotherapy for childhood cerebellar low-grade astrocytoma. *J Neurosurg.* 2005 Mar;102(2 Suppl):172-8. doi: 10.3171/jns.2005.102.2.0172.

- 42) Benesch M, Eder HG, Sovinz P, Raith J, Lackner H, Moser A, Urban C. Residual or recurrent cerebellar low-grade glioma in children after tumor resection: is re-treatment needed? A single center experience from 1983 to 2003. *Pediatr Neurosurg.* 2006;42(3):159-64. doi: 10.1159/000091859.
- 43) Palma L, Celli P, Mariottini A. Long-term follow-up of childhood cerebellar astrocytomas after incomplete resection with particular reference to arrested growth or spontaneous tumour regression. *Acta Neurochir (Wien).* 2004 Jun;146(6):581-8; discussion 588. doi: 10.1007/s00701-004-0257-9.
- 44) de Blank P, Bandopadhyay P, Haas-Kogan D, Fouladi M, Fangusaro J. Management of pediatric low-grade glioma. *Curr Opin Pediatr.* 2019 Feb;31(1):21-27. doi: 10.1097/MOP.0000000000000717.
- 45) Merchant TE, Conklin HM, Wu S, Lustig RH, Xiong X. Late effects of conformal radiation therapy for pediatric patients with low-grade glioma: prospective evaluation of cognitive, endocrine, and hearing deficits. *J Clin Oncol.* 2009 Aug 1;27(22):3691-7. doi: 10.1200/JCO.2008.21.2738.
- 46) Pierce SM, Barnes PD, Loeffler JS, McGinn C, Tarbell NJ. Definitive radiation therapy in the management of symptomatic patients with optic glioma. Survival and long-term effects. *Cancer.* 1990 Jan 1;65(1):45-52. doi: 10.1002/1097-0142(19900101)65:1<45::aid-cncr2820650111>3.0.co;2-z.
- 47) Greenberger BA, Pulsifer MB, Ebb DH, MacDonald SM, Jones RM, Butler WE, Huang MS, Marcus KJ, Oberg JA, Tarbell NJ, Yock TI. Clinical outcomes and late endocrine, neurocognitive, and visual profiles of proton radiation for pediatric low-grade gliomas. *Int J Radiat Oncol Biol Phys.* 2014 Aug 1;89(5):1060-1068. doi: 10.1016/j.ijrobp.2014.04.053.
- 48) Marcus KJ, Goumnerova L, Billett AL, Lavally B, Scott RM, Bishop K, Xu R, Young Poussaint T, Kieran M, Kooy H, Pomeroy SL, Tarbell NJ. Stereotactic radiotherapy for localized low-grade gliomas in children: final results of a prospective trial. *Int J Radiat Oncol Biol Phys.* 2005 Feb 1;61(2):374-9. doi: 10.1016/j.ijrobp.2004.06.012.
- 49) Ater JL, Zhou T, Holmes E, Mazewski CM, Booth TN, Freyer DR, Lazarus KH, Packer RJ, Prados M, Sposto R, Vezina G, Wisoff JH, Pollack IF. Randomized study of two chemotherapy regimens for treatment of low-grade glioma in young children: a report from the Children's Oncology Group. *J Clin Oncol.* 2012 Jul 20;30(21):2641-7. doi: 10.1200/JCO.2011.36.6054.
- 50) Avinash KS, Thakar S, Aryan S, Ghosal N, Hegde AS. Malignant Transformation of Pediatric Low-grade Gliomas: Report of Two Cases and Review of a Rare Pathological Phenomenon. *Neurol India.* 2019 Jul-Aug;67(4):1100-1106. doi: 10.4103/0028-3886.266259.

- 51) Stokland T, Liu JF, Ironside JW, Ellison DW, Taylor R, Robinson KJ, Picton SV, Walker DA. A multivariate analysis of factors determining tumor progression in childhood low-grade glioma: a population-based cohort study (CCLG CNS9702). *Neuro Oncol.* 2010 Dec;12(12):1257-68. doi: 10.1093/neuonc/noq092.
- 52) Gnekow AK, Falkenstein F, von Hornstein S, Zwiener I, Berkefeld S, Bison B, Warmuth-Metz M, Driever PH, Soerensen N, Kortmann RD, Pietsch T, Faldum A. Long-term follow-up of the multicenter, multidisciplinary treatment study HIT-LGG-1996 for low-grade glioma in children and adolescents of the German Speaking Society of Pediatric Oncology and Hematology. *Neuro Oncol.* 2012 Oct;14(10):1265-84. doi: 10.1093/neuonc/nos202.
- 53) Krishnatry R, Zhukova N, Guerreiro Stucklin AS, Pole JD, Mistry M, Fried I, Ramaswamy V, Bartels U, Huang A, Laperriere N, Dirks P, Nathan PC, Greenberg M, Malkin D, Hawkins C, Bandopadhyay P, Kieran MW, Manley PE, Bouffet E, Tabori U. Clinical and treatment factors determining long-term outcomes for adult survivors of childhood low-grade glioma: A population-based study. *Cancer.* 2016 Apr 15;122(8):1261-9. doi: 10.1002/cncr.29907.
- 54) Fisher BJ, Leighton CC, Vujovic O, Macdonald DR, Stitt L. Results of a policy of surveillance alone after surgical management of pediatric low grade gliomas. *Int J Radiat Oncol Biol Phys.* 2001 Nov 1;51(3):704-10. doi: 10.1016/s0360-3016(01)01705-9.
- 55) Shaw EG, Wisoff JH. Prospective clinical trials of intracranial low-grade glioma in adults and children. *Neuro Oncol.* 2003 Jul;5(3):153-60. doi: 10.1215/S1152851702000601.
- 56) Rozen WM, Joseph S, Lo PA. Spontaneous regression of low-grade gliomas in pediatric patients without neurofibromatosis. *Pediatr Neurosurg.* 2008;44(4):324-8. doi: 10.1159/000134925.
- 57) Parsa CF, Hoyt CS, Lesser RL, Weinstein JM, Strother CM, Muci-Mendoza R, Ramella M, Manor RS, Fletcher WA, Repka MX, Garrity JA, Ebner RN, Monteiro ML, McFadzean RM, Rubtsova IV, Hoyt WF. Spontaneous regression of optic gliomas: thirteen cases documented by serial neuroimaging. *Arch Ophthalmol.* 2001 Apr;119(4):516-29. doi: 10.1001/archophth.119.4.516.
- 58) Liu APY, Hastings C, Wu S, Bass JK, Heitzer AM, Ashford J, Vestal R, Hoehn ME, Ghazwani Y, Acharya S, Conklin HM, Boop F, Merchant TE, Gajjar A, Qaddoumi I. Treatment burden and long-term health deficits of patients with low-grade gliomas or glioneuronal tumors diagnosed during

- the first year of life. *Cancer*. 2019 Apr 1;125(7):1163-1175. doi: 10.1002/cncr.31918.
- 59) Sadighi ZS, Curtis E, Zabrowski J, Billups C, Gajjar A, Khan R, Qaddoumi I. Neurologic impairments from pediatric low-grade glioma by tumor location and timing of diagnosis. *Pediatr Blood Cancer*. 2018 Aug;65(8):e27063. doi: 10.1002/pbc.27063.
- 60) Gorodezki D, Zipfel J, Queudeville M, Sosa J, Holzer U, Kern J, Bevot A, Schittenhelm J, Nägele T, Ebinger M, Schuhmann MU. Resection extent and BRAF V600E mutation status determine postoperative tumor growth velocity in pediatric low-grade glioma: results from a single-center cohort analysis. *J Neurooncol*. 2022 Dec;160(3):567-576. doi: 10.1007/s11060-022-04176-4.
- 61) Chumbala Na Ayudhaya A, Morrison SR, Kaliaperumal C, Gallo P. A 10-year retrospective observational study on the utility and prescription standards of dexamethasone in pediatric neuro-oncosurgery in a tertiary care center. *Childs Nerv Syst*. 2022 Sep;38(9):1707-1715. doi: 10.1007/s00381-022-05569-6.
- 62) Schiff D, Lee EQ, Nayak L, Norden AD, Reardon DA, Wen PY. Medical management of brain tumors and the sequelae of treatment. *Neuro Oncol*. 2015 Apr;17(4):488-504. doi: 10.1093/neuonc/nou304.
- 63) Buhl JL, Selt F, Hielscher T, Guiho R, Ecker J, Sahm F, Ridinger J, Riehl D, Usta D, Ismer B, Sommerkamp AC, Martinez-Barbera JP, Wefers AK, Remke M, Picard D, Pusch S, Gronych J, Oehme I, van Tilburg CM, Kool M, Kuhn D, Capper D, von Deimling A, Schuhmann MU, Herold-Mende C, Korshunov A, Brummer T, Pfister SM, Jones DTW, Witt O, Milde T. The Senescence-associated Secretory Phenotype Mediates Oncogene-induced Senescence in Pediatric Pilocytic Astrocytoma. *Clin Cancer Res*. 2019 Mar 15;25(6):1851-1866. doi: 10.1158/1078-0432.CCR-18-1965.
- 64) Medikonda R, Patel K, Jackson C, Saleh L, Srivastava S, Feghali J, Mohan A, Pant A, Jackson CM, Weingart J, Mukherjee D, Bettgowda C, Gallia GL, Brem H, Lim M. The safety and efficacy of dexamethasone in the perioperative management of glioma patients. *J Neurosurg*. 2021 Sep 24;136(4):1062-1069. doi: 10.3171/2021.4.JNS204127.
- 65) Zhou L, Shen Y, Huang T, Sun Y, Alolga RN, Zhang G, Ge Y. The Prognostic Effect of Dexamethasone on Patients With Glioblastoma: A Systematic Review and Meta-Analysis. *Front Pharmacol*. 2021 Aug 31;12:727707. doi: 10.3389/fphar.2021.727707.
- 66) Gorodezki D, Zipfel J, Queudeville M, Holzer U, Bevot A, Schittenhelm J, Nägele T, Schuhmann MU, Ebinger M. Evaluating the safety of perioperative dexamethasone treatment: A retrospective analysis of a

- single center pediatric low-grade glioma cohort. *Int J Cancer*. 2023 May 1;152(9):1875-1883. doi: 10.1002/ijc.34399.
- 67) Cai WL, Hong GB. Quantitative image analysis for evaluation of tumor response in clinical oncology. *Chronic Dis Transl Med*. 2018 Mar 8;4(1):18-28. doi: 10.1016/j.cdtm.2018.01.002.
- 68) Selleck AM, Rodriguez JD, Brown KD. Vestibular Schwannoma Measurements-Is Volumetric Analysis Clinically Necessary? *Otol Neurotol*. 2021 Jul 1;42(6):906-911. doi: 10.1097/MAO.0000000000003055.
- 69) Harris GJ, Plotkin SR, Maccollin M, Bhat S, Urban T, Lev MH, Slattery WH. Three-dimensional volumetrics for tracking vestibular schwannoma growth in neurofibromatosis type II. *Neurosurgery*. 2008 Jun;62(6):1314-9; discussion 1319-20. doi: 10.1227/01.neu.0000333303.79931.83.
- 70) Mandonnet E, Pallud J, Fontaine D, et al: Inter- and inpatient comparison of WHO grade II glioma kinetics before and after surgical resection. *Neurosurg Rev*. 2010 Jan;33(1):91-6. doi: 10.1007/s10143-009-0229-x.
- 71) Lassaletta A, Zapotocky M, Mistry M, et al: Therapeutic and prognostic implications of BRAF V600E in pediatric low-grade gliomas. *J Clin Oncol* 35: 2934-2941, 2017. doi: 10.1200/JCO.2016.71.8726.
- 72) Mistry M, Zhukova N, Merico D, Rakopoulos P, Krishnatry R, Shago M, Stavropoulos J, Alon N, Pole JD, Ray PN, Navickiene V, Mangerel J, Remke M, Buczkowicz P, Ramaswamy V, Guerreiro Stucklin A, Li M, Young EJ, Zhang C, Castelo-Branco P, Bakry D, Laughlin S, Shlien A, Chan J, Ligon KL, Rutka JT, Dirks PB, Taylor MD, Greenberg M, Malkin D, Huang A, Bouffet E, Hawkins CE, Tabori U. BRAF mutation and CDKN2A deletion define a clinically distinct subgroup of childhood secondary high-grade glioma. *J Clin Oncol*. 2015 Mar 20;33(9):1015-22. doi: 10.1200/JCO.2014.58.3922.
- 73) Hawkins C, Walker E, Mohamed N, Zhang C, Jacob K, Shirinian M, Alon N, Kahn D, Fried I, Scheinemann K, Tsangaris E, Dirks P, Tressler R, Bouffet E, Jabado N, Tabori U. BRAF-KIAA1549 fusion predicts better clinical outcome in pediatric low-grade astrocytoma. *Clin Cancer Res*. 2011 Jul 15;17(14):4790-8. doi: 10.1158/1078-0432.CCR-11-0034
- 74) Horbinski C, Hamilton RL, Nikiforov Y, Pollack IF. Association of molecular alterations, including BRAF, with biology and outcome in pilocytic astrocytomas. *Acta Neuropathol*. 2010 May;119(5):641-9. doi: 10.1007/s00401-009-0634-9.

75) David T.W. Jones, Olaf Witt, and Stefan M. Pfister: *BRAF V600E* Status Alone Is Not Sufficient as a Prognostic Biomarker in Pediatric Low-Grade Glioma. *Journal of Clinical Oncology* 2018 36:1, 96-96. doi: 10.1200/JCO.2017.75.8987.

SUMMARY / ZUSAMMENFASSUNG

Summary

Pediatric low-grade gliomas comprise a heterogeneous set of central nervous system WHO grade I or II tumors that represent the most prevalent types of brain neoplasms of childhood and adolescence. Despite favorable long-term overall survival rates, the clinical course of pediatric low-grade gliomas following incomplete resection shows vast variability. While senescence or spontaneous regression are observed, patients experiencing multiple progressions and unsatisfactory tumor control often suffer from neurological and endocrine disorders, caused by tumor burden or treatment sequelae, and are prone to bear significant long-term morbidity. The ambivalent growth behavior of these tumors is barely understood and commonly issues a challenge to oncologists attending these patients following incomplete resection.

The present work comprises a comprehensive retrospective analysis of pre- and postoperative tumor growth velocity of a large monoinstitutional pediatric low-grade glioma cohort. Growth rates of incompletely resected gliomas were quantified for the first time applying sequential MRI-based three-dimensional tumor volumetry. Further analyses showed a clear correlation between the extent of surgical resection and postoperative growth velocity, while a calculated cut-off residual tumor volume associated with a significantly lower risk of progression may provide an idea of a minimal residual tumor volume to strive for in presumably non-completely resectable tumors. BRAF V600E mutated tumors showed significantly higher tumor growth rates compared to BRAF V600E wild-type glioma. A possible dexamethasone-induced senescence inhibition, which was previously reported from in vitro analyses of oncogene-induced senescence in pediatric low-grade glioma, showed no clinical implication, as dexamethasone treatment showed no impact on tumor growth rates and progression-free survival.

The data presented in this work may add to the understanding of the multifaceted growth velocity of pediatric low-grade glioma. While this data supports previous

observations suggesting low resection extent and BRAF V600E mutation as a possible risk factor for progression following incomplete resection, it illustrates the tendency towards a state of senescence in minor tumor residues, and emphasizes the safety of perioperative dexamethasone treatment in pediatric low-grade glioma patients.

Zusammenfassung

Niedriggradig maligne Gliome umfassen eine heterogene Gruppe von ZNS-Tumoren astrozytären, glialen und glioneuralen Ursprungs, die gemäß der WHO-Klassifikation als Grad I und II-Tumoren eingestuft werden und die häufigste Tumorentität des zentralen Nervensystems im Kindes- und Jugendalter darstellen.

Trotz günstiger Langzeitüberlebensraten ist der Krankheitsverlauf nicht vollständig resezierbarer pädiatrischer Low-grade Gliome häufig von einem sehr heterogenen Wachstumsverhalten residueller Tumoreherde geprägt. Während nicht selten ein stabiler Krankheitsverlauf beobachtet wird, leiden Patienten bei Progress nicht vollständig resezierbarer Low-grade Gliome häufig an neurologischen oder endokrinologischen Langzeitfolgen, welche durch wiederkehrenden Tumorprogress und Therapietoxizität begünstigt werden. Das heterogene Wachstumsverhalten dieser Tumore und die eingeschränkte Prognostizierbarkeit des Krankheitsverlaufes stellt das interdisziplinäre Behandlungsteam häufig vor Herausforderungen hinsichtlich therapeutischer Entscheidungen.

Die vorliegende Arbeit beschreibt eine retrospektive Analyse des ambivalenten Wachstumsverhaltens pädiatrischer Low-grade Gliome einer großen monozentrischen Kohorte. Mittels sequenzieller MR-basierter dreidimensionaler Tumolvolumetrie wurde die prä- und postoperative Wachstumsgeschwindigkeit pädiatrischer Low-grade Gliome erstmals quantifiziert. In einer nachfolgenden

Analyse konnte ein signifikanter Einfluss des Resektionsausmaßes auf das langfristige Wachstumsverhalten unvollständig resezierter Gliome gezeigt werden, während hinsichtlich residueller Tumervolumina ein Grenzwert kalkuliert werden konnte, bis zu diesem mit ausreichender Sensitivität und Spezifität eine Tumorstabilität nach unvollständiger Resektion vorausgesagt werden konnte. Gliome mit Nachweis einer BRAF V600E-Mutation zeigten ein signifikant höhere Wachstumsgeschwindigkeit nach unvollständiger Resektion. Ein messbarer Einfluss einer möglichen Dexamethason-induzierten Seneszenzinhibition auf das Tumorwachstum, welcher in zuvor veröffentlichten in-vitro Analysen onkogen-induzierter Seneszenz pädiatrischer Low-grade Gliome beschrieben wurde, konnte nicht gezeigt werden.

Zusammenfassend kann die vorliegende Arbeit zum Verständnis des facettenreichen Wachstumsverhaltens pädiatrischer Low-grade Gliome beitragen. Sie unterstreicht das geringe Resektionsausmaß und den Nachweis einer BRAF V600E-Mutation als mögliche Risikofaktoren für einen Tumorprogress nach unvollständiger Resektion, während die Tendenz zu postoperativer Seneszenz geringer Tumorresiduen und die Sicherheit einer perioperativen Dexamethason-Therapie gezeigt werden kann.

CONTRIBUTION STATEMENT

Erklärung zum Eigenanteil der Dissertationsschrift

Die Arbeit wurde in der Klinik für pädiatrische Hämatologie und Onkologie der Universitäts-Kinderklinik Tübingen unter Betreuung von Prof. Dr. Martin Ebinger durchgeführt.

Es handelt sich um eine kumulative Dissertation unter Zusammenführung zweier Publikationen, die in international anerkannten Fachzeitschriften auf dem Gebiet der Onkologie nach ausführlicher Prüfung durch externe fachkundige Gutachter in einem ‚Peer review‘-Verfahren veröffentlicht wurden.

Ausführliche Erklärungen zum Eigenanteil, sowie zu den Beiträgen der Co-Autoren zu den entsprechenden Arbeiten finden sich in den entsprechenden Kapiteln. Die statistische Auswertung, sowie das Verfassen der Manuskripte erfolgte vollumfänglich durch mich unter Beratung von Prof. Dr. Martin Ebinger und Prof. Dr. Martin Schuhmann. Die übrigen Teile dieser Dissertation wurden ebenfalls ausschließlich von mir verfasst. Ich versichere, keine weiteren als die von mir angegebenen Quellen verwendet zu haben.

David Gorodezki

Tübingen, den 28.02.2023

PUBLICATIONS

Gorodezki D, Zipfel J, Queudeville M, Sosa J, Holzer U, Kern J, Bevot A, Schittenhelm J, Nägele T, Ebinger M, Schuhmann MU. Resection extent and BRAF V600E mutation status determine postoperative tumor growth velocity in pediatric low-grade glioma: results from a single-center cohort analysis. *J Neurooncol.* 2022 Dec;160(3):567-576. doi: 10.1007/s11060-022-04176-4.

Gorodezki D, Zipfel J, Queudeville M, Holzer U, Bevot A, Schittenhelm J, Nägele T, Schuhmann MU, Ebinger M. Evaluating the safety of perioperative dexamethasone treatment: A retrospective analysis of a single center pediatric low-grade glioma cohort. *Int J Cancer.* 2022 Dec 15. doi: 10.1002/ijc.34399.

ACKNOWLEDGMENTS

Danksagung

Mein größter Dank gilt meinem Betreuer Prof. Dr. Martin Ebinger für die hingabevolle Unterstützung bei der Erstellung dieser Arbeit. Lieber Martin, Du wirst mir mit deiner offenherzigen, unterstützenden und positiven Art sowohl im beruflichen Kontext, als auch privat immer ein großes Vorbild sein. Hab vielen Dank dafür.

Auch Prof. Dr. Martin Schuhmann gilt mein besonderer Dank für die Überlassung dieses interessanten Themas. Lieber Martin, mit deiner Art, wie Du dich Tag für Tag mit einer unerschöpflichen Leidenschaft für das Wohl der großen und kleinen Dir anvertrauten Patienten sorgst, wirst Du immer eine große Inspiration für mich sein.

Meiner wundervollen Familie möchte ich für die bedingungslose und liebevolle Begleitung auf diesem langen Weg danken. Ihr seid für mich unersetzlich.

Ganz besonders möchte ich zuletzt meiner Freundin Ann-Sophie für die unendliche Geduld, Liebe und die vielen kleinen Erheiterungen auf unserem gemeinsamen Weg danken. Ohne dich wäre das Leben nur halb so schön.